

# Renal Tubular Acidosis Presenting As Severe Hypokalemia With Respiratory Paralysis: Report Of Two Cases

I Mishra, S Mishra, S Pati, D Mohapatra

## Citation

I Mishra, S Mishra, S Pati, D Mohapatra. *Renal Tubular Acidosis Presenting As Severe Hypokalemia With Respiratory Paralysis: Report Of Two Cases*. The Internet Journal of Tropical Medicine. 2005 Volume 3 Number 1.

## Abstract

Hypokalemia is usually asymptomatic and goes undetected. Or it may manifest as muscular weakness, fatigue, abdominal distension. Severe hypokalemia may lead to cardiac arrhythmias and even death. However, respiratory paralysis leading to hypoventilation and respiratory failure is uncommon and very rarely reported in the literature. We report two patients of hypokalemia with quadriplegia who developed respiratory paralysis and cyanosis, requiring ventilatory support. Both were diagnosed as cases of renal tubular acidosis.

## INTRODUCTION

Hypokalemia is a common electrolyte disturbance encountered in clinical practice. Common clinical conditions in which hypokalemia is found are diarrhea, vomiting, hypokalemic periodic palsy, overuse of diuretics, diabetic ketoacidosis etc. Clinically, hypokalemia presents with muscular weakness, fatigue, abdominal distension. Severe hypokalemia may lead to cardiac arrhythmias and even death. However, respiratory paralysis leading to hypoventilation and respiratory failure is uncommon and very rarely reported in the literature<sup>1,2,3,4</sup>. These are associated commonly with renal tubular acidosis<sup>1,2,3</sup> or Sjogren syndrome<sup>2</sup>.

We report two such cases of hypokalemia who developed respiratory paralysis and required ventilatory support.

## CASE 1

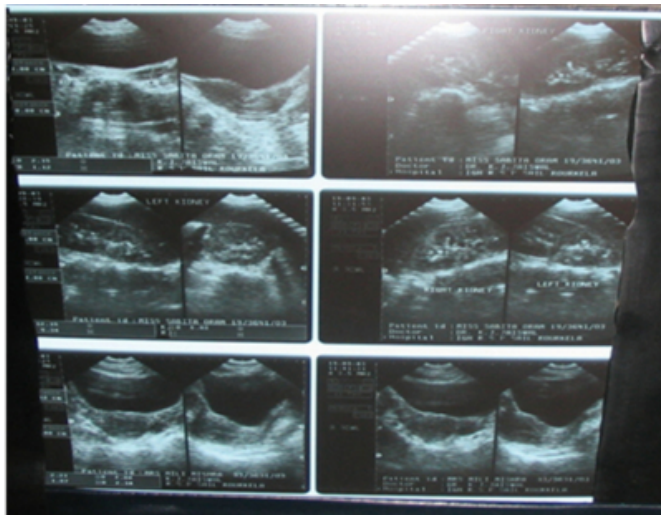
An eight year old girl presented with weakness of all four limbs for three days. She developed breathing difficulty and was brought to the hospital. She had no history of vomiting, diarrhea, or fever. She was not a diabetic nor any history of drug or diuretic use. There was no family history suggestive of endocrine disorders or metabolic disorders. Mile stones of development were normal. At the time of admission, she was drowsy, dehydrated, tachypnoeic with respiration rate of 40 / minute. Heart rate was 100 bpm, BP: 110/70 mm of Hg. There were no abnormal signs in lungs and heart. Neurological examination showed decreased power in all four limbs (Grade - II/V). Limb muscles were flaccid, deep

tendon jerks were diminished. She was cyanosed in spite of high flow oxygen therapy by mask as well as nasal prongs. Her sensorium started deteriorating. She was therefore put on ventilator.

Investigations: Hb 10g/dl, Serum K<sup>+</sup> 2.1 mEq/l, Na<sup>+</sup> 137 mEq/l, pH 7.18 bicarbonate 8.5meq/l, Chloride 129 mEq/l, P<sub>a</sub>CO<sub>2</sub> 23.6 mm of Hg, P<sub>a</sub>O<sub>2</sub> : 74. U waves were seen in ECG. Urine pH was 7.2, urine calcium 125mg per twenty four hours and potassium was 27 meq /l. Trans tubular potassium concentration gradient (TTKG) was 4.6. Ultrasound KUB showed bilateral nephrocalcinosis. She improved over... days and was weaned from the ventilator. She was discharged from the hospital on... days. She was admitted once more to the hospital in subsequent years, but made a prompt recovery on appropriate management with sodium bicarbonate.

**Figure 1**

Figure 1: Ultrasonography showing Nephrocalcinosis (Case-1)



**CASE 2**

A thirty eight year old woman presented with progressive weakness of limbs for four days and breathing difficulty for five-six hours . She was treated elsewhere with potassium chloride with the provisional diagnosis of hypokalemic periodic paralysis .On examination she was dyspnoeic with a respiration rate of 32/min, heart and lungs showed no abnormality.

Neurological examination revealed diminished power in both upper and lower limbs ( Gr II-III/ V), and diminished deep tendon jerks .There was hypokalemia (2.8meq/l), blood pH 7.21,  $\text{HCO}_3^-$  :11.7meq/l and  $\text{PaCO}_2$  27 mm of Hg. Urine pH was 7.1 and potassium 31meq /l . ECG showed U waves in V2 to V5 with T inversion . TTKG was 4.2 . Oxygen saturation was 80% . She required ventilatory support for 48 hours.

Both the patients recovered completely with Inj. sodium bicarbonate, intravenous potassium, antibiotics and ventilatory support. There was no evidence of Sjogren's disease in any of them.

**DISCUSSION**

Mild hypokalemia is invariably clinically insignificant and goes undetected. However, significant hypokalemia can cause weakness, and cardiac arrhythmia. They respond to treatment with potassium supplementation either orally or intravenously. However, respiratory distress amounting to cyanosis is very unusual.

Gambar et al<sub>1</sub> from India reported a case of 26 year old lady with hypokalaemic quadriplegia, acute respiratory failure and life-threatening cardiac arrhythmias. She was diagnosed as a case of distal renal tubular acidosis. She had persistent metabolic acidosis with severe hypokalaemia and required mechanical ventilation and potassium replacement.

Poux et al<sub>2</sub> from France described a 38 year woman with hypokalemic flaccid quadriplegia with sudden respiratory arrest. The woman was found to have distal renal tubular acidosis which lead to the diagnosis of primary Sjogren's syndrome. This case was compared to 8 similar cases previously described in the literature till 1992.

Haddad S et al<sub>3</sub> from S Arabia a 33-year-old female patient admitted to the ICU with ascending muscle weakness leading to acute hypercapneic respiratory failure following 10-day history of severe diarrhea and vomiting. Investigations revealed severe hypokalemia, mixed metabolic and respiratory acidosis, and renal impairment.

Le Corre A et al<sub>4</sub> from France described an unusual cause of acute respiratory distress in 2000. in a 54-year-old patient was admitted for ketoacidosis with acute respiratory distress. The main and unusual cause of being hypophosphataemia. Correction of the metabolic acidosis by insulin therapy resulted in intracellular penetration of phosphate and potassium, causing severe hypophosphataemia and hypokalaemia responsible for Acute respiratory distress.

In our hospital, though we encounter several cases of periodic paralysis due to hypokalemia we suspected these cases to be different and probed for possibility of other etiology.

In both the cases, the patients had muscular hypotonia, hypokalemia, decreased blood bicarbonates, decreased blood pH, and alkaline urine. Therefore both were diagnosed as cases of distal renal tubular acidosis. In most diseases, hypokalemia is associated with metabolic alkalosis, but in renal tubular acidosis metabolic acidosis is seen.

Renal tubular acidosis is a disorder of renal tubules having normal anion gap (hyperchloremic ) metabolic acidosis in the presence of normal glomerular function. In distal RTA there is deficiency of  $\text{H}^+$  ion secretion in distal tubules and collecting ducts. This can manifest as gradient limited defect where urine pH is always greater than 5.5 .

The kidney does not lower the urine pH either because the

collecting permits excessive back diffusion of H ion from lumen to blood or because they fail to transport H ion against a steep pH gradient.

Chronic acidosis lowers tubular reabsorption of calcium causing renal tubular hypercalciuria. The hypercalciuria, alkaline urine and low level of urine citrate cause calcium phosphate stones and nephrocalcinosis. This was observed in our first patient. The stunted growth in this case may be due to acidosis induced loss of bone minerals and inadequate production of 1,25 dihydroxycholecalciferol. In both children and in adults, since the kidney does not conserve potassium, hypokalemia occurs with the stress of an intercurrent illness. Acidosis and hypokalemia can be life threatening which was observed in both these cases.

These patients need intravenous sodium bicarbonate therapy. Use of oral or intravenous potassium alone will not ameliorate the condition.

## **CORRESPONDENCE TO**

Dr SK Mishra, MD Joint Director & Head Dept of Internal Medicine, Ispat General Hospital, Rourkela -769005, INDIA  
Email: sarojrk1@gmail.com

## **References**

1. Gombar S, Mathew PJ, Gombar KK, D'Cruz S, Goyal G. Acute respiratory failure due to hypokalaemic muscular paralysis from renal tubular acidosis. *Anaesth Intensive Care*. 2005 ;33:656-8.
2. Poux JM, Peyronnet P, Le Meur Y, Favereau JP, Charmes JP, Leroux-Robert C. Hypokalemic quadriplegia and respiratory arrest revealing primary Sjogren's syndrome. *Clin Nephrol* 1992 ;37:189-91.
3. Haddad S, Arabi Y, Shimemeri AA. Hypokalemic paralysis mimicking Guillain-Barre syndrome and causing acute respiratory failure. *Middle East J Anesthesiol*. 2004;17:891-7.
4. Le Corre A, Veber B, Dureuil B. An unusual cause of acute respiratory distress. *Ann Fr Anesth Reanim*. 2000;19: 549-51

**Author Information**

**Indira Mishra**

Ispat General Hospital

**Saroj K. Mishra**

Ispat General Hospital

**Sudhansu S. Pati**

Ispat General Hospital

**Devendra N. Mohapatra**

Ispat General Hospital