

# Abdominal Wall Endometriosis In General Surgery

H Hashim, S Shami

## Citation

H Hashim, S Shami. *Abdominal Wall Endometriosis In General Surgery*. The Internet Journal of Surgery. 2001 Volume 3 Number 2.

## Abstract

Endometriosis is a common gynaecological condition that sometimes presents to general surgeons as a lump in the abdomen in patients with no previous gynaecological history. It can pose a diagnostic dilemma and should be in the differential diagnosis of lumps in the abdomen. Diagnosis is usually made by histology.

## CASE HISTORY

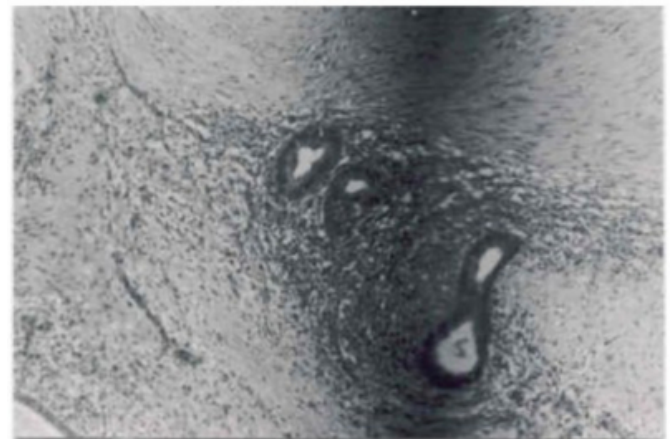
A fit 35-year-old lady was referred to the surgical outpatients clinic by her general practitioner (GP) with a swelling in the lower abdomen which appeared suddenly after exercise. She had no other medical or surgical problems. She had one full term and one pre-term vaginal delivery. The GP organised an abdominal ultrasound scan which revealed a 3 cm cystic lesion in the anterior abdominal wall below the umbilicus with distortion of the muscle fibres surrounding the mass. An incidental 1.6 cm cyst was noted in the right ovary. A radiological diagnosis of haematoma was made.

On questioning, the patient stated that the swelling had not changed in size and was not related to her periods. On clinical examination, she had a virgin abdomen (no scars) with a tender, well-defined, tense swelling in the lower abdominal wall. A provisional diagnosis of irreducible hernia was made.

At operation, a firm mass, arising from the rectus abdominis muscle and sheath, was excised with clear margins and sent to histology. Histological examination revealed firm brown tissue measuring 1.5 x 3.5 cm and many endometrial glands with stromal component and chronic inflammation (Fig. 1). A diagnosis of abdominal wall endometriosis was made.

## Figure 1

Figure 1: Endometrial stroma, glands and inflammatory cells



## DISCUSSION

Endometriosis is defined as the presence of endometrial tissue outside the lining of the uterine cavity. The tissue responds to hormones in a similar manner to that of normally sited endometrium and may result in cyclical symptoms including pain and bleeding during the menstrual cycle. Sites at which endometrial tissue has been found are shown in Table 1.

**Figure 2**

Table 1: Endometrial tissue sites

Ovaries
Pelvic peritoneum
Uterine ligaments
Bowel
Bladder
Umbilicus
Surgical abdominal wall scars
Lungs
Extremities

There are a number of theories of endometrioma formation <sup>1</sup>, including:

- Retrograde spread of collections of endometrial cells during menstruation
- Blood, lymphatic or iatrogenic spread
- Metaplasia of the pelvic peritoneal cells
- Immune system dysfunction and autoantibody formation

Laparoscopy and biopsy is the gold standard for the diagnosis of intra-abdominal endometriosis. On histology, endometrial glands and stroma are seen.

Endometriosis involving only the rectus muscle and sheath is very rare and the cases reported involve patients with abdominal surgical scars or tracts secondary to invasive abdomino-pelvic procedures. Endometriosis, in patients with scars, is more common in the abdominal skin and

subcutaneous tissue compared to muscle and fascia.

The actual incidence of abdominal wall endometriosis is unknown but one series reported that only 6% of these were unrelated to scars. In another series the prevalence of surgically proven endometriosis in scars was 1.6% <sup>2</sup>. The most common site is a caesarean section scar <sup>3</sup>.

A good surgical and gynaecological history, as well as a thorough examination with appropriate imaging techniques (ultrasound, CT or MRI) will usually lead to a correct diagnosis. This patient, however, had no elucidating features on history, clinical examination or investigation pointing towards endometriosis. The final diagnosis was made on histology. This is the first case of endometriosis, in the English literature, of the rectus abdominis muscle in a virgin abdomen.

## CONCLUSION

Endometriosis is a common condition affecting mainly women of child-bearing age and is usually dealt with by gynaecologists. It is the underlying cause of pelvic pain in about 15% of cases, however, some women with the condition present with abdominal pain and a mass to general surgeons and they pose a diagnostic dilemma. It should, therefore, be included in the list of differential diagnosis of an abdominal mass.

## CORRESPONDENCE TO

Hashim Hashim MBBS Department of General Surgery  
Oldchurch Hospital Waterloo Road Romford, Essex, RM7 0BE, UK hashim@doctors.org.uk

## References

1. Seydel AS, Sickel JZ, Warner ED, Sax HC. Extrapelvic endometriosis: Diagnosis and treatment. Am J Surg 1996; 171 (2): 239 - 241
2. Roberge RJ, Kantor WJ, Scorza L. Rectus abdominis endometrioma. Am J Emerg Med 1999; 17 (7): 675-7
3. Khetan N, Torkington J, Watkin A, Jamison MH, Humphreys WV. Endometriosis: presentation to general surgeons. Ann R Coll Surg Engl 1999; 81: 255-259

**Author Information**

**Hashim Hashim, MBBS**

Department of General Surgery, Oldchurch Hospital

**Shukri Shami, FCRS**

Department of General Surgery, Oldchurch Hospital