

# Effects Of Methanolic Extract Of *Aspilia Africana* Leaf On The Ovarian Tissues And Weights Of Wistar Rats

C Okwuonu, K Oluyemi, G Baxter, O Adesanya, V Ukwanya, B Odion, D Ofusori

## Citation

C Okwuonu, K Oluyemi, G Baxter, O Adesanya, V Ukwanya, B Odion, D Ofusori. *Effects Of Methanolic Extract Of Aspilia Africana Leaf On The Ovarian Tissues And Weights Of Wistar Rats*. The Internet Journal of Alternative Medicine. 2007 Volume 5 Number 2.

## Abstract

25 Cyclic female wistar rats were randomized into 5 groups (A, B, C, D & E) of 5 animals each. They were administered 0.00mg/Kg B.W, 100mg/Kg B.W, 150 mg/Kg B.W, 200 mg/Kg B.W, 250 mg/Kg B.W & 300 mg/Kg B.W. of methanolic extract of *Aspilia africana* respectively, once in a day, everyday of the week for 30 days. The animals' weights were taken before, midway and at the end of the experiment. Reduced wet weights of the ovaries were recorded at the end of experiment. Routine histological analysis of the Ovaries revealed derangement of granulosa cells, degeneration and reduction of follicles and poor vascularity of ovarian stroma.

## INTRODUCTION

From time immemorial, extracts from the leaves, seeds, fruits, barks and roots of plants have been used in the preparation of syrups and infusions in traditional medicine. These preparations have been used to treat cases ranging from the common cold to malarial, liver cirrhosis, hypertension, and so on. The active constituents contributing to these protective effects are the phytochemicals, vitamins and minerals (Okwu & Ekeke; 2003). Extracts from the roots, barks seeds and fruits of these plants are used in the preparation of syrups and infusions in traditional medicine for the treatment of various ailments. One of such plant is *Aspilia africana* (compositae). It is a semi-woody herb from a perennial woody root stock up to 2m high. The plant has served as food sources for cattle, sheep, hare and rabbits. Its phytochemical analysis reveals that it is rich in saponins, crude oil protein, sterols and terpenes.

*Aspilia africana* is one of the plants that contain a wide range of biological activity, including antiviral, fungicide and antibacterial due to the presence of thiarubrin, a derivative of 1,2-dithiocyclohexa-3,5-diene (Masato & Wu, 1994). Those plants that contain these rare compounds are used in popular medicine of equatorial Africa as remedy for abdominal infections. Review has it that leaves of *Aspilia africana* are swallowed wholly by chimpanzees to get rid of endoparasites (Rodriguez & Wrangham, 1992). It is believed

to have an anti-parasitic compound extracted in the intestine of the animal without necessarily digesting the leaves.

The cold extract of *Aspilia africana* appears to have a broad spectrum antibacterial activity because both Gram-positive and Gram-negative bacteria were sensitive to the extracts (Adeniyi & Odufowora, 2000).

Tamura et al (1997) reported that OSW-1 (3 beta, 16 beta, 17 alpha-trihydroxycholest-5-en-22-one 16-O-(2-O-4-methoxybenzoyl-beta-D-xylopyranosyl)- (1->3)-(2-O-acetyl-alpha-L-arabinopyranoside)), a steroidal saponin, decrease levels of ovarian steroids due to its direct inhibitory action on the gene expression of the steroidal enzyme and on the proliferation of granulosa cells in the ovary. Studies on contraceptives of plant origin are important because the synthetic hormonal contraceptives in current use produce some side effects. Records on folk medicine mention 225 species of plants with contraceptive and abortive properties. However, experiments performed on animals have confirmed the contraceptive effect in only 145 of these plant species. Chemically, these drugs belong to a wide variety of classes including terpenoids, alkaloids, glycosides, phenols, and other compounds (Korkhov & Mats, 1983). These chemicals are richly present in *Aspilia africana*.

It is the aim of present work to find out the effects of methanolic extract of the leaves of *Aspilia africana* on the

histo-architecture, weights of the ovaries and general body weights of the rats as indices for its reproductive toxicity.

## MATERIAL AND METHODS

### ANIMALS

25 cyclic female rats were sorted randomly selected from the animal house of the Igbinedion University, Okada, Edo State. The rats were fed on standard rat pellet produced by Bendel Feed and Flour mills limited. They were allowed access to water ad libitum and maintained under standard conditions. The animal room was well ventilated with a temperature range of 25 - 27°C under day/night 12-12 hour photoperiodicity. The rats were randomly grouped into five groups of 5 rats each A (0mg/kg), B (150mg/kg), C (200mg/kg), D (250mg/Kg) and E (300mg/Kg).

### PLANT MATERIALS

The plant material, *Aspilia Africana* leaves, were obtained from Okada village in Ovia North-East L.G.A of Edo State and authenticated by the botany Department, University of Benin. The leaves were sun-dried and grounded to fine powder. Crude methanolic extraction was done using 90% Methanol. The solution was filtered after 72 hours while the filtrate was concentrated to a semi solid form using the rotary evaporator, weighed and the solutions were prepared as 100mg/ml and 200mg/ml respectively.

### EXPERIMENTAL DESIGN

The administration of the extract was totally by gavage. Proper concentrations were administered by the use of metal oropharyngeal canula and calibrated hypodermic syringe. The administration of extract was done once in a day, everyday of the week for 30 days. The control group A received no extract but 1ml of distilled water, while Groups B, C, D and E received 150mg/kg B.W, 200mg/Kg B.W, 250mg/Kg B.W and 300mg/kg B.W. of the extracts respectively. The animals were sacrificed a day after the administration of extracts stopped using the humane method.

### TISSUE COLLECTION

The ovaries were dissected out by laparotomy immediately after sacrificing the animals. They were perfused in normal saline, blotted dry and weighed in electronic weighing balance. The ovaries were then fixed in 10% buffered formalin for histological assessment.

### ROUTINE HISTOLOGICAL PREPARATION

The histology of the ovaries was done by a method described

by Oluyemi et al (2007). The organs were fixed in 10% buffered formalin for a day after which it was transferred to ascending grades alcohol for dehydration. The tissues were passed through 50%, 70%, 90% and two changes of absolute alcohol and xylene for different durations before they were transferred into two changes of molten paraffin wax for 1 hour each in an oven at 65 °C for infiltration. They were subsequently embedded and serial sections cut using rotary microtome at 6 microns. The tissues were fixed into albumenized slides and allowed to dry on hot plate for 2 minutes. The slides were dewaxed with xylene and passed through absolute alcohol (2 Changes); 70 % alcohol, 50% alcohol and then to water for 5 minutes. The slides were then stained with Haematoxylin and Eosin. The slides were mounted in DPX. Photomicrographs were taken with x10 objective lens.

### STATISTICAL ANALYSIS

Data were statistical compared at p values <0.001 & <0.05

### RESULTS

**Figure 1**

Table 1.0: Weight Of The Ovaries After The Experiment

Group A (00mg/kg)	Group B (150mg/kg)	Group C (200mg/kg)	Group D (250mg/kg)	Group E (300mg/kg)
0.017±0.00	0.016±0.00 1 <sup>b</sup>	0.013±0.00 2 <sup>a</sup>	0.012±0.00 1 <sup>a</sup>	0.010±0.00 1 <sup>a</sup>

n=5, <sup>a</sup> Values significantly lower when compared with the control, <sup>b</sup> Values not significantly different when compared with the control. P<0.001

**Figure 2**

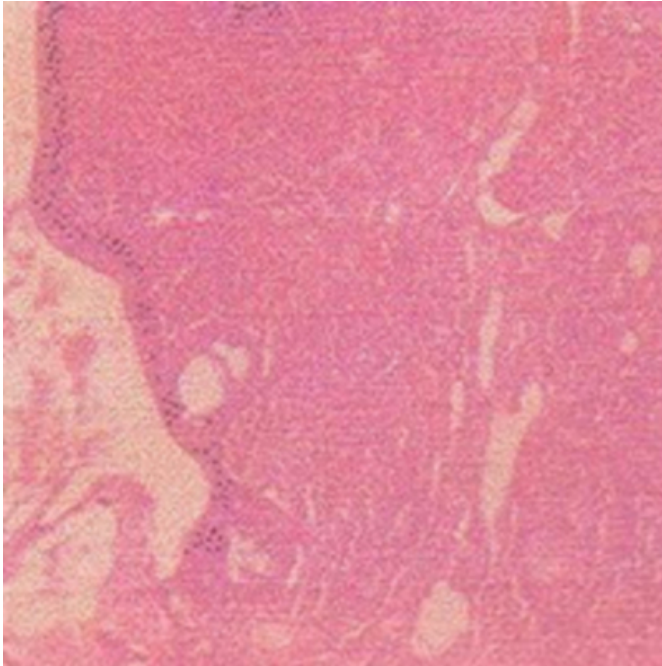
Table 1.1: Weight Changes In Rats Before, During And After The Experiment

Weight (g) <sup>a</sup>	Group A	Group B	Group C	Group D	Group E
At the onset	150±2.34 δ	164±0.30 ♀	155±1.10 ♀	172±0.23 ♀	175±0.52 ♀
Midway to experiment	165±1.48 δ	163±1.65 ♀	156±1.20 ♀	173±2.38 ♀	175±1.22 ♀
At the End of experiment	172±0.42 δ	166±2.30 ♀	155±1.50 ♀	173±0.22 ♀	175±0.01 ♀

<sup>a</sup> Values are recorded as Mean ± S.E.M; ♀ no significant difference when compared with the onset, δ value significantly different from the onset value. P<0.05

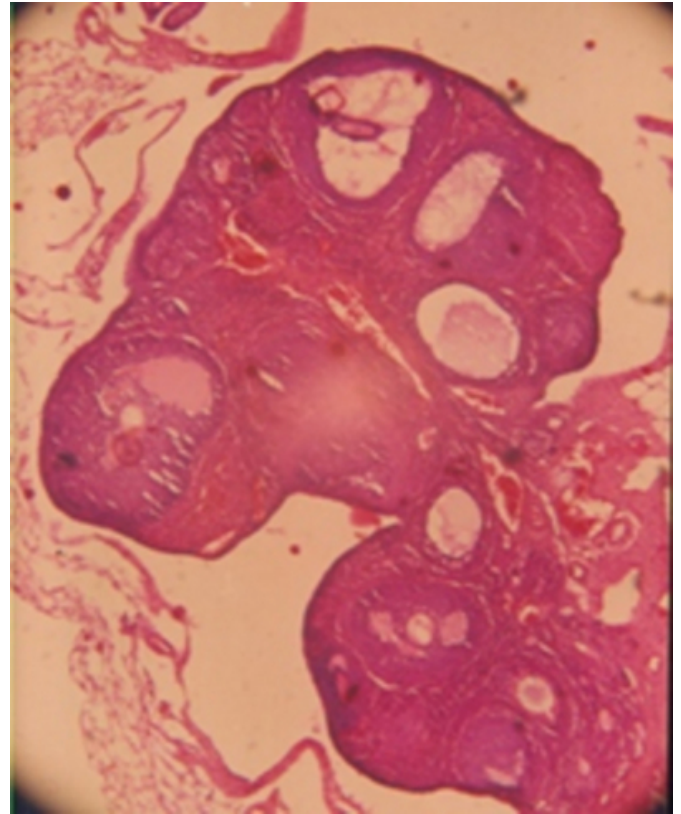
**Figure 3**

Figure 1.0: (Group A; 00mg/kg B.W) Photomicrograph of the ovary of control group. It shows intact ovarian tissues and few developing follicles in the cortex. The primary oocytes show no sign of alteration or degeneration. No visible active corpus luteums. Few corpora albicantia are present.



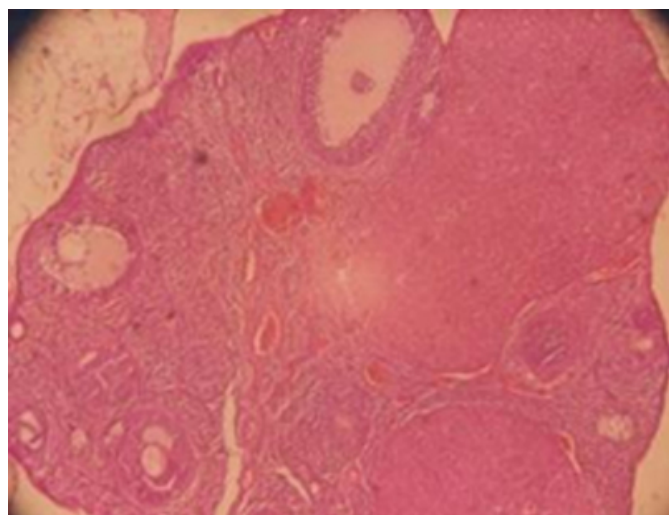
**Figure 4**

Figure 1.1: (Group B; 150mg/kg B.W) Photomicrograph of the ovary of group B. It shows large atretic follicles. It possesses few Graafian follicles with deranged granulosa cells. The ovarian stroma was compact with poor vascularity.



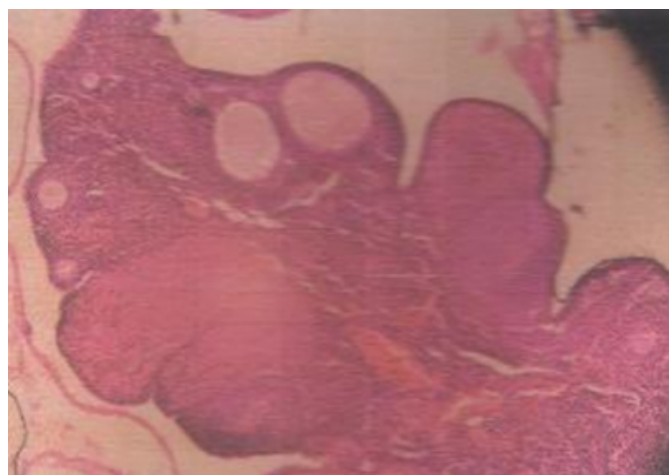
**Figure 5**

Figure 1.2: (Group C; 200mg/kg B.W) Photomicrograph of the ovary of group C. It shows fewer but very large atretic follicles, few Graafian follicles with deranged granulosa cells. The ovarian stroma was compact with poor vascularity.



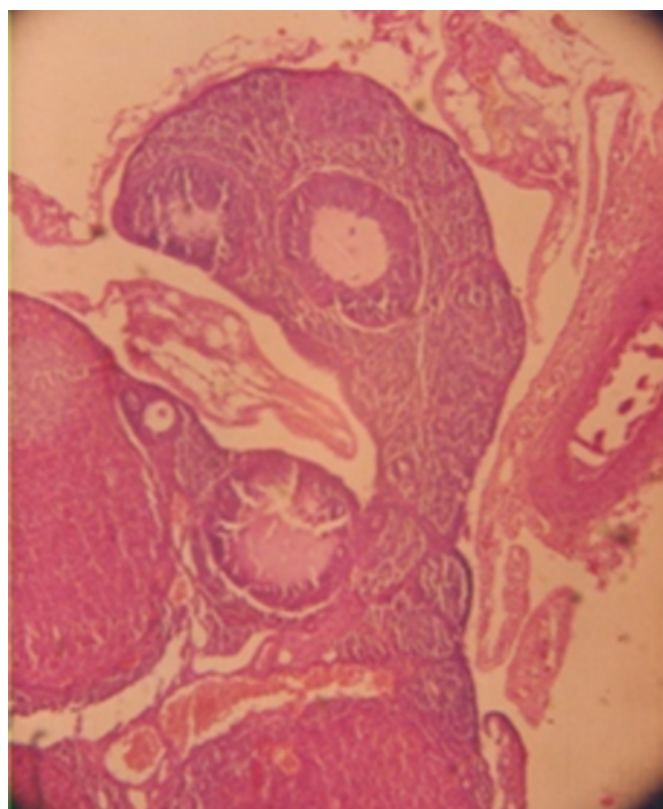
**Figure 6**

Figure 1.3: (Group D; 250mg/kg B.W) Photomicrograph of the ovary of Group D. It shows large atretic follicles with compact blood vessels.



**Figure 7**

Figure 1.4: (Group E; 300mg/kg B.W) Photomicrograph of the ovary of Group E. It shows the presence of a few numbers of follicles with degenerated oocytes.



In general, the surface epithelia of the ovaries are not affected.

## DISCUSSION

Table 1.0 gives the wet weights of the ovaries after the experiment. It reveals a dose-dependent decrease in the experimental rats when compared with the control group. This could probably be due to the saponins and glycoside contents of this plant. This is in line with the work of Wook-Joon et al, (2003) and Subhendu et al, (2006). They have been able to point out that plant rich in saponins and glycosides cause reduction in the wet weights of uteri and dry weights of ovaries of rats.

Table 1.2 shows the weight changes in the rats before, during and after the experimental period. When the values were compared with the onset weights of the animals, there were no significant differences. This means that methanolic extract of *Aspilia africana* slightly reduces the deposition of fat in the animal tissues especially the adipose tissues. Continuous deposition of fat in tissues is responsible for increase in weight. This is an indicator that *Aspilia africana*

could be used for anti-obesity purpose.

From the histology of the ovaries carried out, it is evident that *Aspilia africana* possesses anti-ovulatory properties as seen in the reduction of tertiary follicles with deranged granulosa cells. These are probably due to the abundance of saponins in *Aspilia africana*. In a similar work done by Wook-Joon et al (2003), Korean Ginseng saponins showed similar side effects on the ovarian functions and histology of immature rats. Abnormal oocytes characterized by different types of degeneration, such as fragmentation, parthenogenesis, irregular shape or amorphous opaque mass of vitelline material and empty zona pellucida were reported after the administration of saponins. These are the effects we also observed in this work. Our results therefore justify the usage of *Aspilia africana* leaves, by the Mbaise and other

Igbo Speaking people of Nigeria, which they boil and filter to prevent conception (Okwuonu, Personal communication). In another work, the presence of saponins, tannin, steroids, alkaloids, glycosides and terpenes has been found to possess anti-ovulatory and anti-fertility properties (Subhendu et al, 2006). Most of these compounds are present in *Aspilia africana*, hence its corresponding side-effects on the ovaries of experimental rats.

## References

- r-0.
- r-1.
- r-2.
- r-3.
- r-4.
- r-5.
- r-6.
- r-7.
- r-8.

**Author Information**

**Christina U. Okwuonu**

Department of Anatomy, School of Basic Medical Sciences, Igbinedion University

**Kayode A. Oluyemi**

Department of Anatomy, School of Basic Medical Sciences, Igbinedion University

**Grillo D. Baxter**

Department of Anatomy, School of Basic Medical Sciences, University of Benin

**Olamide A. Adesanya**

Department of Anatomy, School of Basic Medical Sciences, Igbinedion University

**Victor O. Ukwanya**

Department of Anatomy, School of Basic Medical Sciences, University of Lagos College of Medicine

**Blessing I. Odion**

Department of Medicine, School of Medical Sciences, University of Benin

**David A. Ofusori**

Department of Anatomy, School of Basic Medical Sciences, Igbinedion University