

A Case Report of Acute Renal Artery Occlusion Mimicking Acute Appendicitis

S Abouel-Enin, A Douglas, R Morgan

Citation

S Abouel-Enin, A Douglas, R Morgan. *A Case Report of Acute Renal Artery Occlusion Mimicking Acute Appendicitis*. The Internet Journal of Surgery. 2004 Volume 7 Number 1.

Abstract

Acute occlusion of the renal artery is only infrequently recognised clinically and even less frequently treated (1). We report a case of spontaneous right renal artery occlusion presenting with features suggestive of acute appendicitis.

INTRODUCTION

Because the signs and symptoms of acute renal artery occlusion can mimic those of many more common diseases, prompt diagnosis is aided by an awareness that an occlusive renovascular event may have occurred (2).

The clinical features of the condition are not well recognised and diagnosis is frequently delayed prejudicing successful treatment (1).

CASE REPORT

A 56 year old man presented to the emergency department with right iliac fossa pain associated with nausea and vomiting. He described his pain as sharp and constant. There was no history of trauma, fever, rigors, chills or haematuria.

Examination revealed temperature of 37.5°, blood pressure 196/108 and pulse 90/minute. Abdominal examination showed tenderness and rebound tenderness over the right iliac fossa. The remainder of his physical examination was normal.

His investigations revealed an elevated white blood cell count (WBC, $14.4 \times 10^2/L$) and C-reactive protein (CRP, 168 mg/dl). Urinalysis was normal. His kidney function tests showed serum creatinine of 175 μmol . Liver function tests and amylase were normal. Plain abdominal X-ray was normal. Abdominal ultrasound was normal.

A diagnosis of acute appendicitis was made. The patient underwent an emergency appendectomy, in which a normal non-inflamed appendix was removed, and the cause of the abdominal pain was not identified.

He presented 2 weeks later with a severe headache and blood pressure of 230/129. Blood tests revealed low potassium (K, 2.8 mmol), serum creatinine of 140 μmol and a metabolic alkalosis.

An abdominal ultrasound (Figures 1 and 2) revealed that the right kidney was smaller in size than the left, and had decreased in size in comparison with the previous ultrasound study done 2 weeks earlier. An ischaemic renal event was suggested .A magnetic resonance imaging scan (MRI) confirmed the marked discrepancy in the renal size. A renal angiogram (Figure 3) revealed a completely occluded right renal artery. A retrospective diagnosis of an acute right renal artery occlusion was made, which was felt to account for his original presentation with right iliac fossa pain.

Figure 1

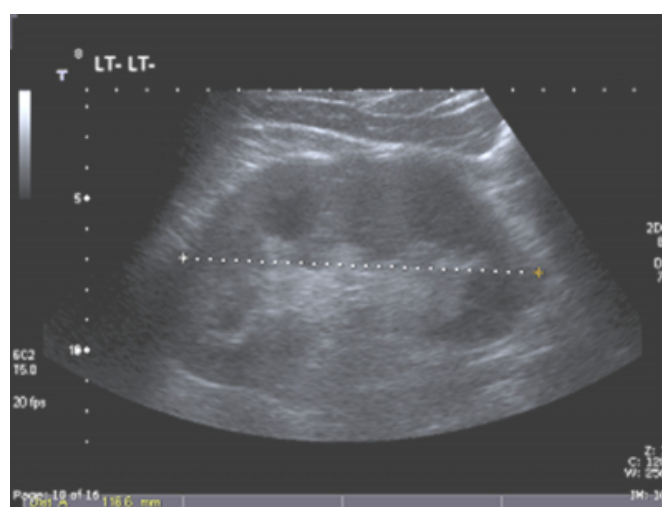


Figure 2

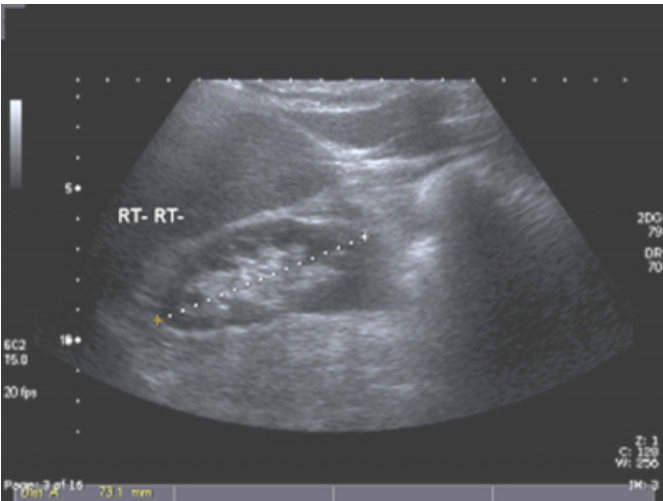
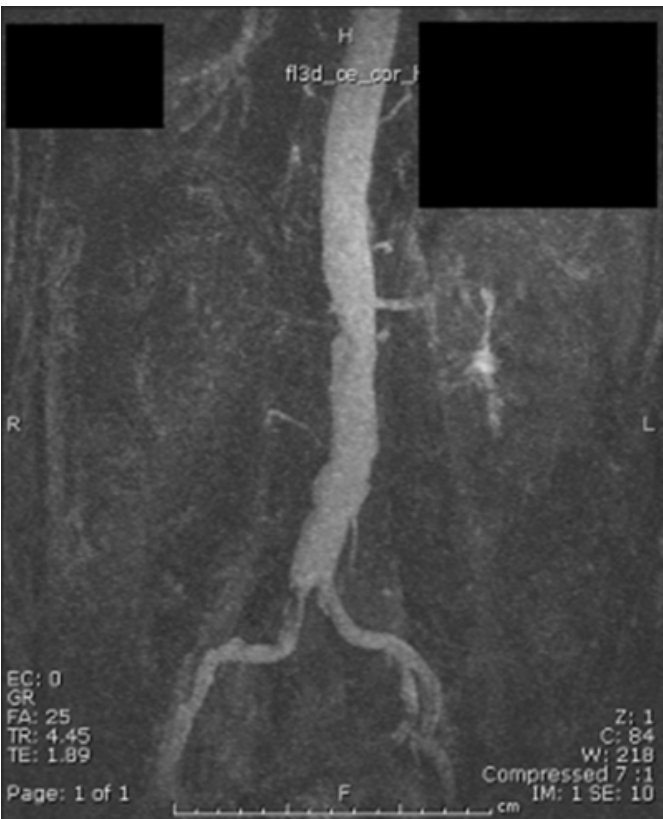


Figure 3



The patient was referred to the renal medicine outpatient clinic for follow-up. His hypertension was difficult to control despite three-drug therapy. However, his renal function returned to normal.

DISCUSSION

The management of patients with suspected appendicitis is associated with a high proportion of explorations during which the appendix is found not to be inflamed(3). Such

negative explorations have been accepted in the past as an unavoidable consequence of the principle of early exploration to prevent perforation of the appendix, but this is becoming increasingly questioned(4) . The promising new diagnostic techniques such as ultrasound and computed tomography (CT) have not gained widespread acceptance, and in most hospitals in the United Kingdom the management of patients with suspected appendicitis continues to be based on the clinical diagnosis (4) .

In a study done on 221 patients (5) who had operations for suspected appendicitis, the diagnosis was confirmed in 175 patients. The remaining 46 patients had other diagnoses (Table 1).

Figure 4

Diagnosis	Number
Appendicitis	175
Tubal/ovarian abscess	16
Diverticulitis	14
Meckel diverticulitis	8
Ectopic pregnancy	4
Ovarian teratoma	2
Volvulus	2
Total	221

Acute renal artery occlusion has not been previously reported to present with an appendicitis-like clinical picture.

Acute renal artery occlusion is a rare condition. Hoxie and Cogan (6) identified 205 cases of renal infarction from 14,411 autopsies done at a hospital (1.4%). Renal embolism had been diagnosed clinically in only 2 cases of these 205 (less than 1%).

Acute renal artery occlusion can be due to embolism, trauma or less commonly thrombosis. Most patients are middle-aged and have varied chronic underlying diseases. The patient may complain of persistent abdominal pain, fever, nausea, vomiting, anorexia, and back or flank pain (2).

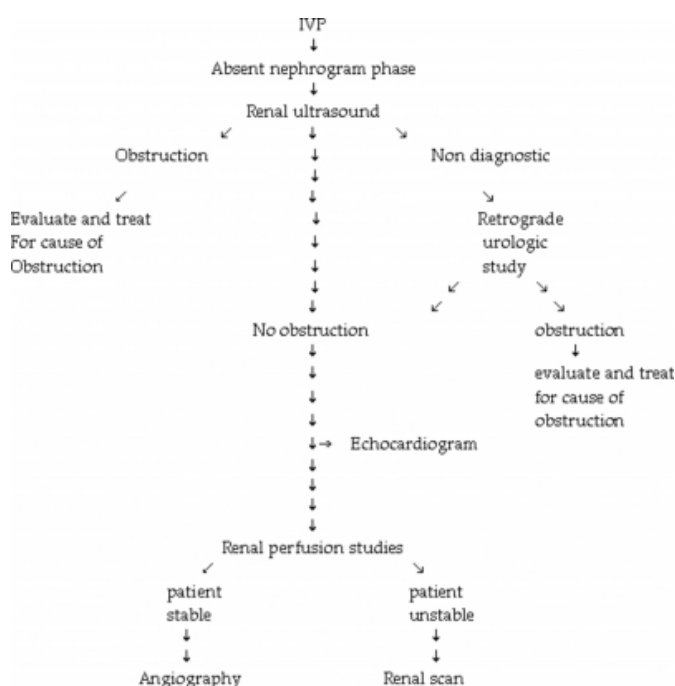
The diagnosis is often delayed most commonly due to a mistaken diagnosis of ureteric colic, and failure to substantiate such a diagnosis with early radiology. The diagnosis of acute renal artery occlusion should be considered in patients with cardiac disease who present features suggestive of ureteric colic (1). Acute renal artery occlusion can also be misdiagnosed as pyelonephritis, cholecystitis, pancreatitis, gastroenteritis, perinephric abscess or pneumonia.

Once the diagnosis of acute renal artery occlusion has been suspected clinically, it requires radiological confirmation. Characteristic radiographic findings in renal arterial

occlusion are described by Teplick and Yarrow (7): "A non-functioning kidney of normal size in conjunction with a normal retrograde pyelogram can be considered diagnostic of arterial occlusion of the renal artery". Radiologic evaluation usually begins in the emergency department with intravenous pyelography (IVP) to investigate the possibility of ureteric calculi when a patient has acute flank pain and associated microscopic haematuria. In an acute renal vascular accident, not only is a nephrogram phase absent on the affected side on delayed films after several hours, but the hyperdense nephrogram that often accompanies an obstructing stone is also characteristically absent. When absence of nephrogram phase on the affected side is confirmed by IVP with delayed films, not only vascular occlusion but also severe obstructive uropathy must be considered and ruled out. A diagnostic algorithm (Fig. 4) is presented here as a suggested approach to further evaluation of such patients (8).

Figure 5

Figure 4: Algorithm for diagnosis of renal artery occlusion



In patients with suspected acute renal artery occlusion, serum LDH has been found to be a very sensitive marker of infarction. However, cases that present early after the infarction may not show elevation of LDH, and it may be necessary to repeat LDH measurement after 24 hours. Urinary LDH can be helpful in differentiating the causes of serum LDH elevation. Contrast enhanced CT is safe, non-invasive, easily available, and highly accurate. Renal angiography is not required unless an operative approach is

considered. (8)

In our case a confident clinical diagnosis of acute appendicitis was made.

An IVP or contrast CT might have been of great value in revealing the correct diagnosis, but these were not indicated, as the patient did not have microscopic haematuria or flank pain.

Once renal artery occlusion has been diagnosed, the time of ischaemia of the affected kidney has usually passed already for trying thrombolysis or thrombectomy in the majority of these patients. In these cases, only anticoagulative drug therapy is recommended. Nephrectomy can be required if severe hypertension develops during follow-up. (9)

In our case the condition was diagnosed 2 weeks after the initial presentation, which was too late to consider thrombolysis or thrombectomy.

CONCLUSION

We present a case of acute right renal artery occlusion with an unusual presentation, which mimicked acute appendicitis. The absence of haematuria, and a normal ultrasound scan did not suggest any renal pathology. In patients with suspected acute appendicitis, a high index of suspicion should be maintained for rare diagnoses such as acute renal artery occlusion.

CORRESPONDENCE TO

Dr. Sherif Abouel-Enin 14 south drive Rhyll, UK LL18 4ST
Tel: 0044-779 5681 573 Email: S_enin@hotmail.com

References

1. McRae CU. Acute renal artery occlusion. *N Z Med J.* 1975;82:344-6.
2. Dell'Aria JC, Petrilli R, Schwartz E. Acute occlusion of renal artery manifested by hypertensive crisis. *J Emerg Med.* 1988;6:23-7.
3. Andersson RE, Hugander A, Thulin AJG. Diagnostic accuracy and perforation rate in appendicitis: association with age and sex of the patient and appendectomy rate. *Eur J Surg.* 1992;158:37-41.
4. Andersson RE, Hungander AP, Ghazi SH, Raven H, Offenbartl SK et al. Why does the clinical diagnosis fail in suspected appendicitis? *Eur J Surg.* 2000;166:796-802.
5. Denizbasi A, Unluer EE. The role of the emergency medicine resident using the alvarado score in the diagnosis of acute appendicitis compared with the general surgery resident. *Eur J Emerg Med.* 2003;10:296-301.
6. Hoxie HJ, Coggin CB. Renal infarction, statistical study of two hundred and five cases and detailed report of an unusual case. *Arch Int Med.* 1978;89:477-482.
7. Hall SK. Acute renal vascular occlusion: an uncommon mimic. *J Emerg Med.* 1993;11:691-700.
8. Singh G, Dhawan R, Potteiger C et al. Acute Renal

infarction secondary to left ventricular thrombus, masquerading as a renal calculus- A case report and brief review of literature. *Angiology*. 2001;52:717-720.
9. Theiss M, Wirth MP, Dölken W, Frohmüller H.

Spontaneous thrombosis of the renal vessels. Rare entities to be considered in differential diagnosis of patients presenting with lumbar flank pain and haematuria. *Urol Int*. 1992;48:441-445.

Author Information

Sherif Abouel-Enin, MBBCh

Senior house officer, Department of General Surgery, Glan Clwyd Hospital

Alistair Douglas, FRCP

Consultant nephrologist, Department of Nephrology, Glan Clwyd Hospital

Richard Morgan, M.D.

Consultant surgeon, Department of General Surgery, Glan Clwyd Hospital