

# Embryonal Sarcoma Of The Liver: A Case Report

U Devi, S Digumarthy, N Peri, J Reddy, Bheerappa, C Sundaram

## Citation

U Devi, S Digumarthy, N Peri, J Reddy, Bheerappa, C Sundaram. *Embryonal Sarcoma Of The Liver: A Case Report*. The Internet Journal of Pathology. 2002 Volume 2 Number 2.

## Abstract

Undifferentiated (embryonal) sarcoma of the liver is a rare primary malignant tumor of the liver occurring almost exclusively in childhood with characteristic discordant findings on Ultrasonography and Computed Tomography. We report a case of hepatic embryonal sarcoma in a seven-year old male child.

## INTRODUCTION

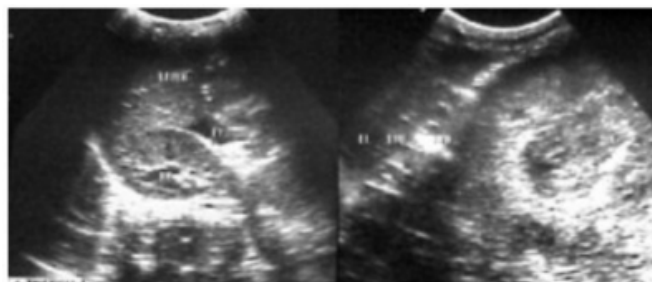
Undifferentiated Embryonal sarcoma (UES) of the liver is a rare malignancy that is found in children and young adults. We present here a case of primary hepatic UES in a young child.

## CASE REPORT

A seven-year-old male child presented with abdominal distension and pain since one month. He also had low-grade fever and loss of appetite. Clinical examination revealed a large mass in the abdomen. Abdominal sonography revealed a large mixed echogenic mass lesion in the peritoneal cavity and another small mass in the right lobe segments V and VI. The continuity of the liver lesion with intraperitoneal mass could not be clearly made out. There was minimal free fluid. Color Doppler showed minimal vascularity. Contrast-enhanced Computed tomography of the abdomen revealed a large (18x14x15cm) intraperitoneal hypodense lesion in the subhepatic region with faint heterogeneous enhancement. Large non-enhancing hypodense areas were noted within suggestive of cystic degeneration; there was no calcification in the lesion. The plane of cleavage between the lesion and liver was obliterated. There was mass effect with displacement of adjacent structures. Serum Alpha Fetoprotein level was normal. The patient was operated and peroperatively there was a large multilobulated vascular exophytic mass arising from the inferior surface of the right lobe of the liver involving segments V, VI and VII. Excision of the mass along with partial hepatectomy was performed. The histopathological diagnosis was Undifferentiated Embryonal Sarcoma of the liver.

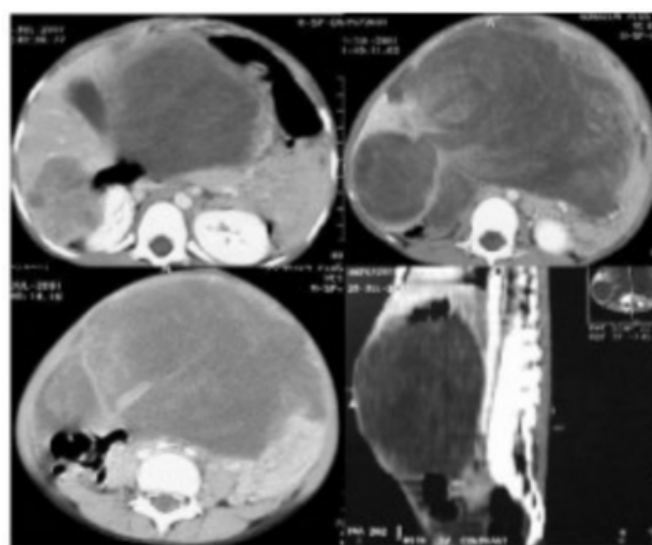
## Figure 1

Fig.1: Ultrasonography of abdomen showing a mixed echogenic mass in the subhepatic region



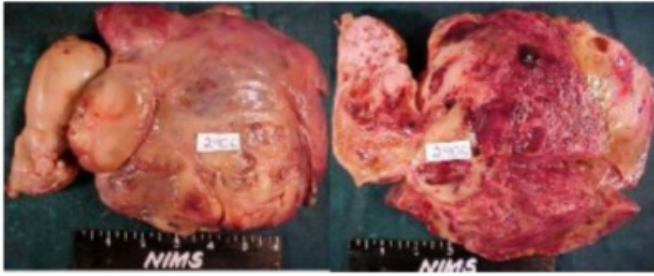## Figure 2

Fig.2: CECT abdomen showing a large lobulated hypodense lesion with faint enhancement in the liver with large exophytic component



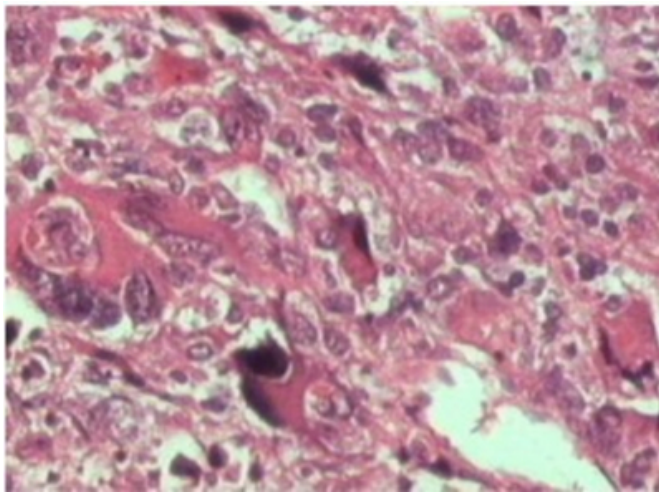
**Figure 3**

Fig.3: Gross specimen showing large multilobulated fleshy lesion with areas of hemorrhage and cystic degeneration



**Figure 4**

Fig.4: Photomicrograph showing spindle cells, bizarre giant cells and high mitotic activity



## DISCUSSION

Undifferentiated Embryonal sarcoma known in the past as malignant mesenchymoma is a rare malignant hepatic tumor. It occurs predominantly in older children aged 6-10 years [1]. However, a few cases were reported in adults also. [2,3] UES is the fourth most common pediatric malignant hepatic tumor following hepatoblastoma, infantile haemangioendothelioma and hepatocellular carcinoma. [4] It represents about 9%-15% of all hepatic tumors in children. Less than 100 cases have been reported. [5]

Patients present with abdominal pain and mass with fever, weight loss, jaundice or other gastrointestinal complaints. Interestingly, serum AFP is not elevated.

Buetow et al reviewed the pathologic and radiologic findings in 28 cases of UES. [6] Pathologically, the tumor is usually a large, solitary mass predominantly solid (about 83% of the volume of a tumor) with the rest of it being cystic filled with serosanguineous fluid. On ultrasonography, the lesion

appears predominantly solid (iso-hyperechoic to liver parenchyma) with few cystic areas due to cystic degeneration or hemorrhage. On CT, it appears predominantly hypodense, of water attenuation; areas of intermediate and soft tissue attenuation are noted in the periphery of the lesion due to solid component; foci of hemorrhage appear hyperdense; occasionally fluid-debris levels are also noted. Delayed CECT images are useful in revealing the solid nature and areas of the tumor as foci of contrast enhancement. On MRI, the lesion is predominantly of CSF signal intensity; areas of cystic degeneration appear hypointense on T1 weighted images and hyperintense on T2 weighted images; there can be hyperintense foci on T1W images due to hemorrhage; inhomogeneous enhancement of the thick peripheral zone can occur due to the solid portion of the tumor [4]. This discrepancy in the appearance on Ultrasonography (predominantly solid) and CT/MRI (predominantly fluid is considered to be due to the increased water content in the abundant myxoid stroma of the tumor. It is also noted in myxoid tumors occurring in other organs of the body. It is very essential to consider UES in the differential diagnosis of a lesion with discordant findings on USG and CT to avoid inappropriate aspiration of the lesion. Occasionally, the lesion can be predominantly cystic on USG and can be mistaken for a hydatid cyst. [5]

Interestingly, on angiography, UES can be a hypovascular or avascular mass; neoplastic vascularity in the form of macroaneurysm, arteriovenous shunting, pooling of contrast material and vascular encasement can be found in the solid portion of the tumor. Macroaneurysms are characteristic of UES.[4]

The treatment of choice is complete resection with pre- or post-operative multidrug chemotherapy. Pre-operative chemotherapy is proven to reduce the size of the tumor with necrosis and fibrosis of the solid portions and foci of dystrophic calcification. [7] However, the prognosis is poor due to the advanced nature of the disease at the time of presentation, the median survival being less than a year following surgery.

## CORRESPONDENCE TO

Dr. Uma Devi.M, MD, DNB 12-11-1403, Boudhanagar, Warasiguda Secunderabad Andhra Pradesh - 500 061 India  
Tel. Ph: 040-7074822; E-mail: bkssastri@hotmail.com

## References

1. Stocker JT, Ishak KG. Undifferentiated (embryonal) sarcoma of the liver: report of 31 cases. *Cancer* 1978; 42:

336-348

2. Yedibela S, Rock T, Ott R, Muller V, Papadopoulos T, Hohenberger W. Undifferentiated embryonal sarcoma as a rare cause of spontaneous liver rupture in adults. *Chirurg* 2000; 71: 101-105

3. Diedhiont, Genin P, Terris B, Sauvanet A, Belghiti J, Degott C. Undifferentiated embryonal sarcoma of the liver in an adult: a case report. *Ann Pathol* 2002; 22:134-136

4. Woong Yoon, Jae Kyu Kim, Heoung Keun Kang. Hepatic Undifferentiated Embryonal Sarcoma: MR Findings. *JCAT* 1997; 21:100-102

5. SW Joshi, NH Merchant, NA Jambhekar. Primary

multilocular cystic undifferentiated (embryonal) sarcoma of the liver in childhood resembling hydatid cyst of the liver. *Br J Radiol* 1997; 70:314-316

6. Buetow PC, Buck JL, Brown LP, Marshall WH, Ros PR, Levine MS, Goodman ZD. Undifferentiated (Embryonal) Sarcoma of the Liver: Pathologic Basis of Imaging Findings in 28 cases. *Radiology* 1997; 203:779-783

7. Moon W.K, Kim W.S, Choi B.I, Kim I.O, Yeon K.M, Han M.C. Undifferentiated embryonal sarcoma of the liver treated with chemotherapy: CT imaging in four patients. *Abdom Imaging* 1995; 20: 133-137

**Author Information**

**Uma Devi, M, MD, DNB**

Assistant Professor, Dept. of Radiology, Nizam's Institute of Medical Sciences

**Subba Rao Digumorthy, MD, DNB**

Assistant Professor, Dept. of Radiology, Nizam's Institute of Medical Sciences

**Nagamani Peri, MD**

Clinical Registrar, Dept. of Radiology, Nizam's Institute of Medical Sciences

**Jagan Mohan Reddy, J, MD**

Addnl. Prof & HOD, Dept. of Radiology, Nizam's Institute of Medical Sciences

**Bheerappa, MS**

Associate Professor, Dept of Surgical Gastroenterology, Nizam's Institute of Medical Sciences

**C. Sundaram, MD**

Prof. & in-charge HOD, Dept. of Pathology, Nizam's Institute of Medical Sciences