

Synchronous bilateral germ-cell tumors of testis: A case report

B Suresh, P Sampath Kumar, M Mary, M Susmitha

Citation

B Suresh, P Sampath Kumar, M Mary, M Susmitha. *Synchronous bilateral germ-cell tumors of testis: A case report*. The Internet Journal of Surgery. 2008 Volume 21 Number 2.

Abstract

The incidence of bilateral testicular germ-cell tumors is 3.3%. Among these, only 5-24% occur synchronously. Very few cases of synchronous tumors with different histopathology like seminoma with contralateral mixed germ-cell tumor are reported. We describe a case in a 35-year-old male who presented with right testicular swelling. Investigations revealed raised tumor markers and bilateral testicular lesions on scrotal USG. Bilateral orchidectomy with right hemiscrotectomy was done. Histopathology showed a right testicular mixed germ-cell tumor and a left testis seminoma. This case is being presented for its rarity.

INTRODUCTION

Testicular tumors constitute 1% of all malignancies. Seminoma is the most common testicular tumor. Bilateral testicular tumors are rare and constitute only 2-3%. Only 5-24% among these occur synchronously. Synchronous tumors carry more risk of metastasis as they present at an advanced stage.

CASE SUMMARY

A 32-year-old male presented with abdominal pain and right scrotal swelling. The patient was diagnosed to have right-sided hydrocele in another hospital and planned for right hydrocelectomy. But the procedure was abandoned as the swelling was arising from the testis and the patient was referred to our hospital for further management. History of trauma or breathlessness was absent. Examination revealed an enlarged right testis with a right scrotal scar. The left testis was normal in size. Other organomegaly and lymphadenopathy were absent. Investigations revealed an α -fetoprotein of 18458ng/ml, a β -HCG of 3142mIU and a LDH of 2408U/L. Scrotal USG showed multiple nodular lesions in both testes. CT of the abdomen and pelvis and chest x-ray showed retroperitoneal and mediastinal lymphadenopathy, respectively. The patient was planned for right-side high inguinal orchidectomy, right hemiscrotectomy & frozen section of the opposite testis. Left testis frozen section was reported as seminoma. Hence, left high inguinal orchidectomy was carried out with right hemiscrotectomy. The patient was discharged on the 5th postoperative day. Histopathology revealed right testicular mixed germ-cell

tumor (seminoma, embryonal and choriocarcinoma) and left testis seminoma. Later, the patient was advised to undergo chemotherapy, radiotherapy, and regular follow-up.

Figure 1

Figure 1. Seminoma of the left testis showing nests of tumor cells having abundant clear cytoplasm, separated by fibrous septae (H&E, x200)

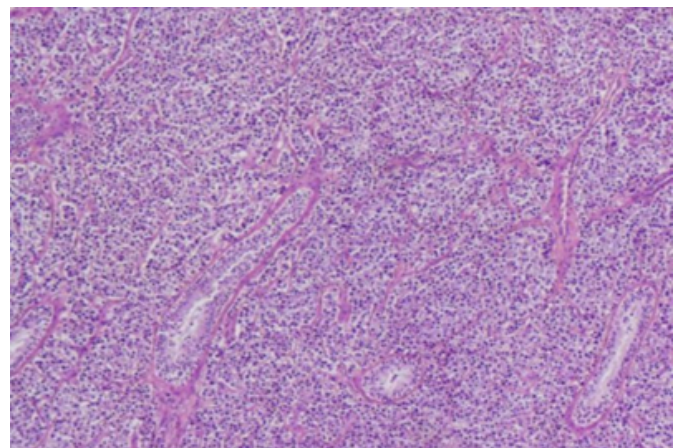
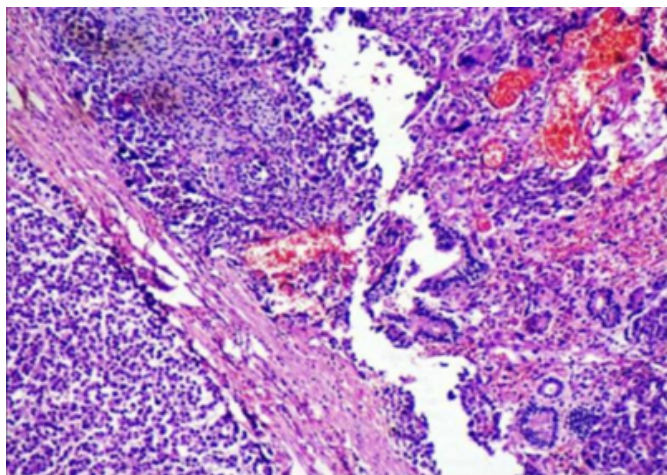


Figure 2

Figure 2. Mixed germ-cell tumor of the right testis showing choriocarcinoma, seminoma & embryonal carcinoma (H&E, x100)



DISCUSSION

Testicular tumors comprise 1% of all malignancies^[1] and may be germ-cell or sex-cord stromal tumors. The most common germ-cell tumor is seminoma. The other germ-cell tumors are choriocarcinoma, teratoma, embryonal carcinoma and yolk sac tumor (non-seminomatous). Germ-cell tumor can occur in testis, retroperitoneum, mediastinum and pineal gland. Only 2-3% of testicular tumors occur bilaterally^[2]. LDH, β -fetoprotein and β -HCG are the useful tumor markers^[3]. Common metastasis seen in testicular malignancy is to retroperitoneal and mediastinal lymph nodes. Choriocarcinoma metastasizes hematogenously.

Among bilateral testicular tumors, only 5 to 24% occur synchronously and the remaining 7-83% are metachronous^[4]. Different histology in synchronous bilateral testicular germ-cell tumors is extremely rare^[5]. Nearly 43 cases have been reported in the literature, of which only eight cases were of mixed germ-cell tumor with contralateral seminoma^[5]. Our case is the ninth case according to a review of the literature. Although bilateral orchidectomy has been largely accepted as standard treatment for bilateral testicular tumors, several

current studies have reported organ sparing approaches^[1,2]. In such cases, tumor diameter should not exceed 20-25mm, to preserve enough testosterone producing parenchyma. Enucleation/resection should always be performed under cold ischaemia to preserve the function of Sertoli and Leydig cells^[2]. Bilateral synchronous GCT carries significantly more risk of metastasis as it presents at an advanced stage compared to metachronous tumors^[1]. Ten per cent of bilateral synchronous GCT present with stage III disease^[1]. In our case, the patient presented with mediastinal and retroperitoneal lymphadenopathy (stage III disease). The prognosis depends on histological type, clinical stage and used therapeutic methods^[3].

CONCLUSION

Very few cases of synchronous germ-cell tumors with different histopathology like seminoma with contralateral mixed germ-cell tumor are reported. Although bilateral orchidectomy has been largely accepted as standard treatment for bilateral testicular tumors, currently organ sparing surgery is an emerging approach. Routine scrotal ultrasound should be done to rule out malignancy of the contralateral testis.

References

1. Akdogan B, Divrik RT, Tombul T, Yazici S, Tasar C, Zorlu F, et al. Bilateral testicular germ cell tumors in Turkey: increase in incidence in last decade and evaluation of risk factors in 30 patients. *J Urol* 2007; 178(1):129-133.
2. Reinberg Y, Manivel JC, Zhang G, Reddy PK. Synchronous bilateral testicular germ cell tumors of different histologic type. Pathological and practical implications of bilaterality in testicular germ cell tumors. *Cancer* 1991; 68(5): 1082-1085.
3. Ondrus D, Hornak M, Matoska J. Bilateral testicular germ-cell tumors - a single center long-term experience. *Int Urol Nephrol* 2001; 33 (3):521-4.
4. Holzbeierlein JM, Sogani PC, Sheinfeld J. Histology and clinical outcomes in patients with bilateral testicular germ cell tumors: the Memorial Sloan Kettering Cancer Center experience 1950 to 2001. *J Urol* 2003; 169(6):2122-2125.
5. Adham WK, Raval BK, Uzquiano MC, Lemos LB. Bilateral testicular tumors: seminoma and mixed germ cell tumor. *Radiographics* 2005; 25(3): 835-839.

Author Information

BP Suresh, MS

Department of Surgery, Kasturba Medical College

P Sampath Kumar, MS

Department of Surgery, Kasturba Medical College

M Mary, MD

Department of Pathology, Kasturba Medical College

MS Susmitha, MD

Department of Pathology, Kasturba Medical College