

# Bilateral Posterior Shoulder Fracture-Dislocation – A Diagnostic Challenge.

A Trollegaard, M Nygaard, B Madsen

## Citation

A Trollegaard, M Nygaard, B Madsen. *Bilateral Posterior Shoulder Fracture-Dislocation – A Diagnostic Challenge..* The Internet Journal of Orthopedic Surgery. 2009 Volume 17 Number 1.

## Abstract

A case of bilateral posterior shoulder fracture-dislocations following an epileptic seizure due to chronic alcohol abuse is described. The fracture-dislocations were missed primarily and were interpreted clinically as hemiparesis of the right arm with no damage to the left shoulder before they were diagnosed and treated firstly with closed reduction and later by open reduction and internal fixation. Treatment was operative with bilateral interlocking plates followed by bandaging with loose slings for four weeks with subsequent active physiotherapy. Results at follow-up after 38 weeks were excellent with Constant Shoulder Scores of 51/47 and no redislocations occurring.

## INTRODUCTION

Bilateral posterior shoulder fracture-dislocation is very rare, with only about 30 cases described in the literature [10]. Fewer than 5% of shoulder dislocations are posterior and an associated fracture is even more rare occurring in fewer than 1% of cases [2, 3, 8]. The diagnosis of posterior dislocation is frequently missed, probably because of the injury's relative rarity and the difficulty in interpreting clinical and radiographical findings [2]. Causes are epileptic seizures, electrocution including electroconvulsive therapy and extreme trauma (Triple "E" syndrome) [4] due to a fall with axial stress on flexed, internally rotated and adducted shoulders [2, 3, 8].

Besides pain, a posterior shoulder fracture-dislocation presents with a flattened anterior shoulder appearance and posterior fullness of the shoulder [2, 6, 8]. In slim individuals a prominent coracoid process may be felt [3]. The arm is internally rotated and adducted and cannot be abducted significantly. Active external rotation is impossible due to fracture pain and because the humeral head is fixed in internal rotation behind the glenoid cavity. Associated axillary nerve or radial nerve neuropraxia have been described. Differential diagnoses have been described as shoulder contusion, rotator cuff injury and dissecting thoracic aneurysm [1, 8, 9, 12]. Posterior shoulder fracture-dislocation can be complicated by posterior damage to the labrum (reverse Bankart lesion) as well as a reverse Hill-Sachs lesion [2, 9, 12].

We report a case of bilateral posterior shoulder fracture-dislocation. Both fracture-dislocations were missed clinically and radiographically at first, probably because an axillary X-ray was not obtained. Because of simultaneous seizure and unconsciousness the decreased function of the right arm was misinterpreted as hemiparesis. We believe it instructive to report this case due to the potential difficulty of diagnosing this rare injury clinically and radiographically. Furthermore, we also find it important to report what we believe is the first description of treatment with bilateral internal fixation using interlocking plates.

## CASE REPORT

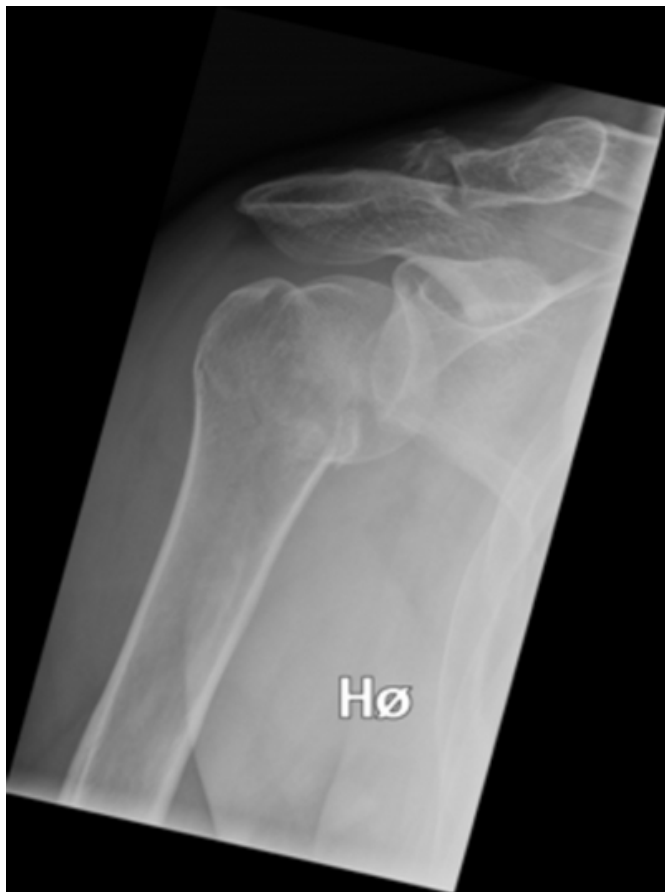A 44-year old man was referred to the Emergency Room suspecting a cerebral arterial embolism causing paresis of the right arm and a temporary loss of consciousness. No associated trauma or prior shoulder injury was reported. The patient had a history of chronic alcohol abuse but no seizure had taken place according to the patient and his girlfriend. No regular medication was being taken and there was no prior significant medical history. In the Emergency Room, the patient was examined by two junior doctors. He was fully alert and complained of pain in his right arm and shoulder but not in his left arm which, at that stage, was not examined further clinically or radiographically.

An extensive neurological examination did not find any neurological deficits and there had been no urinary or bowel incontinence. The right arm was warm, with normal colour and a pulse in the radial artery, while the left arm was not

described. The patient was quite muscular. He could not move his right arm due to severe pain from the elbow to the shoulder. Radiographs of the right shoulder and humerus were interpreted as normal besides an old lateral clavicle fracture (Figure 1 and 2), but an axillary image was not obtained due to pain and reduced mobility. Blood serology was normal. No final diagnosis was made and the patient was admitted to the neurological department for observation.

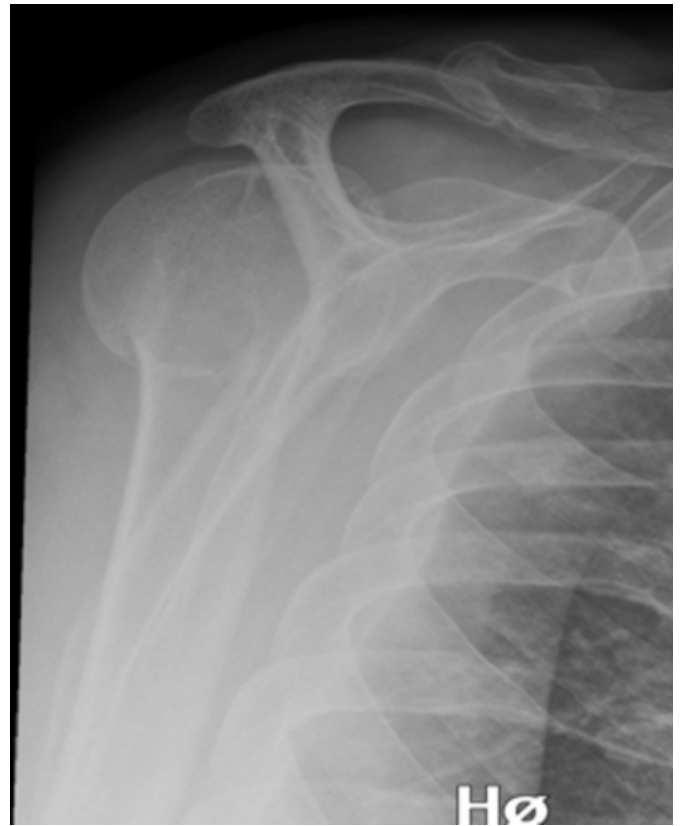**Figure 1**

Figure 1: The initial anteroposterior x-ray showing an undisplaced posterior fracture-dislocation of the right shoulder joint. The convex Moloney line (the curve from the lateral scapular margin to the medial proximal humeral shaft) is broken. No reverse Hill-Sachs lesion is seen. A lateral clavicle fracture of older date is seen.



**Figure 2**

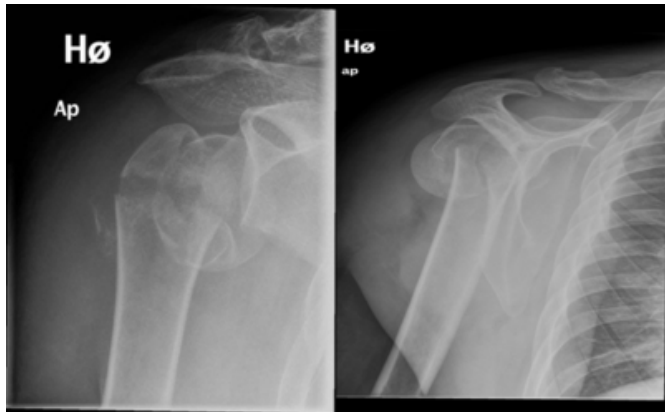
Figure 2: Lateral x-ray of the right shoulder with a posteriorly displaced humeral head.



On the following day, a radiographical review by an orthopaedic consultant interpreted the radiographs as a right posterior shoulder dislocation but no fracture was identified. Closed reduction was performed under general anaesthesia. A new X-ray showed a posterior fracture-dislocation with a displaced subcapital fracture in the right shoulder joint (Figure 3 and 4). Due to growing pain in the left shoulder, this joint was X-rayed on day 3 and a posterior fracture-dislocation was diagnosed there, too (Figure 5 and 6). The neurovascular status of the left arm was normal.

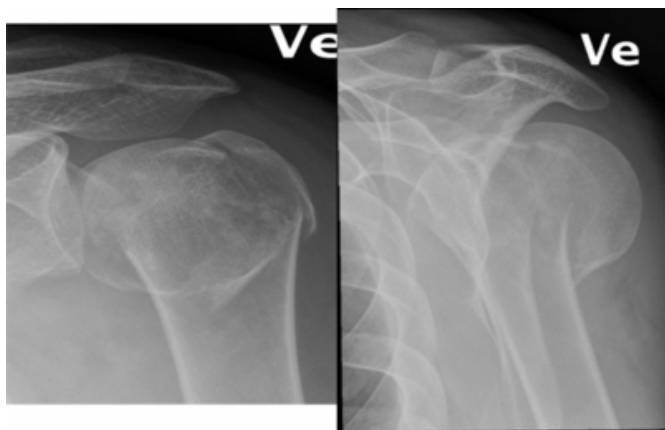
**Figure 3**

Figure 3 and 4: X-rays after closed reposition. The fracture is displaced.



**Figure 4**

Figure 5 and 6: An anteroposterior x-rays of the left shoulder showing a posterior fracture-dislocation. The fracture is displaced and comminute.

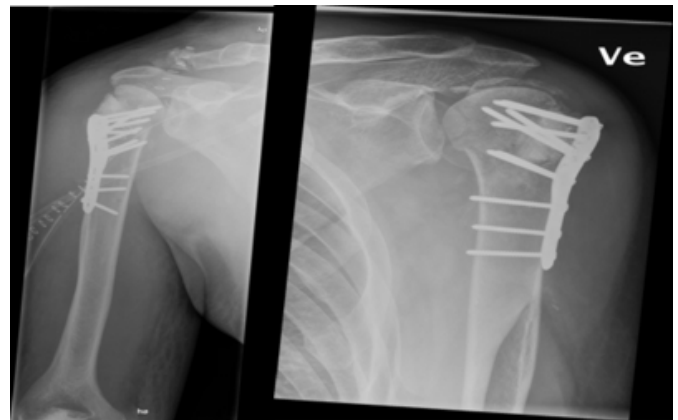


On a repeated examination, both lateral shoulder contours were flattened and had a lack of fullness anteriorly. The arms were internally rotated and adducted and could not be externally rotated or abducted from these positions due to pain. A repeated radiographical evaluation of the primary X-rays of the right shoulder showed an undisplaced subcapital fracture. At this time, it was concluded that the patient must have suffered a seizure due to alcohol withdrawal on the night of admittance.

Due to the patient's relatively young age, the fracture-dislocations were treated with open reduction and internal fixation with PHILOS (Synthes) interlocking plates using the deltopectoral approach (Figure 7 and 8). The fractures were very comminute and the surgeon was unable to obtain anatomical

**Figure 5**

Figure 7 and 8: Both fracture-dislocations after reduction and osteosynthesis. The greater tubercle is avulsed in both shoulders.



fracture reduction and fixation. Additional synthetic bone grafts in blocks and granulate (ProOsteon, Biomet) were applied on both sides. No rotator cuff tendons were ruptured. Biceps tenodesis was not performed. Both shoulders were immobilized in loose slings for 4 weeks and passive movements were begun as soon as pain permitted. After 2 weeks, the right shoulder was operated on again due to infection. This was combined with postoperative intravenous cephalosporin and later on penicillin after peptostreptococci from peroperative samples were identified, and the infection resolved. Active movements were begun at 6 weeks.

In the outpatient clinic at 9 and 38 weeks, there were no signs of osteonecrosis or instability. At 38 weeks, degrees of movement over the shoulder joints were (right/left) 70/60° abduction, 160/160° flexion, 45/45° extension, 90/90° internal rotation and 30/15° external rotation. The Constant Shoulder Score [5] was 51 in the right shoulder and 47 in the left one. At this time, normal activities of daily living had been resumed, however, the patient was not working. The patient was satisfied with the end result and experienced continued improvement of pain and motion.

## DISCUSSION

Posterior shoulder fracture-dislocation presents itself with relatively uncharacteristic findings and symptoms and a precise initial diagnosis may be missed [8, 10]. Our case shows that a complete radiographic evaluation and a strong suspicion are necessary for a correct diagnosis to be made if the objective findings do not correlate with seemingly normal initial radiographs. Shoulder pain after electrocution and epileptic seizure should raise the clinician's suspicion because of the involuntary violent internal rotation,

adduction and flexion that can occur [8]. Two junior doctors misdiagnosed the patient, which indicates that a missed diagnosis is more likely to occur in a hectic Emergency Room and if general orthopaedic experience or knowledge about this condition is lacking.

Radiographically, a fracture may, of course, be obvious. However, an undisplaced fracture may be missed, but the humeral head can be seen displaced laterally compared to the anterior rim of the glenoid cavity on an anteroposterior view. A displacement of more than 6 mm is called the “rim sign”. Due to internal rotation, the humeral head takes on a “light bulb appearance”. The convexity of the Moloney line may be broken. A Hill-Sachs lesion can be seen as a vertical line on the medial side of the head. A gap between this line and the medial cortex may look like a trough (“trough sign”) [2, 8, 12]. A lateral X-ray will show the humeral head lying posterior to the glenoid cavity. An axillary X-ray will reveal the dislocation clearly and, if pain permits, should be taken when a posterior shoulder fracture-dislocation is suspected [8]. A CT scan may provide further details in mapping the fracture pattern for operative planning [8]. MR imaging is not described as being necessary for mapping soft tissue damage because rotator cuff injury is extremely rare in posterior shoulder dislocations [11].

### **CONCLUSION**

A treatment guideline is difficult to establish due to the rarity of the fracture-dislocation and because the diagnosis may be delayed [3, 7]. Conservative treatment with closed reduction of a displaced non-comminute fracture in an immobilizer sling is feasible [8, 12]. Reduction is performed with traction in adduction. Further internal rotation and lateral traction may be necessary with pressure exerted on the posterior part of the humeral head in an anterior direction [9]. Posterior shoulder fracture-dislocations that cannot be reduced closed may be due to Hill-Sachs lesions, dislocated fractures that involve more than 20% of the articular surface or interpositioned soft tissue [12]. In these cases, open

reduction and internal fixation through a deltopectoral approach is relevant [8]. Our patient achieved Constant Shoulder Scores of 51/47 after osteosynthesis with interlocking plates. Stabilization with teno- or myodesis techniques of the posterior part of the shoulder joint may become relevant. The extremity should be bandaged in a sling for 2-4 weeks followed by a test of stability and gradual increase of active ROM exercises [9]. Major comminution of more than 50% of the humeral head or avascular necrosis due to an overlooked displaced fracture may warrant hemiarthroplasty [8].

### **References**

1. Agarwal M, Khan WS, Syed AA, et al. Bilateral posterior fracture-dislocation of the shoulder presenting as a dissecting aneurysm of the thoracic aorta: An uncommon presentation of a rare injury. *J Emerg Med*. 2007; 29:1-4.
2. Becker R, Weyand F. Die seltene, doppelseitige hintere Schulterluxation. *Unfallchirurg*. 1990; 93:66-68.
3. Blasler RB, Burkus JK. Management of Posterior Fracture-Dislocations of the Shoulder. *Clin Orthop Relat Res*. 1988; 232:197-204.
4. Brackstone M, Patterson SD, Kertesz A. Triple “E” syndrome: Bilateral locked posterior fracture dislocation of the shoulders. *Neurology*. 2001; 56(10):1403-4.
5. Constant CR, Murley AH. A clinical method of functional assessment of the shoulder. *Clin Orthop Rel Res*. 1987; 214:160-64.
6. Engel T, Lill H, Korner J, Josten C. Die beidseitige verhakete hintere Schulterluxationsfraktur. *Unfallchirurg*. 1999; 102:897-901.
7. Mancini GB, Lazzeri S. Bilateral Posterior Fracture-Dislocation of the Shoulder. *Orthopedics*. 2002; 25(4):433-4.
8. Martens C, Hessels G. Bilateral posterior four-part fracture-dislocation of the shoulder. *Acta Orthop Belg*. 1995; 61(3):249-254.
9. Mimura T, Mori K, Matsusue Y, et al. Closed reduction for traumatic posterior dislocation of the shoulder using the 'lever principle': two case reports and a review of the literature. *J Orthop Surg (Hong Kong)*. 2006; 14(3):336-9.
10. Page A, Meinhard BP, Schulz E, et al. Bilateral Posterior Fracture-Dislocation of the Shoulders: Management by Bilateral Shoulder Hemiarthroplasties. *J Orthop Trauma*. 1995; 9(6):526-529.
11. Steinmann SP. Posterior Shoulder Instability. *Arthroscopy*. 2003; 19(10):102-05.
12. Tellisi NK, Abusitta GR, Fernandes RJ. Bilateral posterior fracture dislocation of the shoulders following seizure. *Saudi Med J*. 2004; 25(11):1727-9.

**Author Information**

**Anton M. Trollegaard, M.D.**

Staff surgeon, Department of Orthopaedic Surgery Department of Orthopaedic Surgery, Glostrup University Hospital

**Marianne Nygaard, M.D., Ph.D**

Consultant, Department of Orthopaedic Surgery, Glostrup University Hospital

**Bjørn L. Madsen, M.D**

Consultant, Department of Orthopaedic Surgery, Glostrup University Hospital