

Bronchiolitis Obliterans Organizing Pneumonia in Cancer Patients

A Huaranga, M Haro, J Figueroa, J Ro

Citation

A Huaranga, M Haro, J Figueroa, J Ro. *Bronchiolitis Obliterans Organizing Pneumonia in Cancer Patients*. The Internet Journal of Pulmonary Medicine. 2004 Volume 4 Number 2.

Abstract

Design: A retrospective study.

Setting: Pulmonary Department of a university hospital.

Patients: Patients admitted to the pulmonary department who had pathological diagnosis of BOOP and concurrent cancer.

Interventions: Histopathological diagnosis review and data collection.

Measurements and Results: The medical records of 16 patients, with diagnosis of BOOP made by open lung biopsy specimen, were reviewed and the data collected included demographic information, underlying disease, clinical, radiological, and pathological manifestations, pulmonary function tests, arterial blood gases, methods of diagnosis, treatment and final outcome. We found that the mean age of our BOOP population was 47 years (range 15-77); the female/male ratio was 9/7 and except one all of them were Caucasian. The most common underlying neoplasia was Lymphoma. Five of them presented with symptoms such as dyspnea and cough, but 3 were asymptomatic. Five had crackles upon auscultation. The predominant physiological abnormality was a decline in diffusing lung capacity and hypoxemia. Four patients presented with patchy infiltrates, 2 with nodules, 1 with mass, and 1 with localized hyperinflation. From the 14 patients in whom some form of treatment was attempted, 2 responded favorably to corticosteroids, 1 did not and died, 2 improved temporarily but ultimately died, 1 improved with antibiotics, and in 2 improved spontaneously.

Conclusions: The clinical and radiological manifestations of BOOP in our cancer population did not differ from the ones presenting in the general population. The most common malignancies associated with BOOP were Lymphomas and Genito-urinary neoplasias. In 2/3 of the cases the relationship with malignancy was well established.

ABBREVIATIONS

BOOP = bronchiolitis obliterans organizing pneumonia

COP = cryptogenic organizing pneumonia

TBB = Transbronchial biopsy

OLB = open lung biopsy.

INTRODUCTION

Since Epler et al., described the syndrome in 1985; BOOP has been considered a distinct clinical-pathological entity of idiopathic origin. However, over the last few years, it has been associated with different conditions, such as infections, medications, immunological diseases, organ transplantation, etc. There have been scattered reports about the relationship of BOOP with neoplastic processes.

MATERIAL AND METHODS

Subjects: BOOP in an oncological population.

We conducted a review of the medical records of 16 patients seen in consultation in the Department of Pulmonary Medicine at The University of Texas M.D. Anderson Cancer Center from 1994 to 2000. All of these 16 patients had histopathologic specimens that confirmed the diagnosis of BOOP.

Study Objectives: To attempt to clarify the proteiform clinical presentation of bronchiolitis obliterans organizing pneumonia (BOOP) in our unique cancer population.

In this group we obtained the following data: Demographics,

underlying disease, clinical symptoms and signs, radiological, and pathological manifestations, pulmonary function tests, arterial blood gases, methods of diagnosis, treatment and final outcome.

Diagnostic Methods: As shown in Table 1, the diagnosis of BOOP was established in 13 patients by open lung biopsy (OLB) with an accuracy of 100% (Fig. 1), and one by autopsy. Four patients underwent transbronchial lung biopsy (TBB) and the biopsy yielded the diagnosis in two of them (an accuracy of 50%).

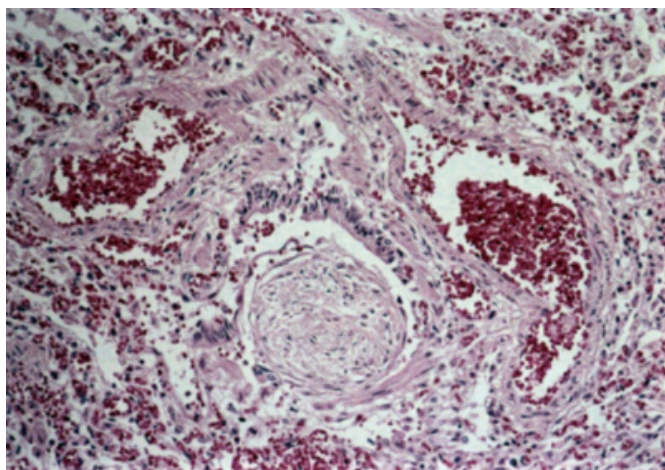
Figure 1

Table 1: Diagnostic Methods

Method	Performed	Diagnosis Obtained	Accuracy
O.L.Bx.	13	13	100%
T.B.Bx.	4	2	50%
Autopsy	1	1	100%

Figure 2

Figure 1: Open-lung biopsy of a patient with BOOP showing granulation tissue obliterating bronchiole surrounded by paren- chymal inflammation. (H and E; original magnification x 120)



RESULTS

Demographics: The Table 2 shows that the mean age of all patients was 47 years, ranging from 15 to 77. There was not significant difference between the number of male and female subjects. There were 7 male and 9 female patients. Out of the 16 patients; only one was an African-American patient, and the remaining were Caucasian.

Figure 3

Table 2: Demographics

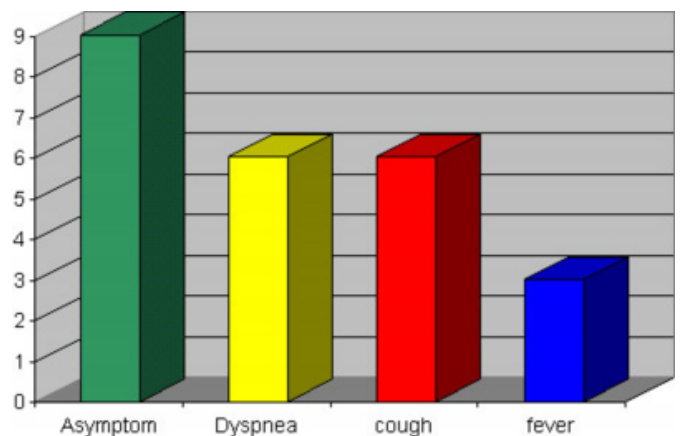
AGE.....	Mean: 47 (Range: 15-77)
SEX.....	7 male and 9 female.
RACE.....	15 caucasian/1 black.

Clinical Symptoms: As shown in Figure 2.

Nine patients (56.25%) were asymptomatic. Dyspnea and cough were present in 6 patients (37.5%), and fever was present in 3 patients (18.75%).

Figure 4

Figure 2: Symptoms of BOOP



Types of associated Neoplasia: As shown in Table 3.

BOOP turned out to be mainly associated with lymphoma and lung cancer.^{5, 6} In our study we found the presence of BOOP in 5 patients with lymphoma (31.25%), 4 patients had genito-urinary cancer (25%), and 2 patients had lung cancer (12.25%). In addition, we found one case with leukemia, one with brain cancer, other with thyroid cancer, and one with head and neck cancer.

Figure 5

Table 3 : Cancer patients with BOOP

Type of CA	No.
Lymphoma	5
Genito-Urinary CA	4
Lung CA	2
Leukemia, Brain Ca, Thyroid, Head & Neck Ca	1 each

Pulmonary Function Tests:

Diffusing lung capacity was reduced in 50% of the patients.

Hypoxemia, defined as $\text{PaO}_2 < 60$ mmHg or A-a gradient > 30 , was present in 43% of the patients.

Gallium scan was 100% sensitive.

Radiographic Patterns: As shown in Figure 3.

The chest roentgenogram showed patchy infiltrate in 6 patients (37.5%), nodular opacities were seen in 5 patients (31.25%), ground-glass density in 3 patients (18.75%), and both localized hyperinflation and reticulonodular opacities in one patient.

Figure 6

Figure 3: BOOP Radiographic Patterns

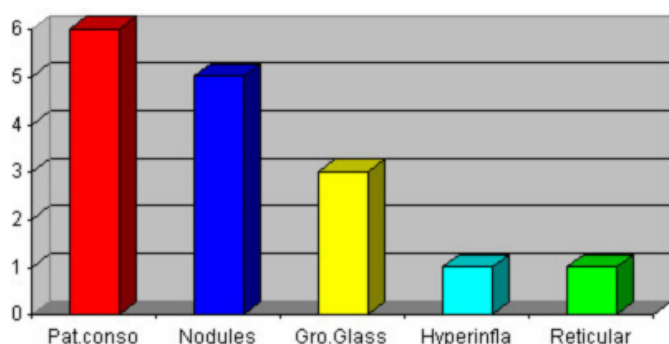


Figure 7

Figure 4: CT scan at the level of the lower lobes shows consolidation in the right lower lobe with air bronchograms and dilated distal air spaces.

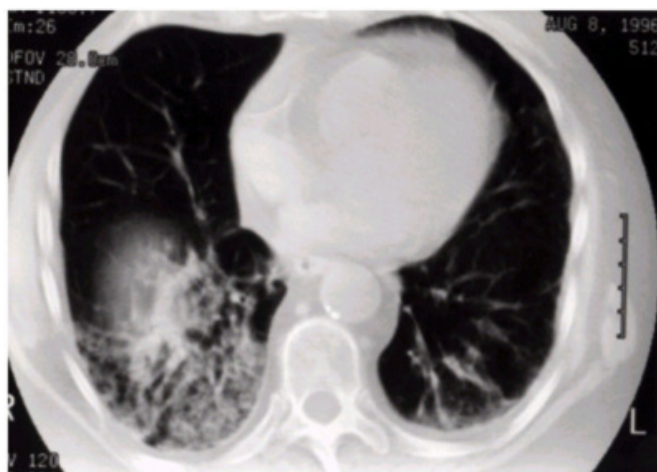
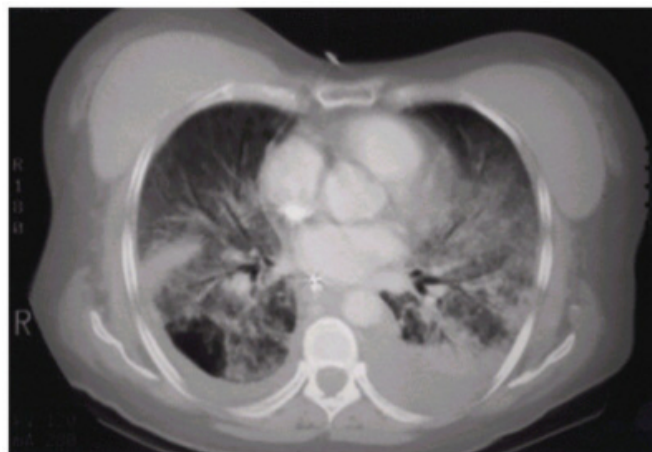

Figure 8

Figure 5: CT scan at the level of the lower lobes shows dense consolidation bilaterally and in the right lower lobe, an area of localized hyperinflation due to bronchiolar obstruction could be appreciated.



Therapy:

In our study group, 3 patients improved with the treatment with steroids; one of them alive and the others two died. There were other two patients that showed no response to steroids and died. Two patients improved with antibiotic treatment. Two patients were incidentally treated by surgery. There were five patients with no treatment, three of them alive and two died.

CONCLUSIONS

1. The clinical and radiological manifestations of BOOP in our cancer population did not differ from the ones presenting in the general population.
2. The most common malignancies associated with BOOP were Lymphomas and Genito-urinary neoplasias.
3. In 1/3 of the cases the relationship with malignancy was well established.
4. In another 1/3 of the cases, the relationship is very suggestive because of absence of other known predisposing factors,
5. In the remaining 1/3, the relationship between BOOP and chemotherapeutic drug administration or BMT was evident.
6. This study suggests that malignancy may need to be considered a predisposing factor for BOOP, or that BOOP is a non-specific inflammatory reaction

to the neoplastic tissue.

7. When approaching a patient with cancer in the lung with a synchronous lesion distant from the primary focus, we cannot assume it is neoplastic, we must obtain histological confirmation because it may be a BOOP-like reaction to the neoplasia, to any drug that the patient is getting, or to any concurrent infection..

References

1. Epler G., Colby T., McLoud T., Carrington C., Gaensler E. Bronchiolitis obliterans organizing pneumonia. *N Engl J Med* 1985; 312: 152-158.
2. Sole A., Cordero P.J., Martinez M.E., Vera F. Bronchiolitis obliterans organizing pneumonia. *Rev. Clinica Espanola* 1996; 196 (2): 99-102.
3. Nirenberg A., Meikle G.R., Goldstein D., Meikle R.G. Metastatic carcinoma infiltrating lung mimicking BOOP. *Australasian Radiology* 1995; 39 (4): 405-407.
4. D'Alessandro M.P., Kozakewich H.P., Cooke K.R., Taylor G.A. Radiologic-pathologic conference of Children's Hospital of Boston: New pulmonary nodules in a child undergoing treatment for a solid malignancy. *Pediatric Radiology* 1996; 26 (1): 19-21.
5. Romero S, Barroso E, Rodríguez-Paniagua M, Aranda FI. Organizing pneumonia adjacent to lung cancer: frequency and clinico-pathologic features. *Lung Cancer* 2002;35:195-201
6. Mokhtari M, Bach PB, Tietjen PA, Stover DE. Bronchiolitis obliterans organizing pneumonia in cancer: a case series. *Respir Med* 2002;96:280-6
7. Rodrigo Garzón M, Asensio Sánchez S, López Encuentra A. Carcinoma broncogénico y bronquiolitis obliterante con neumonía organizada. *Arch Bronconeumol* 1999;35:301-2.
8. Enomoto N, Ida M, Fujii M, Nogimura H, Suda T, Chida K, et al. Bronchioloalveolar carcinoma complicated by a lesion resembling bronchiolitis obliterans organizing pneumonia in the opposite lung. *Nihon Kokyuki Gakkai Zasshi* 2002;40/10: 827-831.

Author Information

Armando Huaranga, M.D.

Department of Pulmonary Medicine, The University of Texas M.D. Anderson Cancer Center

Manuel Haro, M.D.

Loma Linda University School of Medicine, White Memorial Medical Center

Juan Figueroa, M.D.

Department of Pulmonary Medicine, The University of Texas M.D. Anderson Cancer Center

Jae Ro, M.D.

Department of Pathology, The University of Texas M.D. Anderson Cancer Center