

Impacted Denture in the Oesophagus: Case report and review of Literature

P Adhikari, Y Neupane, B Shrestha, K Acharya, B Sinha, D Baskota

Citation

P Adhikari, Y Neupane, B Shrestha, K Acharya, B Sinha, D Baskota. *Impacted Denture in the Oesophagus: Case report and review of Literature*. The Internet Journal of Otorhinolaryngology. 2008 Volume 8 Number 2.

Abstract

Objective: To report a rare case of impacted foreign body (artificial denture) in the oesophagus and review the literature.

Case Report: This is a case report of impacted foreign body (artificial denture) in the oesophagus. The wire could be seen on x-ray soft tissue neck lateral view. But rigid oesophagoscopy could not remove the denture and the patient developed cervical emphysema in the first post operative period. Foreign body (artificial denture) was removed by Oesophagotomy and retrieval of denture and sternocleidomastoid muscle patching via external approach.

Conclusion: Foreign body ingestion is a common problem. Early removal of foreign bodies must be considered to reduce the risk of complications. Impacted denture in the oesophagus which was removed by oesophagotomy is an unusual presentation. To the best of our knowledge this is the first case report from Nepal.

INTRODUCTION

Foreign body ingestion is a common problem¹. Most common foreign bodies in pediatric age group are coins^{2,3} but meat bone, marbles, safety pins, button, batteries and screws are also reported. Adhikari et al study also showed coins and denture as a common foreign body in adults⁴. Foreign body ingestion is a common occurrence and carries significant morbidity and mortality. Sharp F.B. is frequently associated with serious complications⁴. If they are not removed at the earliest, they can cause erosion, perforation, abscess or mediastinitis³. Early removal of these F.B. must be considered to reduce the risk of complication⁴. We report a case of impacted foreign body (artificial denture) in the oesophagus. To the best of our knowledge this is the first case report from Nepal.

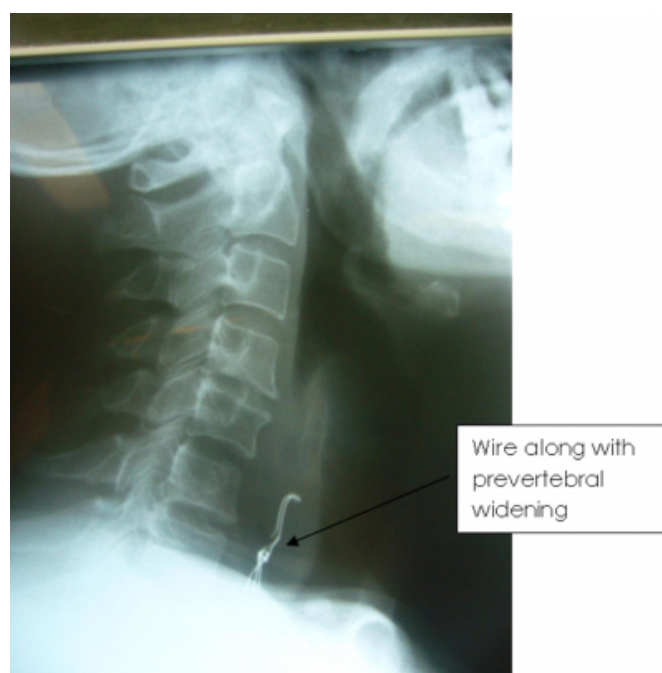CASE REPORT

A 60 years old male presented to ENT outpatient department of TU Teaching Hospital, Kathmandu with the history of gradually progressive dysphagia, odynophagia and pain in the neck after he accidentally ingested artificial denture. There was no history of fever, drooling of saliva, shortness of breath, seizures. On examination, the patient was ill looking. ENT and head and neck examination revealed tenderness over the neck. Indirect laryngoscopy showed pooling of saliva in pyriform sinus. Other examinations were

normal. On x-ray soft tissue neck lateral view there was widening of prevertebral space along with a radio opaque shadow of wire of denture at the level of 6th and 7th cervical vertebra.(Fig:1). Other routine investigations were normal.

Figure 1

Figure 1: X-ray STN lateral view- Wire of denture at C, C level



With the provisional diagnosis of foreign body (denture) oesophagus, patient underwent rigid oesophagoscopy under general anesthesia after 24 hours of antibiotics. Per operative finding was artificial denture impacted at 16 cm from upper incisor. The wire of the denture was impacted on lateral wall of oesophagus and denture could not be removed. The patient developed cervical emphysema on first post operative day and was managed conservatively. On the next day the patient underwent oesophagotomy and retrieval of the denture and sternocleidomastoid muscle patching via external approach. Peri operative finding showed a small rent in the cervical oesophagus anteriorly and impacted denture at lower the cervical oesophagus. (Fig: 2 and 3).

Figure 2

Figure 2: Showing oesophageal perforation after rigid oesophagoscopy

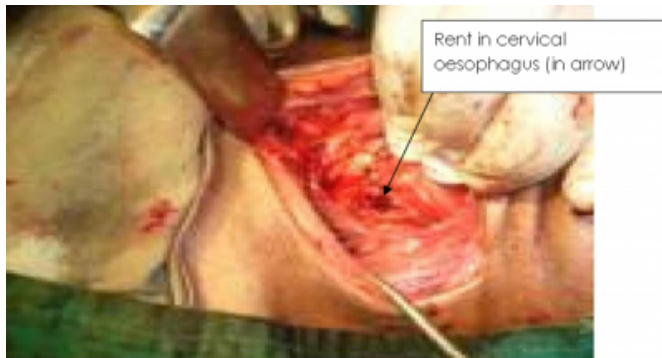
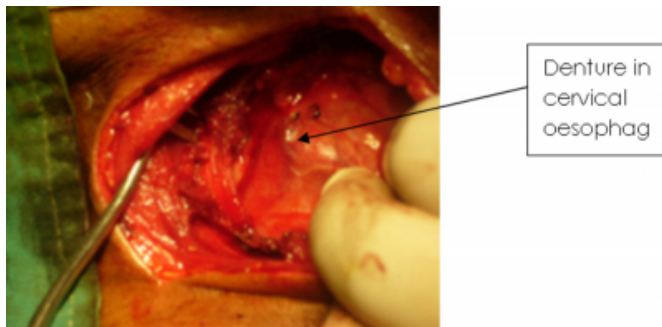


Figure 3

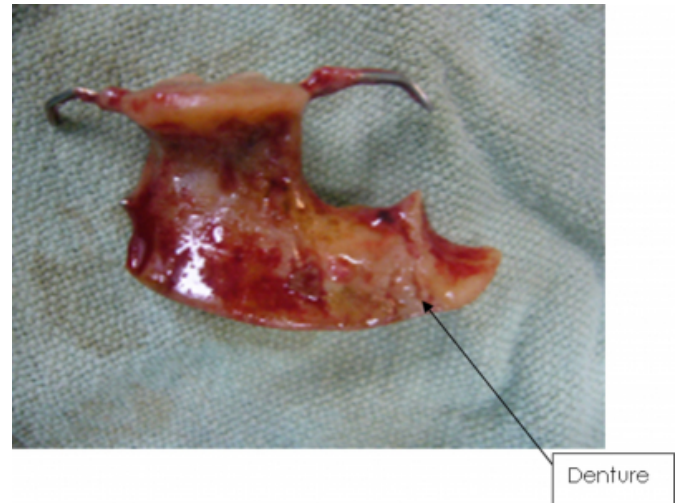Figure 3: Operative photograph showing a denture.



The left sternocleidomastoid muscle was mobilized to create a patch over the defect and interrupted suture were given to close it. A Removac drain and nasogastric tube was inserted. The incision was closed in layers and dressing applied. Fig. 4 showed the artificial denture after removal by oesophagotomy.

Figure 4

Figure 4: Artificial denture removed by Oesophagotomy



Post operatively intravenous antibiotics were continued for 10 days and nasogastric feeding am removac drain kept for 13 days. The suture was removed on 7th postoperative days. The patient was discharged on the 14th postoperative day without any problem.

DISCUSSION

Swallowing and aspiration of dental foreign objects is often reported in the literature⁵. Swallowing is more common than aspiration and usually seen in the elderly⁵. Careful examination is therefore essential in all cases of foreign body injury irrespective of the age and mode of presentation⁶. Too often the size and configuration of these objects compound their impaction and removal⁶. Ingestion usually occurs after trauma, intoxication, loss of consciousness or sleep, so there may not be a definite history of ingestion⁷. Psychiatric and mentally handicapped patients run a high risk of denture ingestion⁸. Following foreign body ingestion, patients usually present with dysphagia (92%) and tenderness of the neck (60%)⁹. Other symptoms include: inability to swallow oral secretions, throat pain, painful swallowing, hypersalivation, retrosternal fullness and regurgitation of undigested food. Indirect laryngoscopy will reveal pooling of saliva in pyriform sinus. Thus the diagnosis can be made by suggestive history of foreign body ingestion which is also in our patient.

Radiological imaging can determine the exact site of radio opaque foreign body. It is difficult to localize the site of impacted denture by imaging technique if there is no wire in it unless there is complications such as emphysema, mediastinitis, increased pre-vertebral shadow and loss of

cervical lordosis. Their radiolucence makes radiological localization almost impossible, and because of their rigidity, large size, irregular and unyielding edges, impacted dentures are apt to produce lacerations during endoscopic removal from gullets rendered friable by impaction¹⁰.

These foreign bodies' especially sharp objects perforate and cause complication. It includes retropharyngeal abscess, perforation to oesophagus, aorta, pericardium and gastrointestinal tract. Therefore the possibility of being damage of the vital structures along the path of migration should be borne in mind⁶.

Endoscopic extraction of dentures carries a high risk of perforation¹¹. Extraction of an impacted denture via oesophagotomy can be undertaken under direct vision and in an ideal situation with judicious use of the shear forceps¹¹. Small perforations of the cervical oesophagus in adult patients produced by foreign body impaction or rigid oesophagoscopy can be managed by observation, restricted oral intake and intravenous antibiotics¹². In our case, rigid oesophagoscopy was tried but the patient had cervical emphysema on first post operative day due to cervical oesophageal perforation.

Most of the impacted foreign body are located at cervical and upper oesophagus and can be removed by cervical oesophagotomy. Our patient also underwent oesophagotomy and retrieval of foreign body (denture). There are various methods of closing the oesophageal perforation but we close it using sternocleidomastoid muscle flap. Oesophagotomy has got the risk of oesophageal leakage and increases the chance of mortality. In the presence of positive history, prompt management is safe and effective to reduce the significant morbidity and mortality. The safest most effective method of removing impacted dentures in the oesophagus is through an open oesophagotomy.

CONCLUSION

Impacted denture in the oesophagus which was removed by oesophagotomy is an unusual presentation. To prevent

accidental ingestion, dentures should be made to fit properly and damaged or malfitting dentures should be discarded and replaced. Patients should be strongly advised against wearing them in bed.

CORRESPONDENCE TO

Dr. Prakash Adhikari, MBBS, M.S. Resident Department of Otorhino-Laryngology and Head and Neck Surgery, T.U. Teaching Hospital, Kathmandu, Nepal,
Tel: +977-1-4414191, Fax: +977-1-4414191. E-mail: prakash_ooz@hotmail.com

References

1. Shivakumar AM, Naik AS, Prashanth KB, Yogesh BS, Hongal GF. Foreign body in upper digestive tract. *Indian J Pediatr* 2004; 71:689-693.
2. Yang CY. The management of ingested foreign bodies in the upper digestive tract: a retrospective study of 49 cases. *Singapore Med J* 1991; 32: 312-5.
3. Guitron A, Adalid R, Huerta F, Macias M, Sanchez Navarrete M, Nares J. Extraction of foreign bodies in the esophagus: Experience in 215 cases. *Rev Gastroenterol Mex* 1996; 61:19-26.
4. Prakash Adhikari, Bikash L. Shrestha, D.K. Baskota, Bimal K. Sinha. Accidental foreign body ingestion: analysis of 163 cases. *Int Archives of Otorhinolaryngol* 2007; 11(3):267-0.
5. Brunello DL, Mandikos MN. A denture swallowed: Case report. *Aust Dent J* 1995; 40 (6):349-51.
6. Prakash Adhikari, R. B. Pradhananga, T. R. Limbu, D. K. Baskota, B. K. Sinha. Foreign body pyriform sinus: an unusual presentation. *Nepal Med Coll J* 2007; 9 (2):141-142.
7. A L Firth, J Moor, P W A Goodyear, D R Strachan. Dentures may be radiolucent. *Emerg Med J* 2003; 20:562-563.
8. De Ruiter MH, Van Damme PA, Drenth JP. Serious complications following removal of an ingested partial denture. *Ned Tijdschr Geneesk* 2007; 151(3):194-7.
9. Khan MA, Hameed A, Choudhry AJ. Management of foreign bodies in the esophagus. *J Coll Physicians Surg Pak* 2004; 14:218-20.
10. Nwafo DC, Anyanwu CH, Egbue MO. Impacted esophageal foreign bodies of dental origin. *Ann Otol Rhinol Laryngol* 1980; 89:129-31.
11. Nwaorgu OG, Onakoya PA, Sogebi OA, Kokong DD, Dosumu OO. Esophageal impacted dentures. *J Natl Med Assoc* 2004; 96(10):1350-3.
12. Morales-Angulo C, Rodríguez Iglesias J, Mazón Gutiérrez A, Rubio Suárez A, Rama J. Diagnosis and treatment of cervical esophageal perforation in adults. *Acta Otorrinolaringol Esp* 1999; 50(2):142-6.

Author Information

Prakash Adhikari, MS Resident

Department of ENT and Head and Neck Surgery, Ganesh Man Singh Memorial Academy of Head and Neck Studies, TU Teaching Hospital

Yogesh Neupane

Department of ENT and Head and Neck Surgery, Ganesh Man Singh Memorial Academy of Head and Neck Studies, TU Teaching Hospital

Bikash L. Shrestha

Department of ENT and Head and Neck Surgery, Ganesh Man Singh Memorial Academy of Head and Neck Studies, TU Teaching Hospital

Kunjan Acharya

Teaching Assistant, Department of ENT and Head and Neck Surgery, Ganesh Man Singh Memorial Academy of Head and Neck Studies, TU Teaching Hospital

Bimal K. Sinha

Professor and Unit Chief, Department of ENT and Head and Neck Surgery, Ganesh Man Singh Memorial Academy of Head and Neck Studies, TU Teaching Hospital

Dharma K. Baskota

Associate Professor, Department of ENT and Head and Neck Surgery, Ganesh Man Singh Memorial Academy of Head and Neck Studies, TU Teaching Hospital