

# Morpheic Basal Cell Carcinoma: Transformation Or Original Pathology?

A Widgerow, T Christofides

## Citation

A Widgerow, T Christofides. *Morpheic Basal Cell Carcinoma: Transformation Or Original Pathology?*. The Internet Journal of Plastic Surgery. 2005 Volume 2 Number 2.

## Abstract

Morpheic basal cell carcinomas (BCC) are considered aggressive and difficult to control. Can prior treatment of a regular BCC initiate its change to a morpheic pattern?

36 patients with diagnosed morpheic BCC were selected. Details of previous surgery and histologic diagnosis were recorded. Out of the 36 patients only 11 had morpheic BCC without previous treatment. Of the 21 who had had prior treatment, 9 had previous histological results available, of which only 1 had an original diagnosis of morpheic BCC.

The study prompts the following questions:

1. After treatment can a BCC transform into a more aggressive morpheic type?
2. Can a background of fibrosis such as that produced by freezing, curetting or that seen with chronic wounds initiate a change in the character of the basal cell to the morpheic form to allow its survival in the scar tissue?

Presented at the Annual Meeting of The Association of Plastic And Reconstructive Surgeons of Southern Africa, Sun City, South Africa, October 2001.

## INTRODUCTION

Morpheic or primary sclerosing basal cell carcinomas (BCC) appear as flat, firm, atrophic, rubbery tan or yellowish tumors characteristically present beneath the skin surface with actual margins usually wider than they appear clinically. They tend to spread laterally and superficially with little dermal penetration. Induration is almost always present with ulceration being very rare. Under the microscope, the neoplasm is seen as thin elongated cords of cells with sharp angulated ends. Traditionally they are considered more aggressive and difficult to control, with this consistent pattern of growth. This makes complete excision more difficult and consequently recurrences are more common (1,2).

Very little information is available in world literature relating to the specifics of this variation of BCC. Does the morpheiform pattern evolve from an initial non specific BCC, is it present abinitio, or do both forms exist? Can prior treatment of a regular BCC initiate its change to a morpheic pattern in some cases?

## MATERIALS AND METHODS

The aim of the study was to determine the percentage of patients diagnosed with morpheic BCCs who had prior treatment of these same lesions. Available histology of the originally treated BCCs was reviewed and the modality of treatment used for removal of the initial lesion was noted. More specifically, the aim of the study was to question if morpheiform changes may have taken place in certain BCCs following treatment, altering the original pathology.

Thirty six patients with diagnosed morpheic BCC were selected from the records of a private pathology group. Details were sought regarding previous surgery of the lesions, histologic diagnosis and method of treatment. Results were then be analysed as follows:

1. Age, sex, of patient and site of lesion
2. Percentage of morpheic BCCs with previous surgery at the site of the same lesion
3. Initial treatment/management of the lesion
4. Initial histologic diagnosis where available
5. Efficacy of treatment of morpheic BCC (%recurrent lesions)

RESULTS

This series showed an increased incidence of morpheic BCC with increasing age. (Table 1) This is in keeping with previous studies(3). Morpheic BCC,s were found to be twice as common in females with a strong predilection for the nose (Table 2.) This differs from reports relating to common basal cell carcinomas (4).

Figure 1

Table 1: Age Predilection

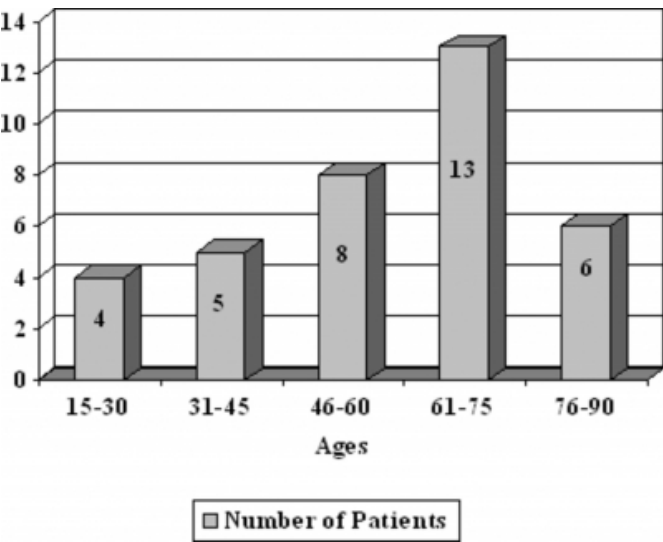
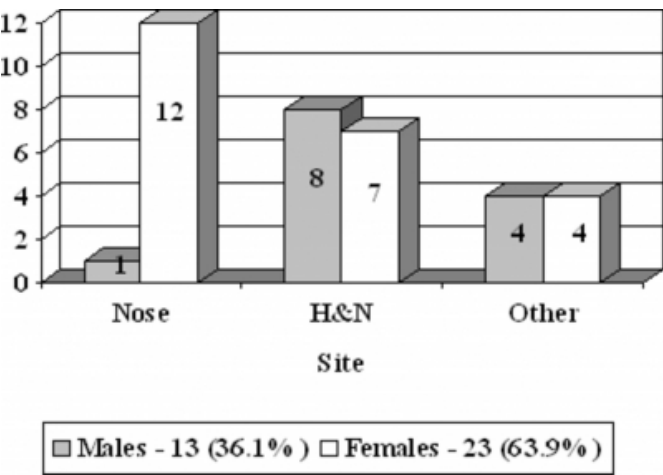


Figure 2

Table 2: Sex of patient and Site of lesion

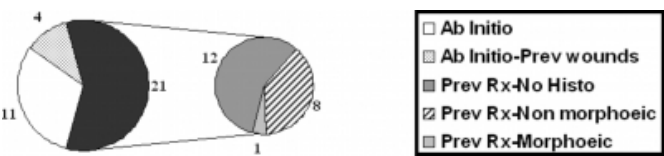


Out of the thirty-six patients, 15 (41.67%) patients were treated for the first time and the histology revealed a morpheic BCC (ab anitio) (Table 3) .The remaining 21 (58.33%) were all pretreated with some form of treatment modality be it cryotherapy, curettage or previous excision. Looking more closely at the 15 patients that were treated for the first time, we found that 4 of these patients had chronic

irritation (burns, ulcers, non-healing mastectomy incision) to the site from longstanding wounds. Thus, only 11 of the 36 patients had been treated for a lesion diagnosed as morpheic BCC without previous irritation or scarring to the site of the lesion (Table 3).

Figure 3

Table 3: Past History of Isolated Morpheic BCC's



Of the 21 patients that received previous treatment to the lesion, 9 had previous histological results while the remaining 12 patients did not have previous histological results available (Table 3) as the previous treatment involved cryotherapy or curettage where specimens were not submitted for histology.

Of those 9 patients with previous histological results, only 1 had an original diagnosis of morpheic BCC. The remaining 8 lesions had different histological diagnoses at the time of the original treatment.

The previous histological results included 2 nodular BCC's, 2 BCC's with background fibrosis but no obvious morpheic cell types and 4 infiltrating BCC's.

Thus, 22% of the patients did not start off as having definite morpheic BCC's. This begs the question that after multiple treatments did the BCC transform into the more aggressive morpheic type of BCC, or was the original histology incorrect, or was a more representative section of the block necessary? Review of the 8 histological diagnoses confirmed the original findings, but multiple sections of the original blocks were not available at this stage, only the slides originally reported on.

Another 33% of lesions were unaccounted for, as their histology results were not available although they were treated previously.

DISCUSSION

The morpheic BCC has a histologic picture of thin, elongated cords of cells with angulated ends in a background of dense fibrosis. The infiltrating component has a much more strand-like or trabecular appearance as compared to the solid nesting found in the other subtypes of BCC's (1,2,3,4).

Our aims of this study were to pose the following questions:

1. Can morpheic BCC evolve from another type of BCC, or is it present ab initio?
2. Can prior scarring (for example from long standing wounds, prior burns or Iatrogenic excision, curettage, cryotherapy), initiate the change to this type of BCC? The results of the study presents the possibility that certain morpheic BCC's may have evolved. from commoner types of BCC's following treatment or any scar-producing process. This would suggest that morpheic BCC may be a secondary phenomenon in certain cases, following treatment or trauma, rather than arising as original pathology.

Recurrent BCC's, categorized from the history or because of histologically identified surgical scarring, were even more likely to be flat and to show a microscopic infiltrative growth pattern (5). One may also question whether inadequate treatment could initiate the change in growth causing an altered stroma (scarring) with aggressive transformation and induction of a morpheaform type of BCC (5,6)? Although it is possible that the initial histology in some of these cases presented features similar to morpheaform features (fibrous infiltration) or may have been present in more sections, it is also possible that certain treatments or irritations, may have transformed the histological picture to one of 'full blown' morpheic BCC. Thus, certain important points regarding the current management of basal cell carcinomas warrant discussion:

1. The first treatment of the BCC should be as effective as possible
2. Cryotherapy has the disadvantage of never having the definitive histology and inducing more scarring and fibrosis with the possible ramifications.

3. Curettage, while recognized as a treatment modality, should be performed with reasonable margins and the specimen must be submitted for histological evaluation.

This study may implicate those forms of treatment inducing marked fibrosis. At the very least, we would hope this paper initiates questions and discussion concerning the 'morpheic' phenomenon.

### **CORRESPONDENCE TO**

Prof A D Widgerow P O Box 669 Gallo Manor 2052 South Africa Tel: 2711 485 2080 Fax: 2711 485 3579 E-mail: surgeon@iafrica.com

### **References**

1. Sexton, A. Jones, B. Maloney M. Histologic pattern analysis of basal cell carcinoma. Study of a series of 1039 consecutive neoplasms. J Am Acad Dermatol 1990; 23: 1118 - 1124.
2. Horlock, N. Wilson, G. Daley, F. Richman, P. Sanders, R. Cellular proliferation characteristics of basal cell carcinoma relationship to clinical subtype and histopathology. Eur J Surg Oncol 1997; 23: 247-252.
3. McCormack, C. Kelly, J. Dorevitch, A. Differences in age and body site distribution of the histological subtypes of basal cell carcinoma. A possible indicator of differing causes. Arch Dermatol 1997;133: 593-596.
4. Puizina, I. Matovic, B. Gluncic, I. Maslovara, S. Vela-Ljubic, J. Histopathologic variants of basal cell carcinoma correlation with sex, age and localization. J Med Syst 1999;23: 389-394.
5. Rippey, J. Rippey, E. Characteristics of incompletely excised basal cell carcinomas of the skin. Med J Aust 1997;166: 581-586.
6. Miller, S. Biology of basal cell carcinoma (Part II). J Am Acad Dermatol 1991;24: 161-168.
7. Dixon, Y. Lee, S. McGregor, D. Histologic evolution of basal cell carcinoma recurrence. Am J Dermatopath 1991;13: 241-245.
8. Lang, P. Maize, J. Histologic evolution of recurrent basal cell carcinoma and treatment implications. J Am Acad Dermatol 1986;14: 186-190.

**Author Information**

**Alan D. Widgerow, MBBCh; MMed; FCS (Wits, Plast); FACS**

Honorary Professor, Department of Plastic Surgery, University of the Witwatersrand

**Tim Christofides, MBBCh; FC (Plast Surg)**

Consultant, Department of Plastic Surgery, University of the Witwatersrand