

Hepatic Portal Venous Gas: An Ominous Sign Of Abdominal Catastrophe In A Blunt Abdominal Trauma Scenario. A Case Report

D BV, B P., S P., S BP., S B.

Citation

D BV, B P., S P., S BP., S B.. *Hepatic Portal Venous Gas: An Ominous Sign Of Abdominal Catastrophe In A Blunt Abdominal Trauma Scenario. A Case Report.* The Internet Journal of Surgery. 2009 Volume 25 Number 1.

Abstract

Hepatic portal venous gas (HPVG) is a well described entity demonstrated in CT scan and ultrasonography of the abdomen. As this sign has been described in a variety of conditions, its clinical significance is open for debate. Miscomprehension of underlying pathologic conditions has led to some confusion in the literature concerning its etiology, diagnostic methods and clinical consequences. HPVG is not a specific disease entity but merely another diagnostic clue in patients suffering from acute abdominal pathology. Approach to the patient with HPVG should be directed by underlying disease. HPVG is more common than realized. The transient nature of HPVG is well established in the review of literature. Here we present one such case with a diagnostic dilemma for the cause of gas in the portal venous system within 8 hours of sustaining abdominal trauma, on ultrasonography and confirmed by CT scan.

INTRODUCTION

HPVG is a life-threatening sign since it is associated with an overall mortality ranging from 75% to more than 90%. However, a recent study has reported a mortality rate as low as 29 %. (2) The decline in the mortality is not due to improved management of the cases but rather due to an increasing number of clinically unimportant causes of portal venous gas, owing particularly to the development and improvement of CT and ultrasound equipment.

HPVG has been reported in so many other causes other than necrotic bowel such as ulcerative colitis, intra-abdominal abscess, bowel obstruction without necrosis, gastric ulcer, acute hemorrhagic pancreatitis, diabetic ketoacidosis and certain cases where the cause is unknown. But in this list, the most common cause is necrotic bowel. (1) Just a presence of HPVG in CT or USG is not an indication for exploratory laparotomy if there are no signs of an intra-abdominal catastrophe or systemic toxicity. (4)

CASE SUMMARY

A 55-year-old male was brought to our hospital 8 hours following a road traffic accident (RTA). Initially he was treated and stabilized in a local hospital. On examination the patient was unconscious, not responding to oral commands, his pulse rate was 96/min, his BP 132/90 mmHg; facial

abrasion and subconjunctival hemorrhage were present. He had dislocation of right shoulder and right elbow, left frontonasal bone fracture, and right pneumothorax with right lower rib fracture.

On examination, the abdomen was soft, no distention, but tenderness in the left lumbar and left iliac fossa was present. There was no guarding or rigidity, bowel sounds were sluggish, and per rectal examination was normal.

- USG of the abdomen revealed a hemoperitoneum and was suggestive of air within the portal tract.
- CT of the abdomen (figures 1&2) revealed air in the main portal vein and its branches in both lobes of the liver, with a segment V liver laceration, pneumatosis intestinalis, few air pockets within the mesenteric vessels, and multiple splenic lacerations.

Figure 1

Figure 1: CT scan showing HPVG

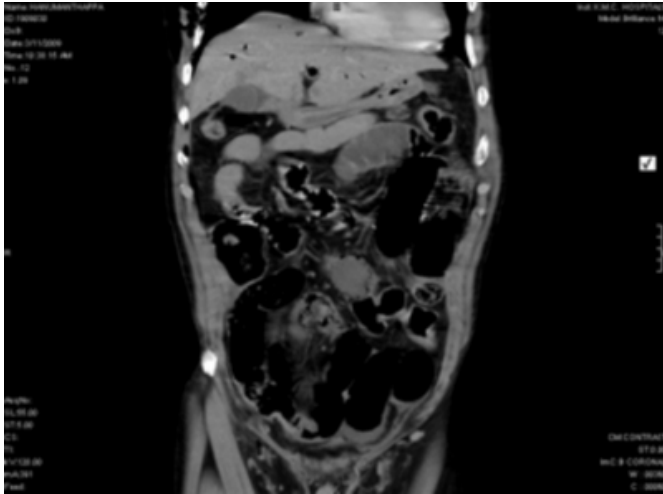
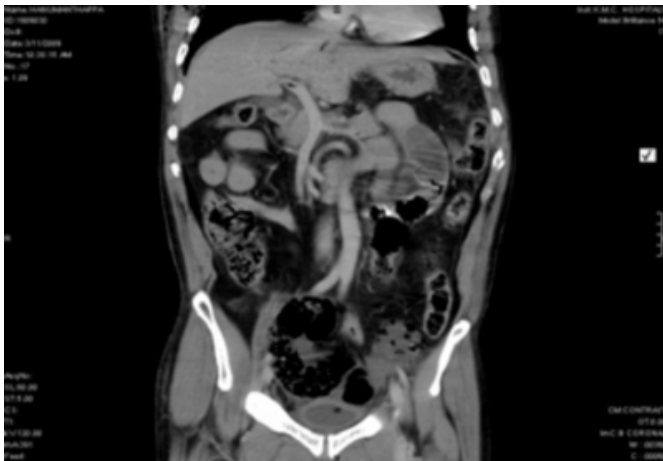


Figure 2

Figure 2: CT scan showing portal venous gas

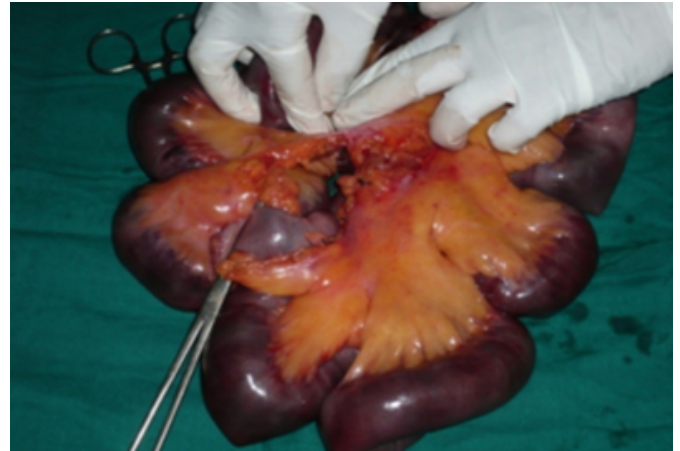

On exploration, there was a haemoperitoneum of about 500ml. The bowel was gangrenous from mid jejunum to the ileocecal junction (figure 2), and there was a splenic laceration, a liver laceration (5cm, with a depth of 2-3cm), and a gangrenous patch over the anterior wall of the stomach at the pyloric region measuring 3x4cm.

The gangrenous bowel was resected and an anastomosis between jejunum and ascending colon was carried out. A splenectomy was done, the gangrenous patch over the stomach wall was excised and the edges were sutured. The liver laceration was stapled and packed with Abgel™.

Figure 3

Figure 3: Small bowel gangrene



Post-operatively, the patient developed renal failure and was detected to have brain stem injury. As the poor prognosis was explained to the relatives of the patient, he was discharged against medical advice.

DISCUSSION

The approach to a patient with HPVG should be directed to the underlying disease. Portal gas composition has been analyzed and found to have high CO₂ content. (3) Different mechanisms for development of HPVG have been explained which are (3, 11, 12, 13)

- Gas under pressure in the bowel lumen,
- Alteration leading to disruption of the bowel mucosa,
- Gas-forming bacteria in intra-abdominal sepsis.

Causes such as endoscopic procedures (1, 2, 14, 15), paralytic ileus (1, 2, 15), mechanical obstruction, acute gastric dilatation (1, 2, 16), blunt trauma and barotrauma produce HPVG (1, 2, 17) by bowel distention and gas under pressure in the bowel lumen.

Inflammatory bowel disease (1, 2, 3), mesenteric ischemia (1, 2, 3) and necrotizing enterocolitis (1, 2, 3) produce HPVG by mucosal damage.

Intra-abdominal or retroperitoneal abscess, diverticulitis, acute necrotizing pancreatitis, abdominal wall gangrene and necrotizing enterocolitis produce HPVG by gas-forming bacteria. (1, 2)

HPVG can occur alone or in association with pneumatosis

intestinalis (PI). When associated with PI, origin seems to be intestinal ischemia. There are case reports showing gas in inferior and superior vena cava, superior and inferior mesenteric, hemorrhoidal, internal ileac and left colic veins. (1) Transient cases of HPVG without clinical consequence have been observed in numerous cases like in inflammatory bowel disease, acute gastric dilatation or jejunostomy catheter insertion.

Abdominal radiographs can detect large quantities of HPVG, but its accuracy is far inferior compared to ultrasonography and CT scan. (4, 7, 11) Demonstration of HPVG should prompt a search for associated abnormalities such as ischemia of the bowel wall, occlusion of mesenteric vessels and pneumatosis intestinalis. HPVG has been reported to occur in less than 1% of patients with blunt abdominal trauma. (2) In these patients HPVG does not necessarily imply bowel perforation or necrosis. Insignificant HPVG in setting of blunt abdominal trauma is believed to result from acute pressure changes that occur at the time of injury and force intraluminal gas into the bowel wall, where it is absorbed into the portal circulation. (1, 11)

Gas in the portal venous system is carried by the centrifugal flow of blood in the periphery of the liver, appearing to extend within 2cm of the hepatic capsule. Inversely, gas in the biliary tract moves with the centripetal flow of bile, thus appearing more central in the liver. Ultrasonography gives additional real-time information allowing the observation of hepatofugal or hepatopetal gas displacement. (5, 8, 9) History of bilodigestive anastomosis, endoscopic papillotomy or biliary endoprosthesis is certainly of importance in the differential diagnosis. (2, 6)

CT scan provides the conclusive diagnosis in most cases. Furthermore, associated necrotic bowel signs are more specific on CT scan than on ultrasonography. (10)

CONCLUSION

HPVG is reported in a wide range of conditions. Among the list, the most important and most common cause of HPVG is bowel gangrene. HPVG and PI are radiological clues and not the diagnosis. Presence of both HPVG and PI strongly suggests bowel gangrene. Management of cases having only HPVG should be individualized as this is observed in a wide variety of conditions. The case we are presenting was having both HPVG and PI on USG and CT scan following blunt abdominal trauma as early as 8 hours. On abdominal examination there were no local signs suggestive of

peritonitis, but on exploration he was found to have massive gangrene of the bowel and other organ injuries. It takes few hours to develop signs of peritonitis in case of bowel gangrene. As HPVG and PI can be picked up on USG and CT scan before the development of signs of peritonitis, this sign should be considered as an ominous early sign of bowel gangrene. To conclude, HPVG and PI are strong indicators of bowel gangrene, especially in the setting of blunt abdominal trauma, and should warrant emergency exploratory laparotomy even in the absence of clinical signs of peritonitis.

References

1. Peloponissios N, Halkic N, Pugnale M, Jornod P, Nordback P, Meyer A, Gillet M: Hepatic portal gas in adults. *Arch Surg*; 2003; 138: 1367-1370.
2. Brown MA, Hauschidt JP, Casola G, Gosink BB, Hoyt DB: Intravascular gas as an incidental finding at US after blunt abdominal trauma. *Radiology*; 1999; 210: 405-408.
3. Liebman PR, Patten MT, Manny J, Benfield JR, Hechtman HB: Hepatic portal venous gas in adults: etiology, pathophysiology, and clinical significance. *Ann Surg*; 1978; 187: 282-287.
4. Iannitti DA, Gregg SC, Mayo-Smith WW, Tomolonis RJ, Cioffi WG, Pricolo VE. Portal venous gas detected by computed tomography: is surgery imperative? *Dig Surg*; 2003; 20(4): 306-15.
5. Bodewes HW, Puylaert JB: Ultrasound in detection of portal venous gas in adults. *Gastrointest Radiol* 1991; 16: 35-37.
6. Gosink BB: Intrahepatic gas differential diagnosis. *AJR Am J Roentgenol*; 1981; 137: 763-767.
7. Chezmar JL, Nelson RC, Bernadino ME: Portal venous gas after hepatic transplantation: sonographic detection and clinical significance. *AJR Am J Roentgenol*; 1989; 153: 1203-1205.
8. Radi DR, Rosen SR, Halls JM: Acute gastric dilatation: a rare case of portal venous gas. *AJR Am J Roentgenol*; 1987; 148: 279-280.
9. Nachtegaele P, Afschrift M, Vandendriessche M, Van Rattinhe R, Voet D, Verdonk G: Sonographic diagnosis of gas embolism in portal vein. *Gastrointest Radiol*; 1982; 7: 375-377.
10. Pear BL: Pneumatosis intestinalis; a review. *Radiology*; 1998; 207: 13-19.
11. Cambria RP, Margolies MN: Hepatic portal venous gas in diverticulitis: survival in steroid treated patients. *Arch Surg*; 1982; 118: 1339-1344.
12. Graham GA, Bernstein RB, Gronner AT: Gas in the portal and inferior mesenteric vein caused by diverticulitis of sigmoid colon: report of a case with survival. *Radiology*; 1975; 114: 601-602.
13. Quirk TE: Hepatic portovenous gas associated with ileus. *Am Surg*; 1995; 61: 1084-1086.
14. Moss ML, Mazzeo JT: Pneumoperitoneum and portal venous air after barium enema. *Va Med Q*; 1991; 118: 233-235
15. Huyck A, Moller DD: Hepatic portal venous gas after colonoscopy in granulomatous colitis. *Am J Gastroenterol*; 1985; 80: 637-638.
16. Benson MD: Adult survival in intrahepatic portal venous gas secondary to acute gastric dilation with a review of

Hepatic Portal Venous Gas: An Ominous Sign Of Abdominal Catastrophe In A Blunt Abdominal Trauma Scenario. A Case Report

portal venous gas. Clin Radiol; 1985; 36: 441-443.
17. Vauthey J, Mathews C: Hepatic portal venous gas

identified by computed tomography in a patient with blunt abdominal trauma: a case report. J Trauma; 1992; 32: 120.

Author Information

Dinesh BV, . MS

Department of Surgery, Kasturba Medical College

Basavaraj Biradar P., MS

Department of Surgery, Kasturba Medical College

Sampath Kumar P., MS

Department of Surgery, Kasturba Medical College

Suresh BP., MS

Department of Surgery, Kasturba Medical College

Sibasis B., MS

Department of Surgery, Kasturba Medical College