

Bilateral pulmonary hydatidosis after traumatic rupture of lung hydatid cyst in a child: report of a case

M Ghaemi, E Soltani

Citation

M Ghaemi, E Soltani. *Bilateral pulmonary hydatidosis after traumatic rupture of lung hydatid cyst in a child: report of a case*. The Internet Journal of Surgery. 2008 Volume 20 Number 2.

Abstract

Cystic echinococcosis is a ubiquitous infectious disease in which the human is its accidental intermediate host. Although the liver is the most common site of the cysts, in children the main site is the lung. Widespread pulmonary hydatidosis is a rare condition and we report an 8-year-old boy with a traumatically ruptured lung hydatid cyst which has lead to widespread pulmonary echinococcosis. Medical treatment with albendazole was successfully used and so recommended to control his non-operable situation.

INTRODUCTION

The vast majority of hydatid disease in human beings is caused by *echinococcus granulosus* which causes cystic echinococcosis (1). The cyst widely spreads in Asia, South America, Middle and Southern Europe (2-9).

While the human is the accidental intermediate host in its life cycle, dogs (wolves or foxes) are the definitive hosts and sheep (cattle or camels) the intermediate host (4-12). Ingestion ova-containing water or vegetables infects humans (4-11). These ingested ova which have turned to a larval form penetrate the intestinal wall. Then, through mesenteric veins, they reach the liver (13), the main site of development for hydatid cysts, although few of them can bypass this organ, which, after all, will be trapped in the lungs (14). They change to vacuolates (encystation) to form the hydatid cyst 6-10 days after ingestion, sometimes with daughter cysts inside or outside the primary cyst (15). The most common organ affected by hydatid disease is liver (55-70%) followed by lungs (20-35%), where systemic spreading may happen (5, 10, 11, 14). In children and young adults, the lung is the most frequent site of involvement (16, 17).

Hydatid cysts are characteristically slow-growing (approximately 1cm in the first 6 months and 2-3cm annually thereafter (5)), benign and well tolerated; therefore, they are often asymptomatic for several years after infection (10, 18). The cyst's symptoms depend on the site and size of them, whereas in some instants the first presentation is the consequence of a complication, such as rupture, pressure

effect, obstruction, allergic responses to cystic fluid, or secondary bacterial infection (1, 14, 19).

Diagnosis of hydatid cysts may be made by serological tests, plain radiographs, ultrasonically or by CT scans (14, 15, 20). The traditional treatment for hydatid cyst in every organ is surgery.

CASE REPORT

An 8-year-old boy was admitted to our hospital with clinical features of dyspnea, coughing and low-grade fever following a blunt chest trauma by a ball during his exercise. On his chest x-ray (Fig. 1) and computerized tomography scan (Fig. 2), a large spherical lung cavity with a collapsed germinative layer was discovered in the right lung. According to the radiologic findings and high prevalence of hydatid disease in our country, operation was planed for the patient, presuming the diagnosis of a ruptured pulmonary hydatid cyst. In the preoperative evaluation, the Casoni and indirect haemagglutination tests were negative and also the liver and other abdominal organs were clear of infestation on ultrasonography.

At exploration via an intercostal incision, the outer wall of the ruptured cyst was excised and the contents were sucked out. There was no spillage around the area. Any site of gas leakage in the open cavity was thoroughly sutured and the cavity was capitonnaged. After five days the chest tube was removed and the patient, who had a good general condition now, was discharged from hospital. Albendazole which has been stared postoperatively was stopped by him after he left

the hospital.

After two months, the patient was admitted for the second time due to his progressive 10 day-long dyspnea. His chest x-ray showed multiple pulmonary nodules (Fig. 3). Pulmonary hydatidosis, some collagen vascular disorders and lung metastasis were among the differential diagnoses. Metastasis is a farfetched condition in this patient and collagen vascular disorders were ruled out by laboratory tests and rheumatologic consultation. Based on his past history and the fact that he stopped his medication by himself, a widespread pulmonary echinococcosis would be the prominent diagnosis. Due to the non-operable situation, the medical treatment continued, using a long-term albendazole therapy. After 6 months of medical therapy, his respiratory condition improved, the treatment was continued for a next period of 6 months and the patient underwent close observation. At the end of these 2 therapeutic periods, all the respiratory symptoms were resolved completely with a normal chest x-ray. For prevention of hepatic complications, albendazole was administered 15 mg/kg/day in divided doses twice daily with meal for a 28-day cycle followed by 14-day albendazole-free interval.

Figure 1

Figure 1. Chest X-ray taken on first admission showing a large cavity with a germinative layer in the right lung

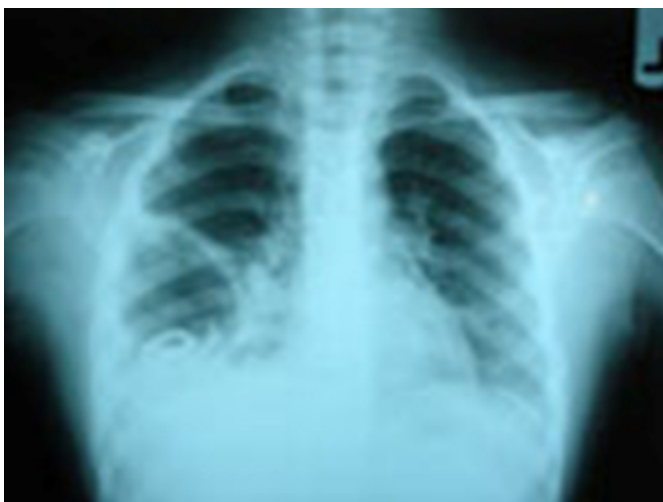

Figure 2

Figure 2. Computed tomography scan of the chest confirming X-ray findings

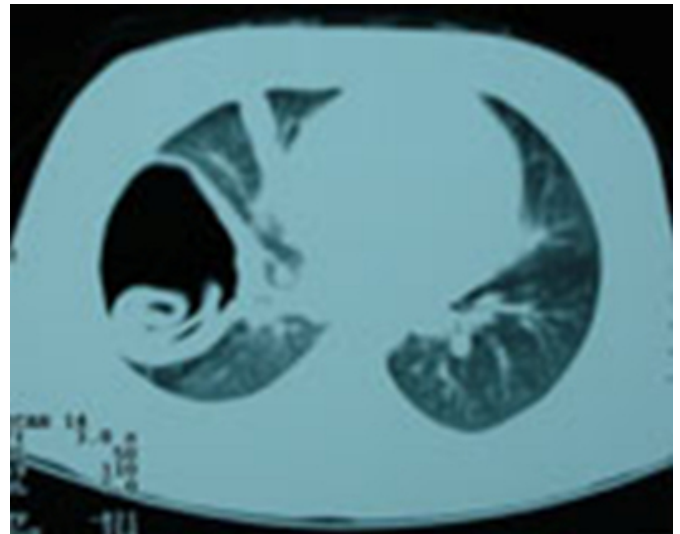
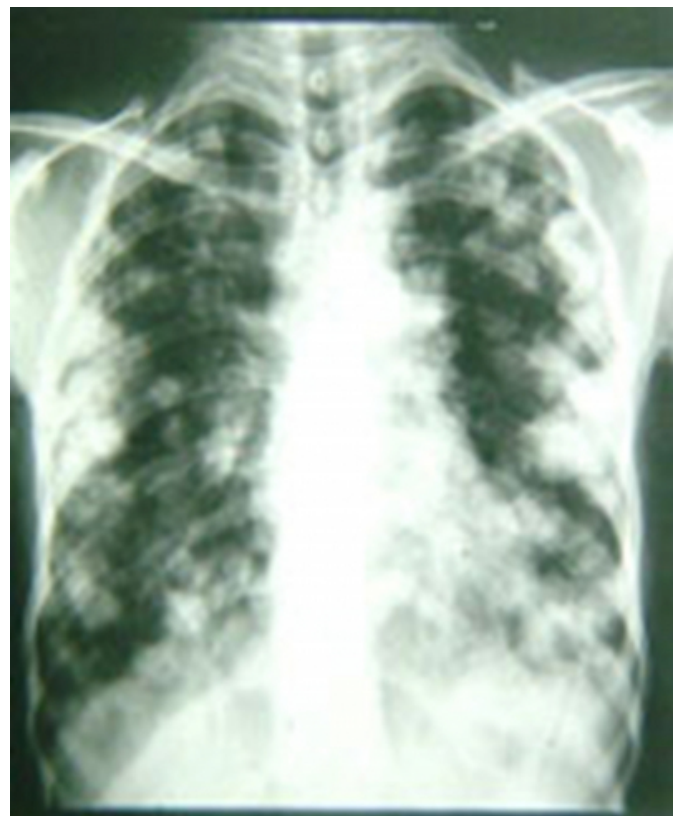

Figure 3

Figure 3. Chest X-ray taken on second admission showing bilateral multiple pulmonary nodules



DISCUSSION

Hydatid disease is one of the most important helminthic diseases. Echinococcosis has a worldwide distribution; it occurs most commonly in sheep and cattle-raising areas (1,

21). The lung is the second most common involved organ, but in children it is the commonest site. This high incidence in children is probably because of incidental hydatid identification on radiographs which occurs when children are investigated for other respiratory infection causes (22). The lung may be affected when the liver is bypassed via the lymphatic system (11). At the time of diagnosis almost 60% of pulmonary hydatid cysts (45% in children) are complicated (2, 22). These symptomatic cysts in lungs may usually be ruptured or secondarily infected (6) and so can produce chest pain, coughing, haemoptysis and allergic reaction. Most infections are acquired in childhood and remain silent for years before the cysts become symptomatic (14). The lung in children is more elastic and therefore more compressible (22); cysts may enlarge more rapidly and cause earlier symptoms resulting in sooner detection. However, hydatidosis frequently remains asymptomatic and hydatid cysts in children are often found by chance on physical examination or by imaging studies done for other reasons.

For confirming the diagnosis of hydatid disease, serologic tests can be very helpful but as some cyst carriers do not have detectable antibodies, negative test results do not rule out echinococcosis (14). Especially in children, as in our case, serological tests can be falsely negative as they may have a poor serological response to echinococcus granulosus (15). Liver cysts are also more likely to elicit antibody responses than those cysts in the lungs (14).

A conventional radiograph (chest x-ray) has an important role in pulmonary hydatidosis. Specially if the cyst ruptures, the air around or within the endocyst, an air-fluid level and the collapsed, crumpled membranes floating in the fluid result in a variety of plain film descriptive terms, namely: the 'meniscus/crescent' sign, the 'water lily' sign, the sign of the 'rising sun', the 'serpent' sign, the 'whirl' sign, the 'onion peel' sign and the 'cumbo' sign (5, 6, 11, 22). CT scan would be useful to confirm the diagnosis and it is also able to demonstrate cysts not identified with plain radiographs (22).

The treatment of hydatid disease is principally surgical (14). The aim of surgery is a removal of all the cysts. The cysts contain numerous scolices, each of which is capable of producing a small tapeworm. Cyst rupture may release a large number of viable scolices that implant elsewhere and produce secondary cysts (20). So killing the ova, by injection of hypertonic saline or aqueous iodine into the cyst, is indicated (14). However, preoperative and postoperative courses of albendazole, or any combination of medications,

should be considered in order to sterilize the cyst, decrease the chance of anaphylaxis, tension in the cyst wall (thus reducing the risk of spillage during surgery) and the recurrence rate postoperatively (14). Especially this complimentary medication is very important in the ruptured cysts where cyst fluid spillage is unavoidable.

We conclude that, in the ruptured hydatid cyst, pre- and long-term postoperative medication with albendazole for killing the spilled scolices is very important.

ACKNOWLEDGMENT

Special thanks are extended to Dr. E. Saremi and Ms. M. Hassanpour for editing the manuscript.

References

1. Kurt Y, Sücüllü I, Filiz AI, Urhan M, Akin ML. Pulmonary echinococcosis mimicking multiple lung metastasis of breast cancer: the role of fluoro-deoxy-glucose positron emission tomography. *World J Surg Oncol* 2008;6:7
2. Kervancioglu R, Bayram M, Elbeyli L. CT findings in pulmonary hydatid disease. *Acta Radiol* 1999;40:510-4
3. Turgut M, Benli K, Eryilmaz M. Secondary multiple intracranial hydatid cysts caused by intracerebral embolism of cardiac echinococcosis: an exceptional case of hydatidosis. Case report. *J Neurosurg* 1997;86:714-8
4. Afşar H, Yagci F, Aybasti N, Meto S. Hydatid disease of the kidney. *Br J Urol* 1994;73:17-22
5. Pedrosa I, Saiz A, Arrazola J, Ferreirós J, Pedrosa CS. Hydatid disease: radiologic and pathologic features and complications. *Radiographics* 2000;20:795-817
6. Haliloglu M, Saatci I, Akhan O, Ozmen MN, Besim A. Spectrum of imaging findings in pediatric hydatid disease. *AJR Am J Roentgenol* 1997;169:1627-31
7. Altinörs N, Bavbek M, Caner HH, Erdogan B. Central nervous system hydatidosis in Turkey: a cooperative study and literature survey analysis of 458 cases. *J Neurosurg* 2000;93:1-8
8. Dahnिया MH, Hanna RM, Ashebu S, Muhtaseb SA, el-Beltagi A, Badr S, et al. The imaging appearances of hydatid disease at some unusual sites. *Br J Radiol* 2001;74:283-9
9. Ergün R, Okten AI, Yüksel M, Gül B, Evliyaoglu C, Ergüngör F, et al. Orbital hydatid cysts: report of four cases. *Neurosurg Rev* 1997;20:33-7
10. Bouckaert MM, Raubenheimer EJ, Jacobs FJ. Maxillofacial hydatid cysts. *Oral Surg Oral Med Oral Pathol Oral Radiol Endod* 2000;89:338-42
11. Rebhandl W, Turnbull J, Felberbauer FX, Tasci E, Puig S, Auer H, et al. Pulmonary echinococcosis (hydatidosis) in children: results of surgical treatment. *Pediatr Pulmonol* 1999;27:336-40
12. Anadol D, Göçmen A, Kiper N, Özçelik U. Hydatid disease in childhood: a retrospective analysis of 376 cases. *Pediatr Pulmonol* 1998;26:190-6
13. Holcomb GW III, Andrews WS. Gallbladder disease and hepatic infections. In: J.L. Grosfeld and J.A. O'Neill, Editors, *Pediatric surgery*, Elsevier, Mosby, 2006, p. 1646
14. Limas C, Soultanidis C, Kambouri A, Deftereos S, Gardikis S, Varitimidou E, et al. Multifocal hydatid disease in a child. *Pediatr Surg Int* 2004;20:384-6
15. Andronikou S, Welman CJ, Kader E. Classic and unusual appearances of hydatid disease in children. *Pediatr*

Radiol 2002;32:817-28

16. Macedo AJ, Magalhães MP, Tavares NJ, Bento L, Sampayo F, Lima M. Cardiac hydatid cyst in a child. *Pediatr Cardiol* 1997;18:226-8

17. Lamy AL, Cameron BH, LeBlanc JG, Culham JA, Blair GK, Taylor GP. Giant hydatid lung cysts in the Canadian northwest: outcome of conservative treatment in three children. *J Pediatr Surg* 1993;28:1140-3

18. Onal C, Barlas O, Orakdögen M, Hepgül K, Izgi N, Unal F. Three unusual cases of intracranial hydatid cyst in the pediatric age group. *Pediatr Neurosurg* 1997;26:208-13

19. Iuliano L, Gurgo A, Poletini E, Gualdi G, De Marzio P. Musculoskeletal and adipose tissue hydatidosis based on the

iatrogenic spreading of cystic fluid during surgery: report of a case. *Surg Today* 2000;30:947-9

20. Onbas O, Kantarci M, Alper F, Sekmenli N, Okur A. Spinal widespread intradural extramedullary hydatidosis. *Neuroradiology* 2004;46:310-2.

21. Gencer M, Ceylan E. Pulmonary echinococcosis with multiple nodules mimicking metastatic lung tumor in chest radiography. *Respiration* 2008;75:345

22. Celik M, Senol C, Keles M, Halezeroglu S, Urek S, Hacıbrahimoglu G, et al. Surgical treatment of pulmonary hydatid disease in children: report of 122 cases. *J Pediatr Surg* 2000;35:1710-3

Author Information

Mohammad Ghaemi

Professor of General Surgery, Mashhad University of Medical Sciences, Mashhad, Iran

Ehsan Soltani

Resident of General Surgery, Mashhad University of Medical Sciences, Mashhad, Iran