

# Management Of A Knotted Infant Feeding Tube In The Urinary Bladder

P Shah, R Desai, B Madhok

## Citation

P Shah, R Desai, B Madhok. *Management Of A Knotted Infant Feeding Tube In The Urinary Bladder*. The Internet Journal of Urology. 2004 Volume 2 Number 2.

## Abstract

Urethral catheterization is routinely used in pediatric patients for various indications. Intravesical knotting of the catheter is a rare event but can cause significant morbidity. We report a case of knotted infant feeding tube in urinary bladder successfully treated endoscopically. Tips on prevention and treatment of this condition are also given.

## INTRODUCTION

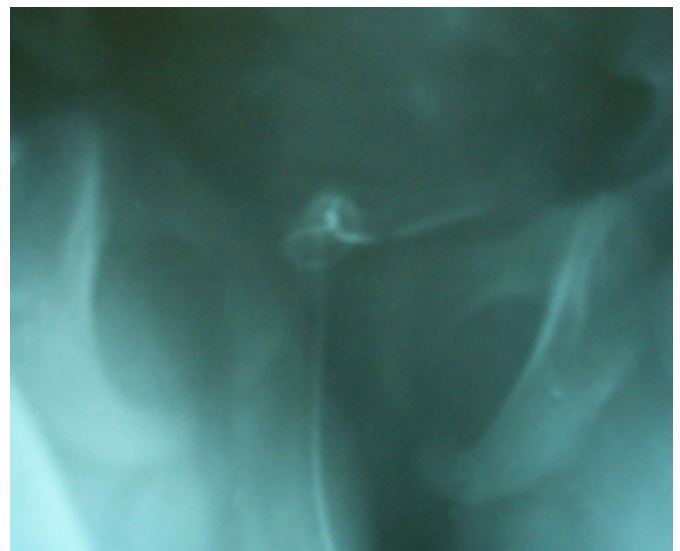
Per-urethral catheterization is routinely used for obtaining urine for culture, to relieve acute retention of urine, to monitor fluid balance in critically ill and following repair of hypospadias and urethroplasty. In these settings complications related to infection and catheter trauma have been reported<sup>1</sup>. Though intravesical knotting is an infrequently reported complication it can involve significant morbidity<sup>2,3,4</sup>. Due to relative rarity of this complication there is a lack of awareness in clinical community. We report a case of knotted infant feeding tube in urinary bladder successfully treated endoscopically. Tips on prevention and treatment of this condition are also given.

## CASE REPORT

A 3 year old male child underwent Byers' stage I urethroplasty & release of chordee under general anesthesia for penoscrotal hypospadias with chordee. Post-operative an 8 F green lined (radio opaque) infant feeding tube (IFT) was inserted for urinary drainage through the perineal stoma. On 10<sup>th</sup> postop day gentle attempts to remove the IFT failed. Even manual traction under local and general anesthesia failed to remove the IFT. Patient leaked urine by the side of IFT. Clinically knotting of IFT which prevented removal of IFT was suspected. This was confirmed on X-ray KUB (Fig 1). A double knot of the IFT was visible as the IFT had a radio opaque marker line.

## Figure 1

Figure 1: X-Ray KUB showing double knotting of IFT



Patient was taken for endoscopic removal of IFT under general anesthesia. A 10 F cystoscope was passed by the side of IFT into bladder to confirm the double knotting. The small size of urethra compared to the relative big size of the double knot prevented simple removal. The IFT was cut off at perineal stoma and pushed into bladder. The urethra and bladder neck were dilated sequentially over guide wire using fascial dilators to 16 F. It was then successfully removed by holding with foreign body holding alligator forceps passed through a short ureteroscope introduced through perineal urethrostomy. Fig 2 shows the double knot present 3 cm from proximal end. A 10 F Foley's catheter was kept for 7 days. Child passed urine subsequently with good stream and was continent.

### Figure 2

Figure 2: Double knot present in IFT 3 cm from proximal end



### DISCUSSION

IFT as per urethral catheter is routinely used in children for post-operative drainage because of ease of insertion and low cost. IFT knotting is a very rare event. It gets knotted when excessive length of flexible catheter is inserted in bladder and forms a loop. Subsequently as the catheter is withdrawn a knot can form and tightens on removal.

Removal of IFT has been tried in many ways:

1. Manual removal of catheter with gentle traction under local/general anesthesia.
2. The IFT is uncoiled by passing a guide wire in IFT and straightening it. This fails if knot is tight.

### 3. Suprapubic cystostomy.<sup>5</sup>

In the present case, gentle traction under GA failed. Because of small urethral caliber and post operative status it was necessary to cut off the IFT at the perineal stoma and push it into bladder and then do a guided urethral dilatation to facilitate endoscopic removal of the cut IFT with double knot thereby avoiding an open removal.

It is best to prevent this problem by totally avoiding use of IFT. A self-retained short tip pediatric Foley catheter from 6 F to 10 F serves all purposes. A high index of suspicion is required to diagnose knotting of IFT when a simple removal is not possible. This will prevent traumatic urethral injury due to forcible removal and subsequent risk of urethral stricture.

### CORRESPONDENCE TO

Dr. Brijesh Madhok 'MADHOK' Villa, Sindhwai Mata Road, Baroda 390 004. Phone : 0265-2654415, 098-252-68798 E-mail: brijeshmadhok@yahoo.co.uk

### References

1. Smith AB, Adams LL. Insertion of indwelling urethral catheters in infants and children: a survey of current nursing practice. *Pediatr Nurs* 1998; 24:229-34.
2. Foster H, Ritchey M, Bloom D. Adventitious knots in urethral catheter: report of 5 cases. *J Urol* 1992; 148:1496-8.
3. Kanengiser S, Juster F, Kogan S, Ruddy R. knotting of a bladder catheter. *Pediatr Emer Care* 1989; 5:37-9.
4. Pearson-Shaver AL, Anderson MH. Urethral catheter knots. *Pediatrics* 1990; 85:852-4.
5. Carlson D, Mowery BD. Standards to prevent complications of urinary catheterization in children: should and should knots. *J Soc Pediatr Nurs* 1997; 2:37-41.

**Author Information**

**Prashant N. Shah, M.S.**

Senior Resident, Department of General Surgery, Sir Sayaji General Hospital and Medical College

**Rasesh Desai, MCh(Uro), DNB(Uro)**

Associate Professor, Department of Urology, Sir Sayaji General Hospital and Medical College

**Brijesh Madhok, M., MS**

Senior Resident, Department of General Surgery, Sir Sayaji General Hospital and Medical College