

Tying laparoscopic intracorporeal knots with one instrument: "Dowais tie"

A DOWAIS, H SAMEI

Citation

A DOWAIS, H SAMEI. *Tying laparoscopic intracorporeal knots with one instrument: "Dowais tie"*. The Internet Journal of Surgery. 2008 Volume 21 Number 2.

Abstract

In laparoscopic surgery, intracorporeal suturing is one of the most important and difficult techniques. Laparoscopic intracorporeal knot tying in minimally invasive surgery is an advanced skill. Mastering this skill is a difficult process with a long learning curve. Intracorporeal suturing is essential in advanced laparoscopy and is a rate-limiting step in many procedures. The technique we wish to describe makes the art of knot-tying simple and straightforward by the use of a single laparoscopic needle holder. This technique, which we called "Dowais tie", is useful for totally trans-umbilical laparoscopic surgery. This simple and useful technique of intracorporeal knot tying is demonstrated in this report

TECHNIQUE

Pass the suitable suture with a straight needle through the abdominal wall, then cut the end of the suture, remove the needle and pass the suture around the target tissue (Fig. 1 a, b, c).

Make a loop with the long arm and grasp the long arm through the loop (Fig. 2a, b). While grasping the long arm rotate the needle-holding forceps clockwise making the first loop and continue rotating the needle-holding forceps to do the second loop (Fig. 3 a, b).

Release the long arm by opening the needle-holding forceps; then catch the distal end and pull the distal end through the loops (Fig. 4 a, b, c).

Control the tie by pulling the distal end from outside (Fig. 5).

Make the second tie by the same technique but rotate the needle holder in an anti-clockwise direction through the loop and use the same technique for the third tie in a clockwise direction (Fig. 6 a, b, c).

Figure 1

Fig. 1 a, b, c (a - target tissue, here it is the appendix, b - stitch through abdominal wall, c - long and short arm)

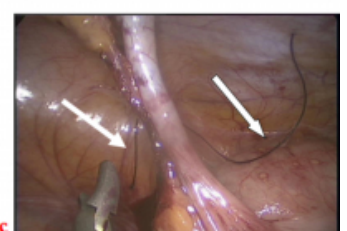
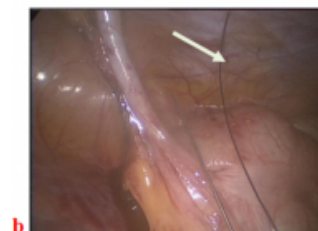
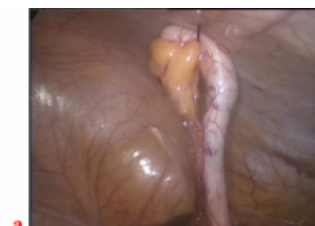
Figure 2

Fig. 2 a, b (making the loop)

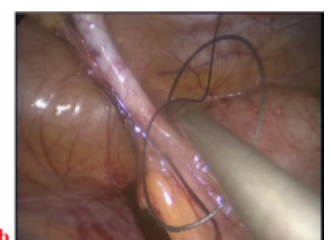
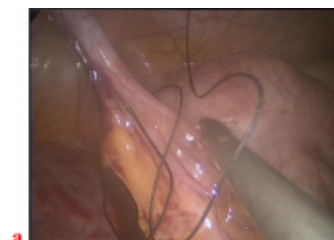


Figure 3

Fig. 3 a, b (making a - first loop, b - second loop)

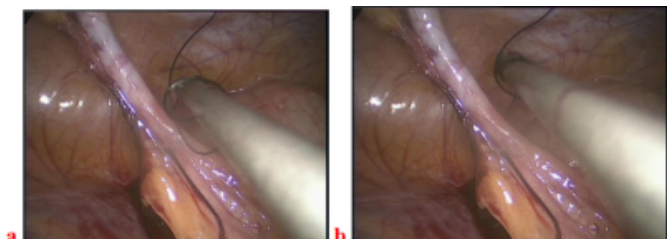


Figure 4

Fig. 4 a, b, c (a - releasing long arm, b - grasping short arm, c - pulling short arm)

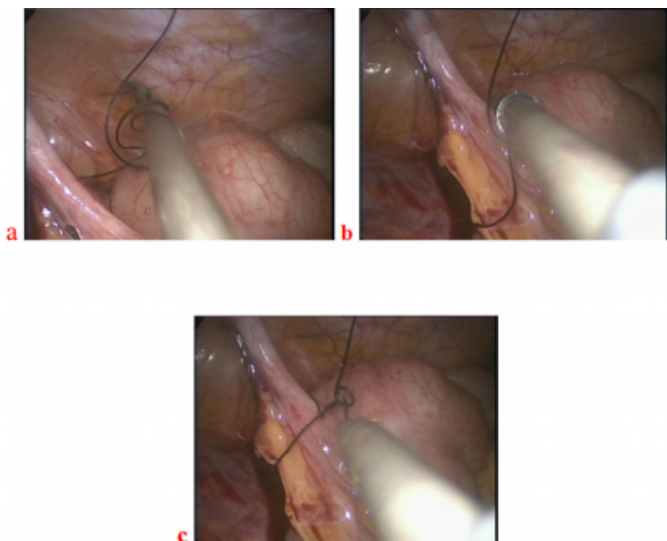


Figure 5

Fig. 5 (knot controlling)

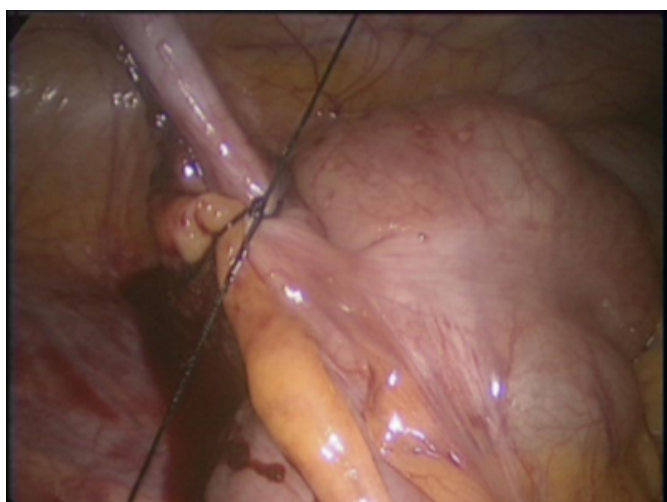
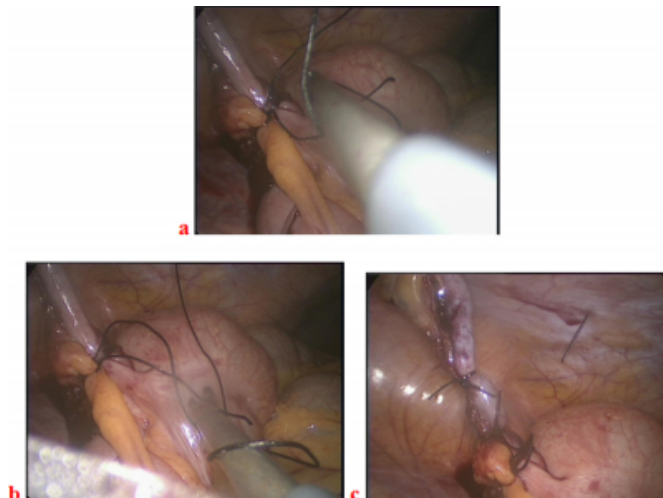


Figure 6

Fig. 6 a, b, c (a - second tie, b - third tie, c - the end)



DISCUSSION

This new technique was used in King Khalid Hospital in Najran, Saudi Arabia.

Laparoscopic suturing and knotting is difficult to perform, especially when the angle between the working instruments is narrow and working space is limited [1]. In these situations, knot tying using this technique makes knotting more simple and easy to perform, especially for those who have limited experience in intracorporeal suturing and knot tying. No special instrument is required to perform knot tying with this technique.

With the start of trans-umbilical laparoscopic surgery with its limitation in the space and the working instruments, we developed this new technique using one instrument which was named Dowais technique.

The three aims of tying intracorporeal knots are to minimize instrument movement, to control suture tension, and to create secure square knots using standard atraumatic needles and sutures [2].

Although minimally invasive surgery produces the same technical phases as traditional surgery, there are still some specific differences due to the limits inherent to its method. One of the most difficult acts in laparoscopic surgery is the knot-tying and suturing technique. The knots performed laparoscopically must be as safe as the traditionally performed ones [3].

In laparoscopic surgery, intracorporeal suturing is one of the most important and difficult techniques. Each laparoscopic surgeon trains alone to improve his techniques of suturing.

However, for most average surgeons the technique of tying a knot is still a difficult procedure in laparoscopic suturing [4].

In our hospital, we perform trans-umbilical laparoscopic cholecystectomy and appendectomy. We use this technique safely in ligation of the base of the appendix and of cystic duct if needed.

Using one instrument in this technique also gives the advantage of using the other instrument.

Laparoscopic intracorporeal knots with this technique became easy and without cost compared with pre-tied loops and the stapler.

CONCLUSION

This simple technique (Dowais Tie) for tying intracorporeal knots using one instrument is easy and of low cost and gives great help in totally trans-umbilical laparoscopic surgery where there are limitations of space and instruments.

References

1. Jagad RB. A new technique for intracorporeal knot tying in laparoscopic surgery. J Laparoendosc Adv Surg Tech A 2008; 18(4): 626-8.
2. Murphy DL. Endoscopic suturing and knot tying: theory into practice. Ann Surg. 2001; 234(5): 607-12.
3. Croce E, Olmi S. Intracorporeal knot-tying and suturing techniques in laparoscopic surgery: technical details. JSLS 2000; 4(1): 17-22.
4. Kawano T, Nishikage T. Open-jaw technique in laparoscopic knot tying. Surg Endosc 2008; 22(1): 269-70.

Author Information

ALI M. DOWAIS, MD

Department of General Surgery, King Khalid Hospital

HAMADA A. SAMEI, MD, MRCS

Department of General Surgery, King Khalid Hospital