

Communication Between Median And Musculocutaneous Nerve And Accessory Head Of Biceps Brachii: A Case Report

K Oluyemi, O Adesanya, C Saalu, U Okwuonu, D Ofusori, B Odion

Citation

K Oluyemi, O Adesanya, C Saalu, U Okwuonu, D Ofusori, B Odion. *Communication Between Median And Musculocutaneous Nerve And Accessory Head Of Biceps Brachii: A Case Report*. The Internet Journal of Surgery. 2006 Volume 12 Number 1.

Abstract

Communication between different branches of the brachial plexus is a common phenomenon that has several clinical and surgical implications. Forty-eight upper extremities were dissected to investigate the communication between median and musculocutaneous nerves. The cadavers were fixed in a mixture of four fixatives through femoral canulation. Communications were observed in two of the left arms. Their points of origin and course were evaluated. One of the biceps brachii muscles possessed an accessory head originating from the anterior surface of the left humerus. These anatomical variations are of crucial importance in brachial plexus block in the upper arm.

INTRODUCTION

Variations in the formation and branching pattern of the brachial plexus are well documented (Williams et al., 1999; Ken, 1918; Linell, 1921; Poynter, 1920). Some of these variations include prefixed and postfixed brachial plexus. In the former, the brachial plexus receives contribution from the ventral ramus of the 4th cervical spinal nerve, but contribution from the ventral ramus of the 1st thoracic spinal nerve is reduced or absent. In the postfixed type of formation, the 2nd thoracic nerve gives a contribution while a contribution from the 5th spinal nerve is reduced or absent (Williams et al., 1999). This is against the normal pattern in which the brachial plexus is formed by the ventral rami of the 5th to 8th cervical spinal nerves and a ventral ramus of the 1st thoracic spinal nerve.

The median nerve is formed by union of two roots from the lateral (C_{5,6,7}) and medial (C₈, T₁) cords (Pansky, 1984; Snell, 1995) while the musculocutaneous nerve (C_{5,6,7}) arises from the lateral cord of the brachial plexus. According to Tountas and Bergaman (1993), the musculocutaneous nerve arises from the lateral cord in 90.5%, from the lateral and posterior cord in 4%, from the medial cord in 2% and has two separate bundles from the medial and lateral cords in 1.4%.

Sometimes it sends a branch back to the median nerve in the brachium (Williams et al., 1999; Arora and Dhingra, 2005). Williams et al. (1999) stated that some fibers of the median

nerve may run in the musculocutaneous nerve leaving it to join their main trunk.

Crossing over of nerve fibres between the median nerve and the ulnar nerve in the forearm has been described as Martin-Gruber connections (Nakashima, 1993; Taams, 1997; Shu & Chantelot, 1999). These connections occur mostly in the forearm and have been implicated to cause confusion in the assessment of nerve injuries, carpal tunnel syndrome, cubital tunnel syndrome and leprosy neuropathy (Buschbacher, 1999).

In present study we present abnormal communications between musculocutaneous and median nerves among Nigerian cadavers and discuss their surgical implications.

CASE REPORT

During a routine dissection of twenty-four (24) formalin-fixed cadavers (23 males & 1 female) for medical students training at Igbinedion University, Okada, Nigeria, abnormal communications between the median and musculocutaneous nerves were unilaterally observed on the left brachia of two adult male cadavers. The cadavers were fixed by femoral canulation and injection of a fluid containing 10% formalin, liquid phenol, methylated spirit and glycerol. They were kept in storage tanks containing weak formalin solution for the period of 3 months before commencement of routine


dissection. They are normally returned back to the weak formalin solution after dissection to prevent hardening and maceration.

In one of the cadavers (Figure 1), the abnormal branch of the musculocutaneous nerve was found originating approximately at the mid point level of the brachial region distal to the insertion of the coracobrachialis muscle. It coursed inferiorly between the biceps brachii and brachialis muscles for about 4.2cm and joined the median nerve 8.7cm superior to the base of the cubital fossa. Giving its accessory branch and the nerve to the biceps brachii and brachialis muscle, the musculocutaneous nerve coursed normally as a lateral cutaneous nerve of the forearm. The course of the musculocutaneous nerve was normal in the forearm region.

On the other cadaver (Figure 2), the abnormal branch of the musculocutaneous nerve was found originating at the junction of the superior and middle thirds of the left brachium about 3cm before the insertion of the coracobrachialis muscle. It coursed inferiorly between the accessory head of biceps brachii and brachialis muscles for about 9.2cm and joined the median nerve 15.5cm below its origin and 5.5cm above the base of the cubital fossa. Giving its accessory branch and the nerve to the biceps brachii and brachialis muscle, the musculocutaneous nerve coursed normally as a lateral cutaneous nerve of the forearm. The course of the musculocutaneous nerve was normal in the forearm region. Other branches originating from the brachial plexus were also normal. In this brachium, the biceps brachii had an accessory head originating from the anterior surface of the left humerus (Fig. 2).

Figure 1

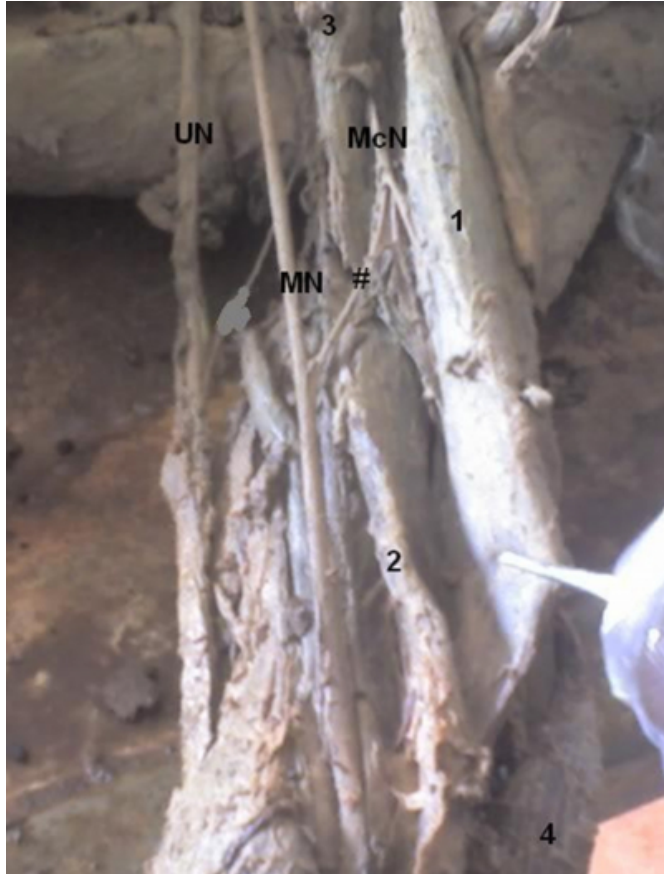
Figure 1: Median and musculocutaneous nerves are linked by the communication between them. The communication comes as a branch from the musculocutaneous nerve. It crosses the brachial artery anteriorly to join with the median nerve.



CB: Coracobrachialis; BB: Biceps Brachii; BM: Brachialis Muscle; AA: Brachial Artery; MCN: Musculocutaneous Nerve; MN: Median Nerve;

Figure 2

Figure 2: Note the communication between the median and musculocutaneous nerves (1) as it passes deep to the biceps brachii muscle over the accessory head of the biceps brachii muscle (2).



1: Biceps brachii; 2: Accessory head of biceps brachii; 3: Coracobrachialis; 4: Brachioradialis; UN: Ulnar nerve; McN: Musculocutaneous nerve; MN: Median nerve;

#: Communication between median and musculocutaneous nerve

DISCUSSION

Abnormal communications between median nerve and musculocutaneous nerve have been reported in many articles. Le Minor (1990) has described five types of median and musculocutaneous nerves variations in man.

Type I: There are no connecting fibers between the musculocutaneous and median nerve as described in classic textbooks (Arinci et al, 1997). The musculocutaneous nerve pierces the coracobrachialis muscle and innervates the coracobrachialis, the biceps brachii and brachialis muscle.

Type II: Although some fibers of the medial root of the

median nerve unite with the lateral root of the median nerve and form the main trunk of the median nerve, remaining medial root fibers run in the musculocutaneous nerve leaving it after a distance to join the main trunk of the median nerve.

Type III: The lateral root of the median nerve from the lateral cord runs in the musculocutaneous nerve and leaves it after a distance to join the main trunk of the median nerve.

Type IV: The fibers of the musculocutaneous nerve unite with the lateral root of the median nerve. After some distance, the musculocutaneous nerve arises from the median nerve.

Type V: The musculocutaneous nerve is absent (Arora & Dhingra, 2005). The fibers of the musculocutaneous nerve run within the median nerve along its course. In this type the musculocutaneous nerve does not pierce the coracobrachialis muscle.

Our finding belongs to the Type III variation. The lateral root of the median nerve is somewhat small in consonance with Canter et al. (2005).

Sargon et al. (1995) stated a variation of the median nerve which is formed by the union of three roots, two of them coming from the lateral cord. Arora and Dhingra (2005) reported a case in which the median nerve had three roots and the musculocutaneous nerve was absent. Canter et al. (2005) reported a case of abnormal communication in which the lateral root of the median nerve from the lateral cord was significantly normal and the abnormal communicating branch was significantly thick. This is against the general belief that the lateral root of the median nerve is usually abnormally small whenever there is a communication from musculocutaneous nerve to median nerve.

Venieratos and Anagnostopoulou (1998) reported three types of communications between median and musculocutaneous nerves considering the coracobrachialis muscle as the reference point. In type one the communication was proximal to the entrance of the musculocutaneous nerve into the coracobrachialis muscle, in type two the communication was distal to the muscle and in type three the nerve and the communicating branch did not pierce the muscle.

The presence of a communication between median and musculocutaneous nerves may be attributed to random factors influencing the mechanism of formation of limb muscles and the peripheral nerves during embryonic life.

Significant variations in nerve patterns may be a result of altered signalling between mesenchymal cells and neuronal growth cones (Sanes et al., 2000) or circulatory factors at the time of fusion of brachial plexus cords (Kosugi et al., 1986).

The existence of an accessory head of biceps brachii in our case report may be attributed to the random factors influencing the mechanism of formation of limb muscles and the peripheral nerves during embryonic life as it is known that the limb muscles develop from the mesenchyme of seemingly local myogenic precursor cells (Moore & Persaud, 2003).

In conclusion, surgical practitioners should be aware of these variations in the nerve formation in the brachium to prevent problems in surgical practices such as brachial plexus block.

References

1. Arora L, Dhingra R (2005). Absence of musculocutaneous nerve and accessory head of biceps brachii: a case report. *Indian Journal of Plastic Surgery*. Vol: 38, Issue: 2, pp 144-146.
2. Buschbacher RM. Mixed nerve conduction studies of the median and ulnar nerves. *Am J Phys Med Rehabil*, 78 (6): 69- 74, 1999.
3. Canter Halil Ibrahim, Erdem Adnan, Denk C. Cem. Variation between Median and Musculocutaneous Nerves. *The Internet Journal of Surgery*. 2005. Volume 6 Number 1.
4. Ken AT. (1918). The brachial plexus of nerves in man. The variation in its formation and branches. *American Journal of Anatomy*. 23: 285-395.
5. KO Taams. Martin-Gruber connections in South Africa, *J-Hand-Surgery-British*, 22 (3): 328-330, 1997.
6. Le Minor JM. A rare variation of the median and musculocutaneous nerves in man. *Arch Anat Histol Embryol* 1990; 73: 33-42.
7. Linell EA. (1921). The distribution of nerves in the upper limb with reference to variabilities and their clinical significance. *Journal of Anatomy* 55: 79-112.
8. Nakashima T. An anatomic study on Martin-Gruber anastomosis. *Surg Radiol Anat* 15: 193-195, 1993.
9. Necdet Kocabiyik, Bulent Yalcin, Fatih Yazar, Hasan Ozan (2005). An accessory branch of musculocutaneous nerve joining median nerve. *Neuroanatomy* 4: 13-15.
10. Pansky Ben (1984). *Review of Gross Anatomy*. 5th Ed. Macmillan Publishing Comp. New York. pp236.
11. Poynter CWM (1920). Congenital anomalies of the arteries and veins of human body with bibliography. *University studies*. University of Nebraska. 22:1-106.
12. Sargon MF, Uslu SS, Celik HH, Aksit D (1995). A variation of the median nerve at the level of brachial plexus. *Bull Assoc Anat (Nancy)* 79(246): 25-6.
13. Shu HS, Chantelot C. Martin-Gruber communicating branch: anatomical and histological study. *Surg Radiol Anat* 21: 115-118, 1999.
14. Snell S. Richard (1995). *Clinical Anatomy for Medical Students*. 5th Edition, Little. Brown and Company, USA, pp393-398.
15. Tountas C Bergaman R. Anatomic variation of the upper extremity. Churchill Livingstone, 1993; pp 223-224. In Arora L, Dhingra R. (2005): Absence of musculocutaneous nerve and accessory head of biceps brachii: a case report. *Indian Journal of Plastic Surgery*. Vol 38, Issue 2, pp 144-146.
16. Tountas C Bergaman R. Anatomic variation of the upper extremity. Churchill Livingstone, 1993; pp 223-224.
17. Venieratos D, Anagnostopoulou S (1998). Classification of communications between the musculocutaneous and median nerves. *Clin Anat* 11(5): 327-331.
18. Moore KL & Persaud TVN (2003). *The Development Human Clinically Oriented Embryology*. 7th Ed. Elsevier Science (USA) pg: 410-424.
19. Sannes HD, Reh TA and Harris WA. Development of the nervous system In: *Axon growth and guidance*. Academic Press New York: pp 189-197 (2000).
20. Kosugi, K, Mortia, T; Yamashita, H. (1986). Branching pattern of the musculocutaneous nerve; 1 case possessing normal biceps brachii. *Jikeikai Medical Journal* 33: 63-71.

Author Information

Kayode A. Oluyemi, B.Sc.

Department of Anatomy, School of Basic Medical Sciences, Igbinedion University

Olamide A. Adesanya, M.Phil, MSc, B.Sc

Department of Anatomy, School of Basic Medical Sciences, Igbinedion University

Chia L. Saalu, M.Phil, MSc, MBBS

Department of Anatomy, Lagos State University, College of Medicine (LASUCOM)

Uche C. Okwuonu, MSc, BSc

Department of Anatomy, School of Basic Medical Sciences, Igbinedion University

David A. Ofusori, MSc, BSc

Department of Anatomy, School of Basic Medical Sciences, Igbinedion University

Blessing I. Odion, BSc

Department of Medicine, School of Clinical Sciences, College of Medicine, University of Benin