

Prostatic utricle cyst – a case report and review of current literature

R Mukha, K Sriram, G Ganesh

Citation

R Mukha, K Sriram, G Ganesh. *Prostatic utricle cyst – a case report and review of current literature*. The Internet Journal of Urology. 2009 Volume 6 Number 2.

Abstract

We present a 23 year old mentally challenged male with hypospadias who presented with haematuria. Digital rectal examination revealed a large firm non-tender midline swelling whose upper limit could not be reached, palpable just above the prostate. CT scan showed a homogenously hypodense thick walled cystic lesion in the region of prostate, enhancing with contrast. Cystoscopy revealed a small opening at the summit of verumontanum in the midline. Intra-operatively, the thick walled hollow cavity was found in the retro-vesical region, adherent to the prostate and right seminal vesicle. Histopathological examination done showed that the wall of a cavitory lesion was lined by inflammatory granulation tissue suggestive of a prostatic utricle cyst. Enlarged prostatic utricles are commonly seen in patients with hypospadias, cryptorchidism and intersex. The posterior sagittal rectum-retracting approach has been described as one of the most suitable approaches for the surgical management of this condition.

CASE REPORT

A 23 year old male, mentally challenged since birth and a known case of hypothyroidism on regular treatment for 3 years presented with intermittent gross painless hematuria for 4 months. He did not have any lower urinary tract symptoms. There was no history of trauma or treatment for tuberculosis in the past.

He had similar episodes 2 years back and the hematuria subsided with conservative management. He underwent a repair of proximal penile hypospadias with chordee correction at 3 years of age.

His general and abdominal examination was normal. External genitalia showed evidence of previous hypospadias repair. The neomeatus was adequate in caliber, at the glans penis. Both testes were normal. Digital rectal examination revealed a normal sphincter tone with a large firm non-tender midline swelling palpable just above the prostate whose upper limit could not be reached,. Urine culture was sterile and renal functions were normal. The peak flow rate was 6ml/sec with a voided volume of 500 ml and a residue of 50 ml. CT scan (Fig 1 and Fig 2) showed a 3.1 x 2.8 x 3 cm homogenously hypodense thick walled cystic lesion in the region of prostate, enhancing with contrast. Kidneys, ureters and bladder appeared normal (Fig 3 and Fig 4).

Figure 1

Figure 1

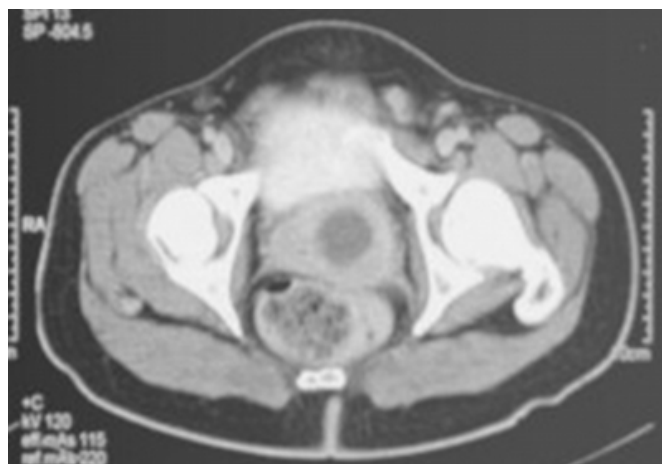

Figure 2

Figure 2

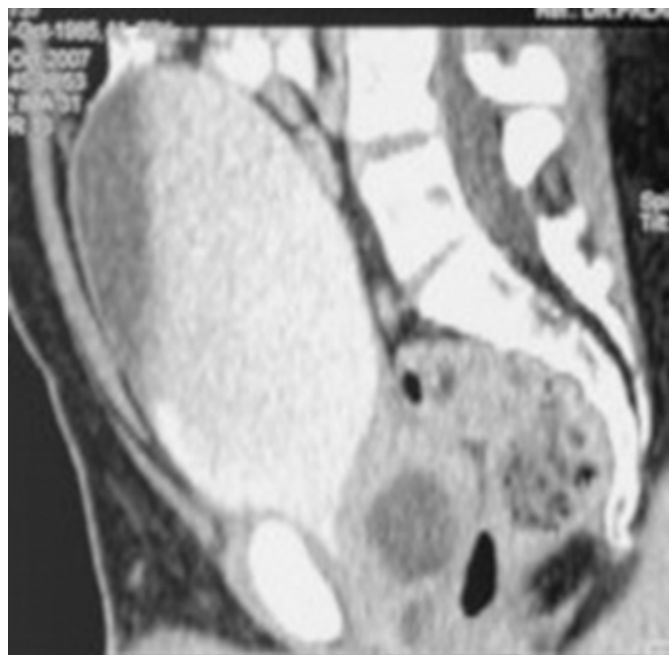

Figure 4

Figure 4

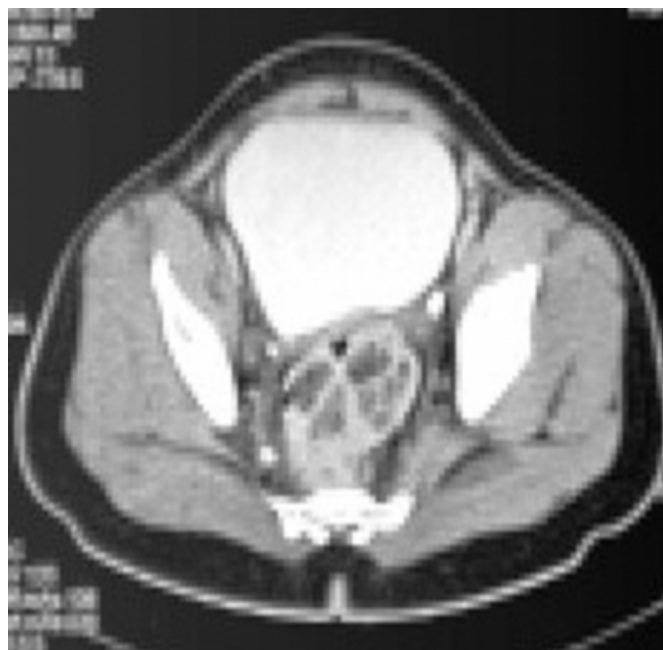
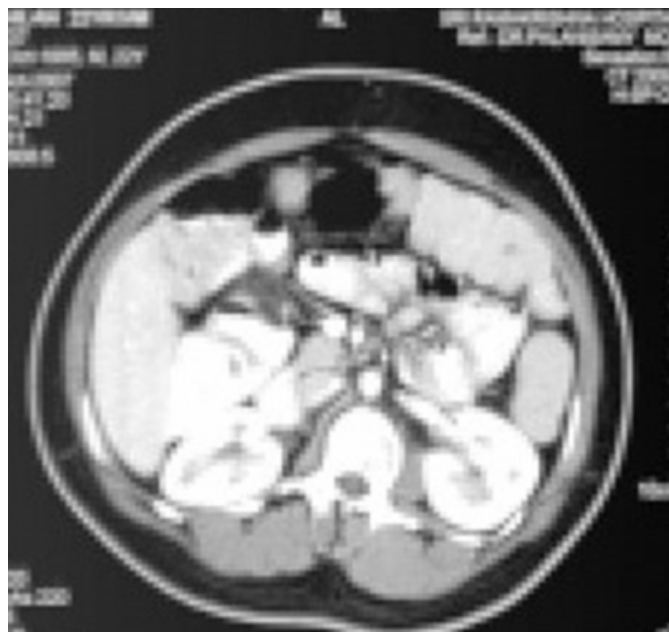
Figure 3

Figure 3

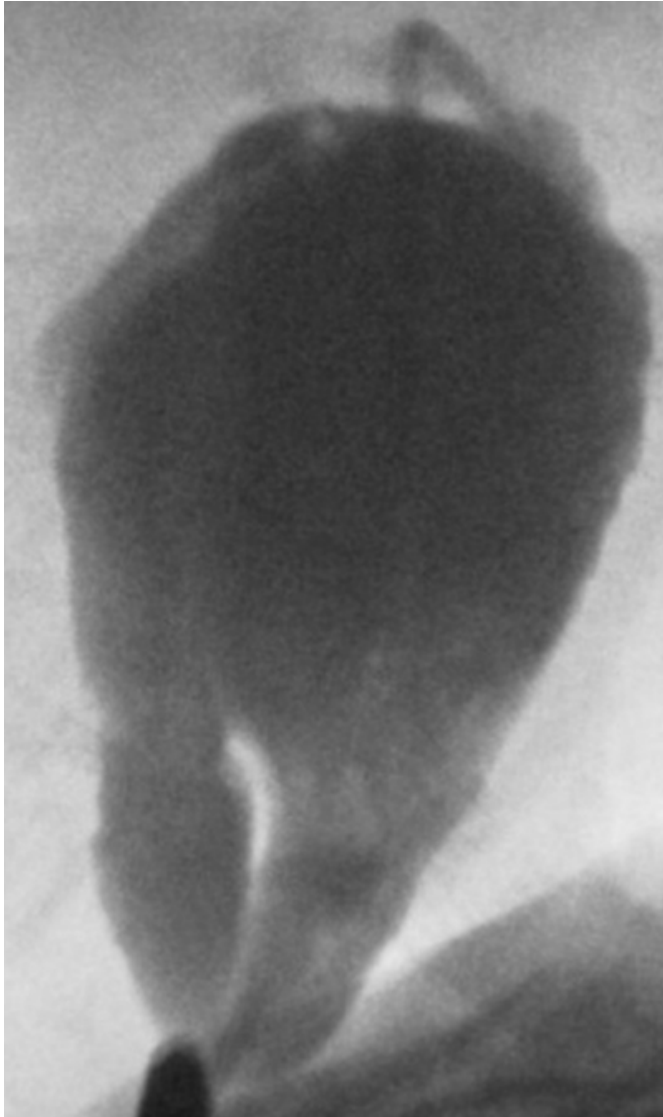


He underwent cystoscopy and examination under anesthesia followed by a trans-vesical excision of the cyst. Cystoscopy revealed a normal skin tube up to the penoscrotal junction. The urethral lumen was of adequate caliber. A 17Fr cystoscope could be easily negotiated. A small opening was seen at the summit of verumontanum in the midline. The opening was approximately 5 French (Fr) in caliber, but admitting a 7.5Fr ureteroscope with ease. Bladder capacity was normal. Both ureteric orifices were normal.

A 5Fr open end ureteric catheter was inserted into the opening and contrast injected, which showed a 15ml cyst with opacification of ejaculatory ducts (Fig 5).

Figure 5

Figure 5



Intra-operatively, the thick walled hollow cavity was found in the retro-vesical region, behind the trigone with inflammatory adhesions to the prostate and right seminal vesicle.

The gross pathological examination revealed a greyish white firm cyst, 6 x 3 x 2.5cm. Sectioning revealed greyish tan necrotic material. The maximum wall thickness was 1cm. Histopathological examination revealed the wall of a cavity lesion lined by inflammatory granulation tissue with dense infiltrates of neutrophils, eosinophils, foamy histiocytes, lymphocytes and plasma cells. The wall of the cyst was composed of fibro muscular connective tissue with fibrosis with features of chronic inflammation with lymphoid aggregates. There were no granulomas or evidence of malignancy. The final report was suggestive of a prostatic

utricle cyst.

DISCUSSION

The prostatic utricle is the homologue of the uterus and upper vagina in the female. It is derived from the fused ends of the Mullerian duct ^[1]. The secretion of the Mullerian regression factor in the male causes only the vestigial structures to remain, with the cephalic part persisting as the appendix testis and the caudal prostatic utricle. The prostatic utricle has been called the 'Utriculus masculinis' since it is considered to be the homologue of the uterus in the female. Prostatic utricle enlargement is seen in younger males usually in the first and second decades and is associated with hypospadias and intersex problems. The incidence of prostatic utricle cysts is 11% to 14% in association with hypospadias or intersex anomalies and increases up to 50% in the presence of perineal hypospadias ^[2]. The prostatic utricle is usually tubular and does not extend outside the prostate; it communicates with the posterior urethra in the majority of cases. On the other hand, the Mullerian duct cysts are rounded in shape, do not communicate with the prostatic urethra and are diagnosed later in adults with normal genitalia ^[2]. The clinical presentation is varied, which includes urinary frequency, urgency, dysuria, urinary obstruction, hematuria, and pelvic pain ^[3]. The diagnosis is suspected when the mass is felt on digital rectal examination. A pelvic ultrasound or a transrectal ultrasound will demonstrate the fluid filled cavity ^[3]. An MRI with an endorectal coil ^[4] is particularly useful to delineate the cyst from the other pelvic structures.

The complications arising from these cysts can be pain, hematuria, ejaculatory duct obstruction, epididymitis, and calculi formation ^[2] and in rare cases malignant transformation ^[4]. Gupta et al had reported a case of mullerian duct cysts presenting as a recurrent intra-abdominal mass ^[5]. The posterior sagittal rectum-retracting (PSRR) approach ^[6] has been described as one of the most suitable approaches for the surgical management of this condition. The treatment can be transurethral deroofting ^[7], laparoscopic ^[8] or an open transvesical excision ^[9].

CONCLUSIONS

Enlarged prostatic utricles are commonly seen in patients with hypospadias (11-14%), cryptorchidism and intersex ^[2]. MRI with an endorectal coil is one of the non invasive and accurate methods of diagnosing this condition ^[10]. The posterior sagittal rectum-retracting (PSRR) approach ^[6] has been described as one of the most suitable approaches for the

surgical management of this condition.

References

1. Witten DM, Myers GH, Utz DC. Anomalies of the genitourinary tract. Emmett's clinical urography, vol. 2. Philadelphia: Saunders, 1977:765-774
2. Luc Coppens, Pierre Bonnet, Robert Andrianne and Jean DE Leval. Adult Mullerian duct or utricle cyst: clinical significance and therapeutic management of 65 cases. The Journal of Urology April 2002. Vol 167, 1740 – 1744.
3. Charles Ariz, MD and Katarzyna J. Macura, MD, PhD. Applied radiology on line December 2005. Müllerian duct cyst. Volume: 34 Number: 12.
4. Nadine M. Aalame, Tullio Sulser, Urs Egli, Gabriel P. Krestin, Rahel A. Kubik-Huch. Primary male infertility caused by congenital prostatic cyst: Sonographic and magnetic resonance imaging findings. Urol Int 1998;61:58-61.
5. Gupta GG, Pandey AP. Mullerian duct cyst : Presenting as recurrent abdominal mass. Indian J Urol 2001; 17:176-177.
6. I. V. Meisheri á S. S. Motiwale á V. V. Sawant. Surgical management of enlarged prostatic utricle. Pediatr Surg Int (2000) 16: 199 ± 203.
7. Cornel EB, Dohle GR, Meuleman EJ. Transurethral deroofting of midline prostatic cyst for subfertile men. Hum Reprod. 1999 Sep; 14(9):2297-300.
8. McDougall EM, Clayman RV, Bowles WT. Laparoscopic excision of müllerian duct remnant. . J Urol. 1994 Aug; 152(2 Pt 1):482-4.
9. Goon HK, Tan KC, Sakijan AS. Mullerian duct cyst (utricular cyst): treatment with the transvesical, transtrigonal approach. Aust N Z J Surg. 1987 Sep;57(9):683-6.
10. In R. Cho, Moo S. Lee, Koon H. Rha, Sung J. Hong, Seok S. Park and Myeong J. Kim. Magnetic resonance imaging in hemospermia. Journal of Urology January 1997. Vol. 157, 258-262.

Author Information

RP Mukha, MS General Surgery

Christian Medical College and Hospital, Vellore, Tamil Nadu. India

K Sriram, MCH Urology

Christian Medical College and Hospital, Vellore, Tamil Nadu. India

G Ganesh, MCH Urology

Christian Medical College and Hospital, Vellore, Tamil Nadu. India