

# Endoscopic Treatment Of Recurrent Gastro-Gastric Stricture Following Revision Of A Divided Roux-En-Y Gastric Bypass

B Bal, S Lakhani, H Shah, F Finelli, T Koch

## Citation

B Bal, S Lakhani, H Shah, F Finelli, T Koch. *Endoscopic Treatment Of Recurrent Gastro-Gastric Stricture Following Revision Of A Divided Roux-En-Y Gastric Bypass*. The Internet Journal of Gastroenterology. 2008 Volume 8 Number 1.

## Abstract

Balloon dilation as a treatment for post-surgical anastomotic strictures is minimally invasive and relatively safe. The benefit of "through-the-scope" endoscopic balloon dilation has a reported long-term improvement for patient symptoms. This is a case report of a patient who developed severe dysphagia following revision of a divided Roux-en-Y gastric bypass with formation of a gastro-gastric anastomosis. The patient developed a gastro-gastric anastomotic stricture that rapidly recurred following multiple endoscopic dilations with balloon dilators. Following repeat endoscopic dilations, the anastomotic stricture was treated by submucosal injections of triamcinolone into the stricture, using a protocol described for esophageal strictures. Because this treatment prevented recurrent symptoms, she did not require repeat dilation for 3 months, prior to small intestinal transplantation. Repeat upper endoscopy prior to transplantation surgery revealed a patent gastro-gastric anastomosis. This case report demonstrates that injection of corticosteroid directly into a surgical anastomotic stricture improves the long-term efficacy of dilation.

## INTRODUCTION

The National Longitudinal Study of Adolescent Health and the National Health and Nutrition Examination Survey (NHANES) studies have shown that over 40% of the population is overweight, and the prevalence in 18 to 29 year olds has almost doubled to 19% between 1991 and 1999 (1). Roux-en-Y gastric bypass surgery has become an increasingly popular treatment option for morbid obesity (2, 3).

Anastomotic strictures causing recurrent obstructive symptoms are commonly seen following upper gastrointestinal surgeries (4). When oral intake becomes severely impaired owing to significant stricture, a rapid diagnosis and treatment is important. In recent years, balloon dilation has become the therapeutic option of choice since it is minimally invasive and relatively safe. However, the therapeutic efficacy of this procedure can be limited and often multiple dilations are required to make the patient symptom free (5-7). Multiple dilations increase the risk of the catastrophic complication of perforation (8).

Corticosteroids are known to inhibit fibrosis by preventing the migration and activation of inflammatory cells and fibroblasts. Various investigators have examined the role of

corticosteroid injection for treating recurrent esophageal strictures requiring multiple dilations (9, 10).

Gastro-gastrostomy is classically used as an anastomotic method during the reconstruction of pylorus preserving laparoscopic gastrectomy and during segmental gastrectomy for early gastric cancer and gastric ulcer. This case presents an unusual use of a gastro-gastrotomy complicated by a recurrent indolent stricture at the anastomotic site.

## CASE

This is a 40 year-old female who is status-post laparoscopic divided Roux-en-Y gastric bypass six years ago, followed by subsequent revision 2 years later for inadequate weight loss. She presented to an outside hospital with severe abdominal pain of one day duration associated with nausea and vomiting. An emergency exploratory laparotomy revealed a small intestinal volvulus with extensive necrosis of the jejunum. Infarcted small bowel was resected and the abdomen was packed without closure. The following day, due to both increasing serum lactate level and continued requirement for intravenous vasopressor drug, the patient had a repeat exploratory laparotomy. She was found to have further extensive necrosis of the ileum and ascending colon. Following resection of the infarcted bowel, she began to

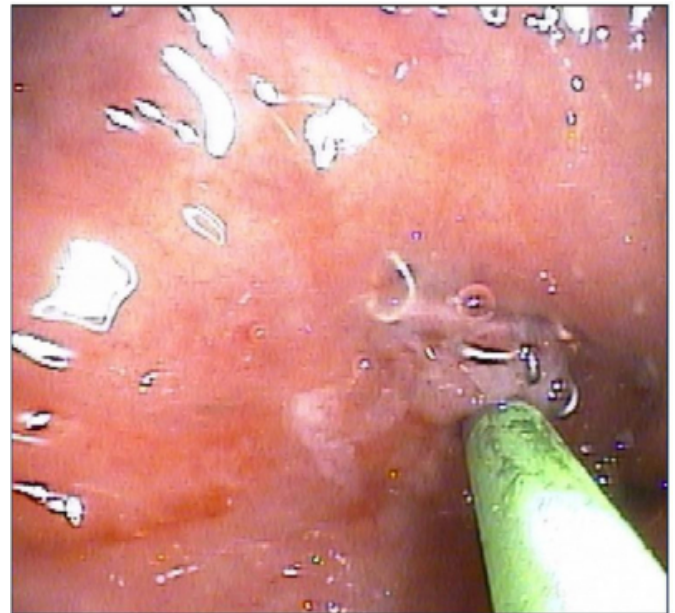
improve and was extubated successfully on post operative day 8.

The patient was transferred to our hospital for further management of her complicated condition. It was determined that the patient's gastrointestinal tract consisted of three separate segments: the esophagus with the blind gastric pouch; the excluded stomach and duodenum; and the colon from mid transverse colon to the anus. At repeat surgical exploration of the abdomen, there were extensive adhesions and inflammation. Additional infarction of mesentery and intestine were found in the abdominal cavity with leakage of bile from the duodenal stump. A duodeno-colostomy was planned as a bridge to small intestinal transplantation, but was not feasible due to the extensive inflammation. A gastro-gastrostomy was completed by bringing together the gastric pouch and the remnant stomach using an end-to-end anastomosis (EEA) stapler. In addition, a distal decompressive tube gastrostomy was performed with primary closure of the distal duodenum. Post-operatively the patient did well and was discharged home on total parenteral nutritional feedings in order to recover for a future small intestinal transplantation.

One month later, the patient was admitted to the hospital with severe nausea, vomiting and drooling of saliva. Upper GI endoscopy revealed a high-grade stricture at the site of the gastro-gastric anastomosis (see Figure 1).

**Figure 1**

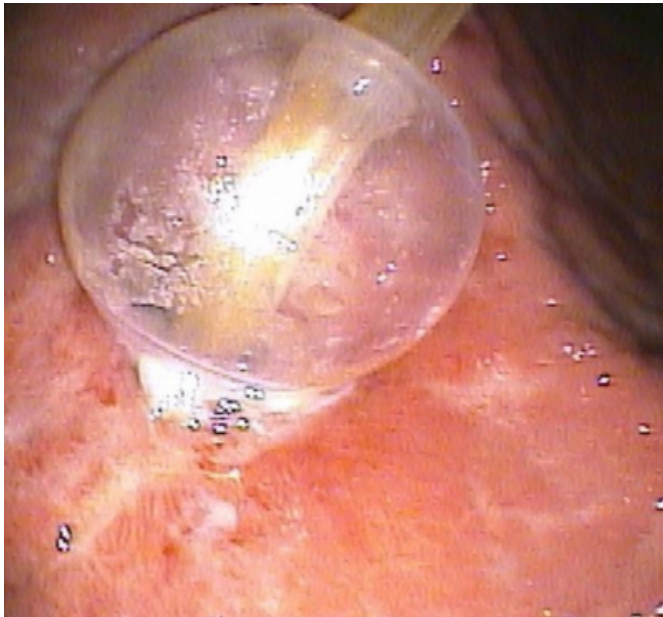
FIGURE 1. At upper GI endoscopy, a cannula was passed through a high-grade stricture at the site of the gastro-gastric anastomosis.



We were unable to pass a regular endoscope or a 6mm endoscope through this opening. A cannula was passed through the stricture under fluoroscopic guidance and contrast was injected to confirm the anatomy and position. The stenosis was then successfully dilated with 6 mm, 7 mm, 8 mm and 9 mm esophageal balloon dilators (see Figure 2).

**Figure 2**

FIGURE 2. At upper GI endoscopy, through-the-scope balloon dilation of a high-grade stricture at the site of the gastro-gastric anastomosis



Repeat upper endoscopy performed 3 days later revealed a residual stricture that was further dilated with 12 mm, 13 mm and 15 mm balloon dilators. The patient had partial relief of her symptoms and was discharged home with an outpatient follow-up appointment.

Patient returned to the hospital with intractable nausea and vomiting 10 days later and an upper GI endoscopy revealed recurrence of stricture at the gastro-gastric anastomosis. An adult 9.6 mm upper endoscope could not be passed through the anastomosis. The stricture was re-dilated with 8 mm, 9 mm and 10 mm balloon dilators. The patient was admitted to the hospital and three additional upper GI endoscopies were performed over the next ten days for continued nausea. During each procedure, balloon dilations of the anastomotic site was repeated. The dilation treatments however only provided temporary symptomatic benefit for the patient.

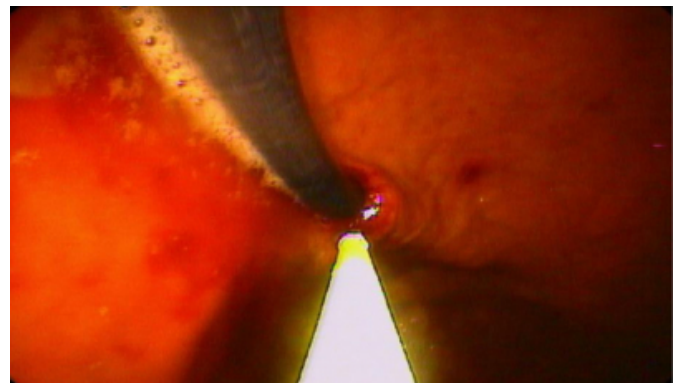A seventh upper GI endoscopy performed at day 50 after her surgery revealed a persistent high grade stricture at the gastro-gastric anastomotic site. The stricture was again dilated with a 12 mm balloon. During this session, the decision was made to inject triamcinolone into the anastomotic stricture using a published protocol (10); 10 mg of triamcinolone in multiple submucosal injections was injected circumferentially into the stricture (see Figure 3).

Following this corticosteroid injection, the patient did not

have any recurrent symptoms of upper gastrointestinal obstruction. She continued to do well symptomatically and no repeat dilations of the anastomosis were required. A repeat upper GI endoscopy at 3 months prior to small bowel transplant revealed a patent gastro-gastric anastomosis. At 3 months after small intestinal transplantation, she was clinically doing well.

**Figure 3**

FIGURE 3. At upper GI endoscopy, a cannula was passed following balloon dilation of a stricture at the site of the gastro-gastric anastomosis. In all 4 quadrants of the stricture, submucosal injections of triamcinolone were performed.



## DISCUSSION

This case demonstrates an effective strategy for improving long-term efficacy of endoscopic balloon dilation. Following complicated upper gastrointestinal surgery, patients often have long and complicated post-operative period associated with substantial morbidity. Multiple endoscopic balloon dilations are required to keep these patients free of symptom from upper gastrointestinal tract obstruction and maintain adequate oral intake. The incidence of perforation during therapeutic endoscopy with pneumatic dilatation ranges from 2% to 5% (8).

Injection of corticosteroids into anastomotic strictures is a safe and effective adjunct treatment (9, 10). Histological observation of biopsy specimens from stricture sites has revealed inflammation with edema, fibrosis, and abundant infiltration of polymorphonuclear cells and lymphoid cells. Therefore, corticosteroids seem to be a logical therapy for preventing strictures recurrence in the gastrointestinal tract by inhibiting the local inflammatory response.

Recently demonstrated multiple-cause mortality benefit from gastric bypass surgery will support this therapy for effective treatment of morbid obesity. As laparoscopic techniques have evolved surgeons are offering patients such an

approach for performance of gastric bypass surgery. Laparoscopic gastric bypass surgery is associated with a significant learning curve that is perhaps more pronounced than many other advanced laparoscopic procedures (3). As gastric bypass surgery becomes more common, new complications related to this surgery are starting to the surface (11), and novel techniques will have to be developed to deal with these complications.

## References

1. Mokdad AH, Serdula MK, Deitz WH. et al. The spread of the obesity epidemic in the United States 1991 - 1998. *JAMA* 1999; 282: 1519-1522.
2. Sugerman HJ, Kellum JM, Engle KM, et al. Gastric bypass for treating severe obesity. *Am J Clin Nutr* 1992; 55:560S-566S.
3. Schauer P, Ikramuddin S, Hamad G, Gourash W. The learning curve for laparoscopic Roux-en-Y gastric bypass is 100 cases. *Surgical Endoscopy* 2003; 17 (2): .
4. Nguyen NT, Stevens CM, Bruce BS, et al. Incidence and outcome of anastomotic stricture after laparoscopic gastric bypass. *J Gastrointest Surg* 2003; 7:997-1003.
5. Ide M, Sato N. Endoscopic dilatation for anastomotic stricture of the upper gastrointestinal tract. *Prog Dig Endosc*; 1990; 36: 90-94.
6. Ukleja A, Afonso BB, Pimental R, Szomstein S, Rosenthal R. Outcome of endoscopic balloon dilation of strictures after laparoscopic gastric bypass. *Surg Endosc* 2008; 22 (8): 1746-50.
7. Singh VV, Draganov P, Valentine J. Efficacy and safety of endoscopic balloon dilation of symptomatic upper and lower gastrointestinal Crohn's disease strictures. *J Clin Gastroenterol* 2005; 39(4): 284-90.
8. Sakurai H, McElhinney J. Perforation of the esophagus: Experience at Bronx VA Hospital 1969-1984. *Mt Sinai J Med* 1987; 54: 487-495.
9. Brooker JC, Beckett CG, Saunders BP, Benson MJ. Long-acting steroid injection after endoscopic dilation of anastomotic Crohn's strictures may improve the outcome: a retrospective case series. *Endoscopy* 2003; 35(4): 333-7.
10. Ramage JI Jr, Rumalla A, Baron TH, Pochron NL, Zinsmeister AR, Murray JA, Norton ID, Diehl N, Romero Y. A prospective, randomized, double-blind, placebo-controlled trial of endoscopic steroid injection therapy for recalcitrant esophageal peptic strictures. *Am J Gastroenterol* 2005; 100(11): 2419-25.
11. Higa KD, Boone KB, Ho T. Complications of the laparoscopic Roux-en-Y gastric bypass: 1,040 Patients - what have we learned? *Obesity Surgery* 2000; 10(6): 509-513.

**Author Information**

**Bikram S. Bal, MD**

Department of Medicine, Washington Hospital Center and Georgetown University School of Medicine, Washington, DC

**Shilen V. Lakhani, MD**

Department of Medicine, Washington Hospital Center and Georgetown University School of Medicine, Washington, DC

**Hiral N. Shah, MD**

Department of Medicine, Washington Hospital Center and Georgetown University School of Medicine, Washington, DC

**Frederick C. Finelli, MD**

Department of Surgery, Washington Hospital Center and Georgetown University School of Medicine, Washington, DC

**Timothy R. Koch, M.D., FACP**

Department of Surgery, Washington Hospital Center and Georgetown University School of Medicine, Washington, DC