

Isolated Dislocation Of Carpal Scaphoid: A Case Report

I Wani, N Guptha, R Guptha, A Salaria

Citation

I Wani, N Guptha, R Guptha, A Salaria. *Isolated Dislocation Of Carpal Scaphoid: A Case Report*. The Internet Journal of Orthopedic Surgery. 2007 Volume 10 Number 1.

Abstract

Scaphoid dislocation is an uncommon injury. This results from a forced dorsiflexion-supination force upon the hand. The proximal pole of scaphoid come to lie over radial styloid which is commonly fractured and depressed. Reduction is difficult to achieve by manipulation and open reduction is usually necessary. At the same time radial articular surface may be reduced and fixed by one or more fine k-wires. Isolated dislocation of scaphoid implies not only a rupture of the volar radiocarpal ligament but its capsular attachments to the lunate, capitate and the trapezium, the whole scaphoid may undergo avascular necrosis. We report a case of this rare injury which was missed before the patient presented to us.

CASE HISTORY

A 22 year old male presented to the outdoor department ten days after sustaining an injury to his right dominant wrist in a road traffic accident. He complained of pain, swelling and deformity of the right wrist. Examination of the right wrist revealed swelling, tenderness, ulnar deviation & a palpable prominence over the radial aspect of the wrist without any neurovascular deficit (Fig.1 &2). There was no other associated bony injury.

Figure 1

Figure 1

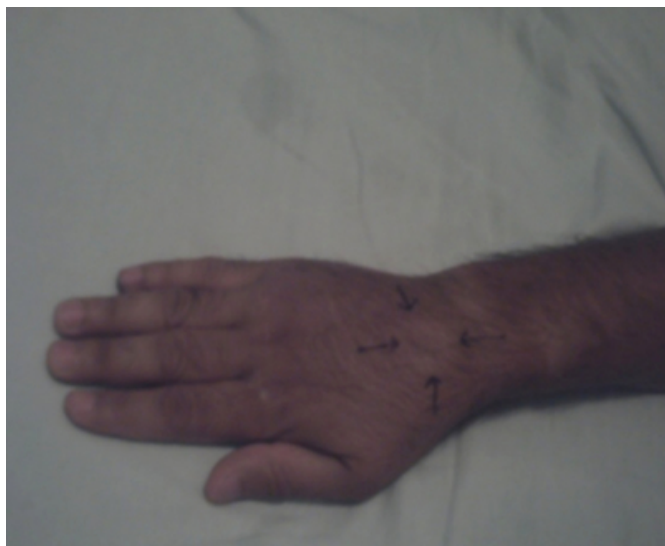
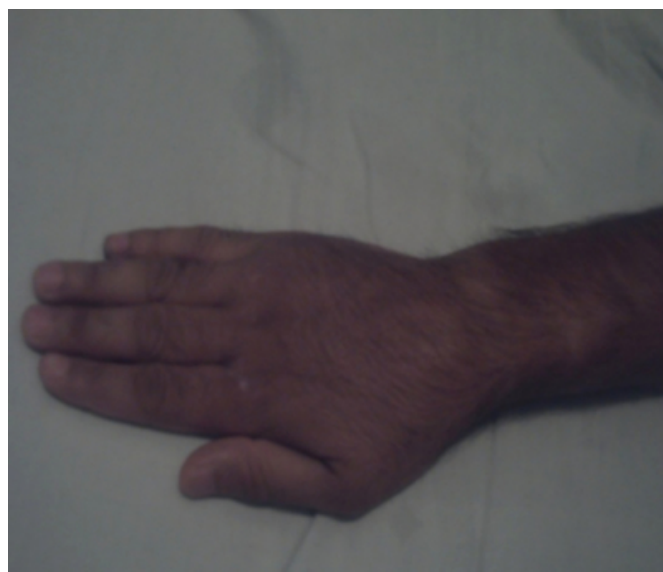
Figure 2

Figure 2



Radiographs (FIG.3& 4) revealed dislocation of scaphoid. There was no other associated bony injury. CT scan (FIG.5 & 6) confirmed the diagnosis of scaphoid dislocation.

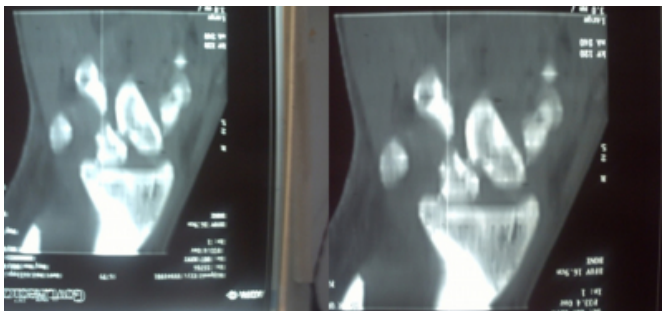
Figure 3

Figure 4

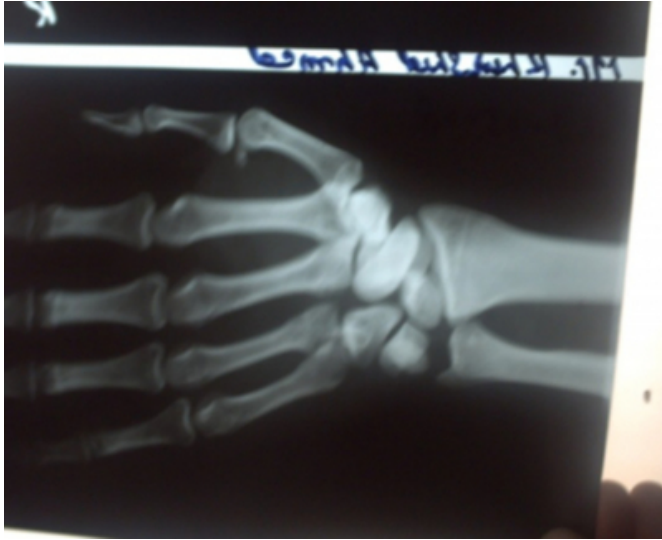

Figure 4

Figure 5 & 6: CT Scan Wrist



Patient was taken up for surgery under general anaesthesia. Pre-operatively fixation was planned. Wrist was approached by dorsal incision and scaphoid identified. The scaphoid was found to lie freely without any ligamentous attachments. Fixation was tried but was found to be very difficult and subsequently scaphoid excision was done followed by obliteration of the gap with surrounding fascia, fibrofatty tissue and Palmaris longus tendon. The rest of the carpus was fixed with k-wires fearing carpal instability. Post-operatively a below elbow pop slab was given till removal of stitches on 12th day. The, a below elbow pop cast was given for three weeks after removal of stitches. After removal of cast at three weeks, carpal stability was assessed & physiotherapy was started. There were no signs of carpal instability after removal of cast and thereafter. The patient is a teacher by profession and plays domestic cricket. Presently after one year of surgery the patient is doing well. There is no residual deformity or carpal instability & is asymptomatic except for occasional pain after severe strain and exertion of

the same wrist. There is no limitation of movements of the wrist after one year follow-up.

DISCUSSION

Dislocation of the scaphoid is rare and very few case reports have been published.^{1, 2 and 3} In 50% of the reported cases, the diagnosis was missed initially.² A characteristic radiographic feature of scaphoid dislocation is the palmar and radial displacement of the proximal pole of scaphoid out of the scaphoid fossa of the radius.³ Good functional results have been uniformly reported after both surgical and non surgical management, provided that the condition is recognised and treated early.² Delayed diagnosis not only increases the likelihood of open reduction for the dislocation but also affects the final outcome because of stiffness of the wrist and fingers and arthritis of intercarpal and radiocarpal joints.⁴ Simple radiographs are usually sufficient to make a diagnosis, and delay in recognition is mainly due to lack of awareness of this rare injury.

The exact mechanism of scaphoid dislocation is not known but it is generally believed that dorsiflexion, ulnar deviation with or without rotational forces are involved.^{2 and 3} It represents a spectrum of injuries with varying extent of ligamentous damage.^{2 and 3} Radiographs can provide some indication of the severity but wrist arthroscopy allows a more accurate assessment of individual ligaments and is a useful adjuvant modality in the management.³ Preoperative AP view Xrays of the wrist may show 'Cortical ring sign' indicating rotation of the scaphoid bone and suggesting injury to the interosseous scapholunate ligament. The avulsed radial styloid fragment may be still attached to the scaphoid and is equivalent to an injury to the radioscapocapitate ligament (which is always injured in scaphoid dislocations). The scaphoid fossa (on the distal radial articular surface) is empty and the proximal pole of scaphoid is displaced out, whereas lunate bone is present in its anatomical position in the lunate fossa. We did not observe any radiological changes suggestive of avascular necrosis of the scaphoid.

Because scaphoid dislocation is missed frequently, we aim to increase the awareness of this rare injury and emphasise that early diagnosis and treatment contributes significantly to good prognosis.

CORRESPONDENCE TO

Iftikhar H Wani PG Hostel Boys Govt. Medical College
Jammu Room No.215B Bakshi Nager Jammu, J & K,

INDIA. Email drihwani@yahoo.co.in phone no.
+91-9469212594.

References

1. S.A. Antuna and J.M. Antuna-Zapico, Open dislocation of carpal scaphoid: a case report, J Hand Surg 22-A (1997).
2. Y.F. Leung, Y.L. Wai, W.L. Kam and P.S. Ip, Solitary

- dislocation of the scaphoid-from case report to literature review, J Hand Surg 23-B (1998), pp. 88-92.
3. R.M. Szabo, C.C. Newland and P.G. Johnson et al., Spectrum of injury and treatment options for isolated dislocation of the scaphoid. A report of three cases, J Bone Joint Surg 77-A (1995), pp. 608-615.
 4. H. Takami, S. Takahashi and M. Ando, Dislocation of carpal scaphoid associated with median nerve compression, J Trauma 33 (1992), pp. 921-924.

Author Information

Iftikhar H. Wani, MBBS

Postgraduate Scholar Orthopaedics, Postgraduate Department of orthopaedics, Government medical college JAMMU, J & K

Nital Guptha, MBBS

Postgraduate Scholar Orthopaedics, Postgraduate Department of orthopaedics, Government medical college JAMMU, J & K

Rakesh Guptha, MBBS, MS (Orthopaedics)

Senior Resident Postgraduate Department Of Orthopaedics, Government medical college JAMMU, J & K

Abdul Q. Salaria, MBBS, MS (Orthopaedics)

Associate Professor Postgraduate Department Of Orthopaedics., Government medical college JAMMU, J & K