

An Unusual Retroperitoneal Mass –Non Functioning Retroperitoneal Paraganglioma

K Pandurengan, R Natarajan, R Marudavanan, T Sowmya, K Raja chidambaram

Citation

K Pandurengan, R Natarajan, R Marudavanan, T Sowmya, K Raja chidambaram. *An Unusual Retroperitoneal Mass –Non Functioning Retroperitoneal Paraganglioma*. The Internet Journal of Endocrinology. 2010 Volume 6 Number 2.

Abstract

A paraganglioma is a rare neuroendocrine neoplasm that may develop at various body sites (including the head, neck, thorax and abdomen). About 97% are benign and cured by surgical removal; the remaining 3% are malignant because they are able to produce distant metastases. When presenting within the abdominal cavity, they may arise as a primary retroperitoneal neoplasm and can mimic vascular malformations or other conditions related to specific retroperitoneal organs such as the pancreas, kidneys, or adrenals. Retroperitoneal paragangliomas are mostly benign with good prognosis; however, they can present with abdominal pain, palpable mass, or hypertensive episodes. Patients should be initially evaluated with catecholamine levels, followed by computed tomography or magnetic resonance imaging to locate the primary lesion. Surgical excision remains the mainstay of treatment, although advanced disease and proximity to vital organs can make excision difficult or impossible. We report a rare case of retroperitoneal mass presented to be a non-functioning Paraganglioma.

INTRODUCTION

Pheochromocytomas and extra-adrenal paragangliomas are rare tumors arising from neural crest tissue that develops into sympathetic and parasympathetic paraganglia throughout the body. Sympathetic paraganglia include the following: The adrenal medulla, the organ of Zuckerkandl near the aortic bifurcation, other paraganglia along the distribution of the sympathetic nervous system. Parasympathetic paraganglia include the following: The carotid body, other paraganglia along the cervical and thoracic branches of the vagus and glossopharyngeal nerves. The most recent World Health Organization classification utilizes the term pheochromocytoma exclusively for tumors arising from the adrenal medulla and the term extra-adrenal paraganglioma for similar tumors that arise from other locations. [1]. Like our case, mass presenting within the abdomen, they may arise as a primary retroperitoneal neoplasm and can be mistaken for other retroperitoneal tumors, including those arising from the pancreas. This case report describes a patient who presented clinically suspected to be a pancreatic mass arising from the body and tail which was discovered to be a non functioning paraganglioma, successfully treated was reported.

CASE REPORT

A 35 year old female presented to us with upper abdominal pain for past one year which was vague constant dull aching, sometimes radiating to the back. On clinical examination the mass occupied the part of the left hypochondrium, epigastrium and left lumbar (figure-2) region. The patient was normotensive and otherwise she was clinically normal. Basic hematological work up, liver function test, serum amylase and lipase, adrenal hormonal profile turned out to be normal. Computed tomography (figure-1) revealed a retroperitoneal mass arising below the body and tail of the pancreas and anterior to the left kidney. Both adrenal glands were normal. After complete anesthesia workup, laparotomy was done which reveals a variable consistency-more of cystic component retroperitoneal mass of size 20x15x12 cm inferior to the body and tail of the pancreas, anterior to the kidney was found (figure-3a, 3b, 4).intraoperatively no vascular invasions made out hence the tumor was resectable, complete excision of the tumor done without intraoperative alterations in bloodpressure. Histopathology of the mass reveals features of Paraganglioma (figure-5).

Figure 1

FIGURE: 1: CT-ABDOMEN-Reveals retroperitoneal mass arise below the body and tail of pancreas and anterior to the left kidney. Both adrenal glands was normal

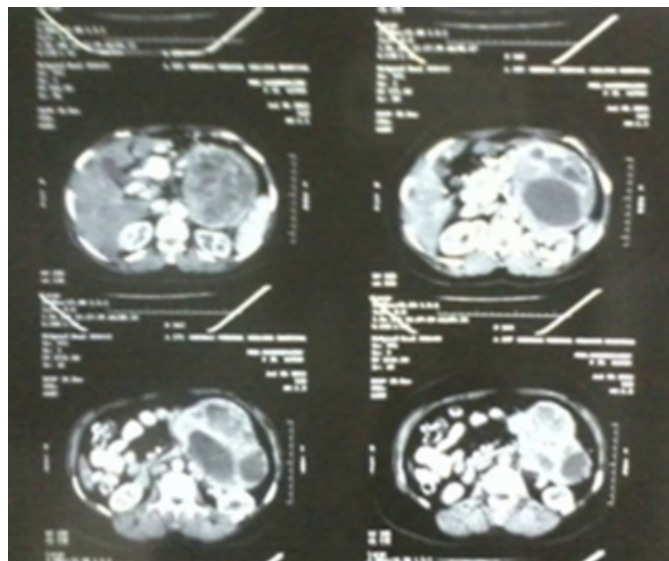


Figure 2

FIGURE: 2: Visible mass occupying the epigastric and left lumbar region.

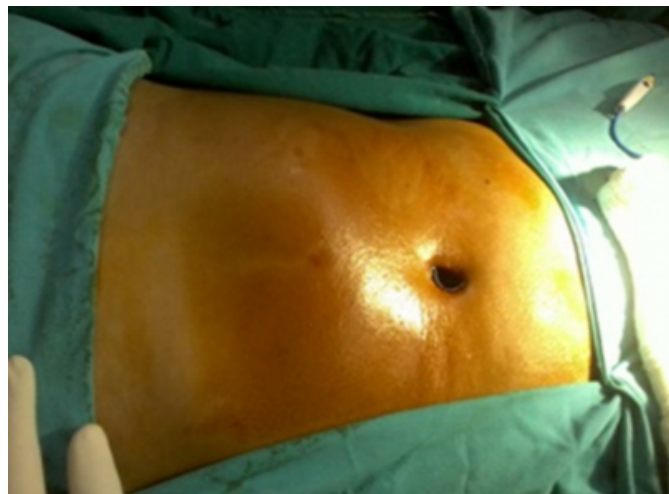

Figure 3

FIGURE: 3(a): Intra Operative Retroperitoneal Mass

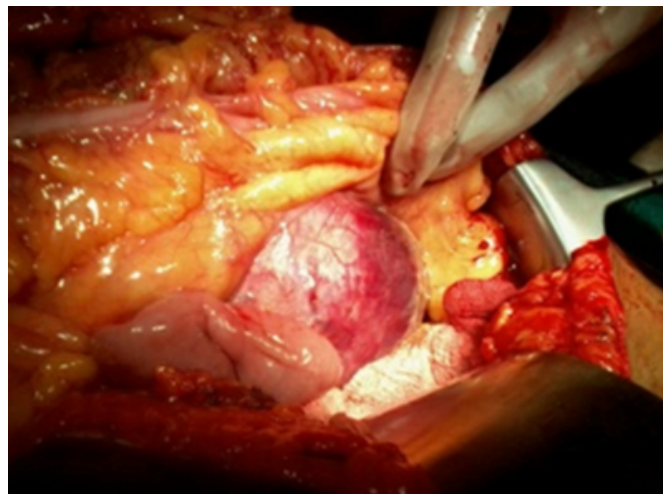


Figure 4

FIGURE: 3(b): Intra Operative Retroperitoneal Mass

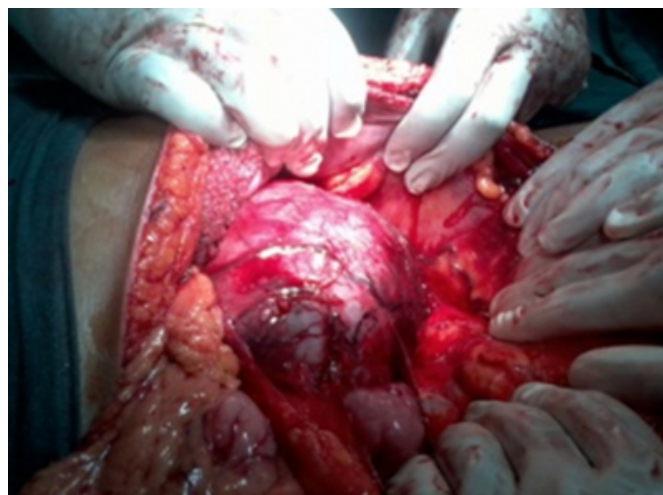

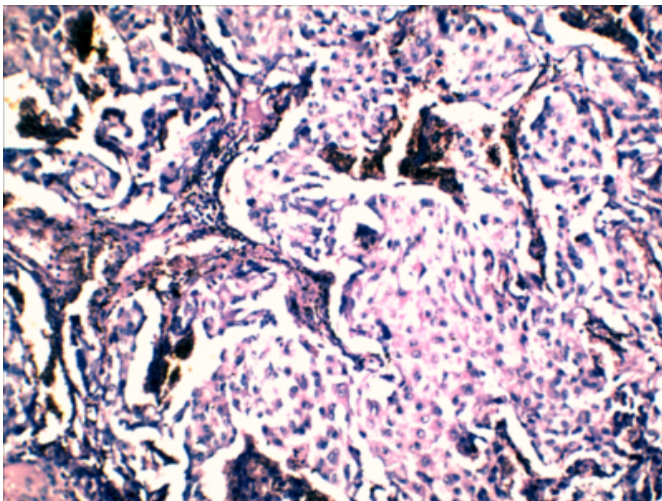
Figure 5

FIGURE :(4): Tumor bed

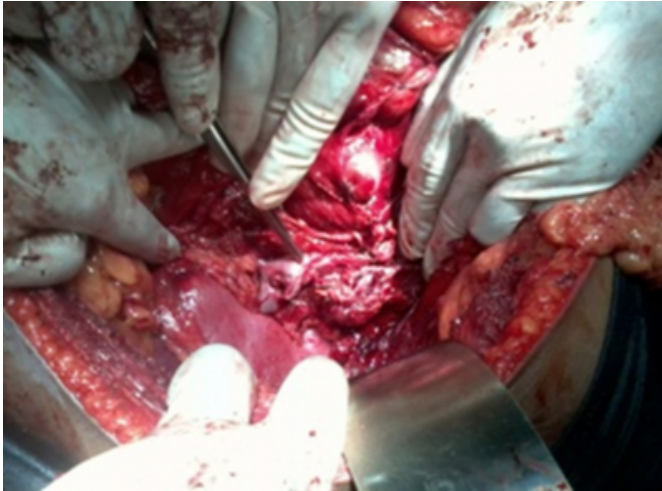

Figure 6

FIGURE :(5): Histopathology: reveals Paraganglioma.



DISCUSSION

Paragangliomas are extra-adrenal pheochromocytomas that arise from chromaffin cells in the sympathetic (localized in retro peritoneum and thorax) or parasympathetic (next to aortic arch, neck, and skull base) neural paraganglia [2]. They account for 10% of adult pheochromocytomas. About 70% of sympathetic paragangliomas are intraabdominal, usually found in the perinephric and paraaortic spaces. The

remaining 30% are located in the chest. Malignant retroperitoneal paragangliomas range from 30% to 50% [3]. Paragangliomas metastasize approximately in 20% to 42% of the cases. Dissemination can be hematogenous or through the lymphatic system, with the most common site of metastasis being the regional lymph nodes, bone, lung, and liver. Because benign and malignant paragangliomas have the same histological appearance, the best predictor for outcome is metastasis or recurrence [2].

The nonfunctioning type most commonly presents as abdominal pain or mass [4]; a large proportion of these tumors are incidentally discovered in normotensive patients during imaging evaluation for other reasons [5]. These nonfunctioning tumors are mostly benign and even if they turn malignant they metastasize late. Hence complete excision of the tumor is always advisable in absence of vascular invasion or metastasis to regional lymph nodes or liver. Surgery remains the best way of treatment as we proceeded in our case.

In conclusion any Retroperitoneal mass with diagnostic difficulty preoperatively and not able to locate the organ from which it is arising, they can be thought of paragangliomas and complete biochemical workup is always advisable to rule out Pheochromocytoma in view of dangerous alterations in Blood Pressure that can occur which may lead to loss of patients life even on table.

References

1. DeLellis R, Lloyd R, Heitz P, eds. Pathology and Genetics: Tumours of Endocrine Organs (IARC WHO Classification of Tumours). Lyon, France: IARC Press, 2004.
2. S. E. Rha, J. Y. Byun, S. E. Jung, H. J. Chun, H. G. Lee, and J. M. Lee. Neurogenic tumors in the abdomen: tumor types and imaging characteristics, Radiographics, vol. 23, no. 1, pp. 29–43, 2003.
3. J. H. Yang, S. J. Bae, and S. J. Bae, Bilateral pheochromocytoma associated with paraganglioma and papillary thyroid carcinoma: report of an unusual case. Endocrine Journal, vol. 54, no. 2, pp. 227–231, 2007.
4. G. A. Kaltsas, G. M. Besser, and A. B. Grossman, tumors, Endocrine Reviews, vol. 25, no. 3, pp. 458–511, 2004.
5. E. E. Elder, G. Elder, and C. Larsson. Pheochromocytoma and functional paraganglioma syndrome: no longer the 10% tumor. Journal of Surgical Oncology. vol. 89, no. 3, pp. 193–201, 2005.

Author Information

Karthick Pandurengan, M.S (general surgery).F.MAS

Assistant professor, Department Of General Surgery, Chennai Medical College Hospital and Research Centre

R.M. Natarajan, M.S

Department Of General Surgery, Chennai Medical College Hospital and Research Centre

R. Marudavanan, M.S

Department Of General Surgery, Chennai Medical College Hospital and Research Centre

T.K. Sowmya, M.S

Department Of General Surgery, Chennai Medical College Hospital and Research Centre

K. Raja chidambaram, M.S

Department Of General Surgery, Chennai Medical College Hospital and Research Centre