

Postpartum Stress Fracture of The Sacrum: A Case Report

D ESKIN, S MEMISOGLU, C COPUROGLU, M OZCAN

Citation

D ESKIN, S MEMISOGLU, C COPUROGLU, M OZCAN. *Postpartum Stress Fracture of The Sacrum: A Case Report*. The Internet Journal of Orthopedic Surgery. 2008 Volume 14 Number 1.

Abstract

The pelvic joints undergo changes during not only pregnancy and delivery but also postpartum that are due to hormonal influences and mechanical stresses. Pain in the low back and sacrum is common during pregnancy and postpartum period. However delivery-related sacral fracture is an uncommon complication that should be considered in the differential diagnosis of low back pain during the postpartum period. We report the case of a woman without osteoporosis and trauma who had a stress fracture of the sacrum. The patient was 31 years old and her fracture was diagnosed five months after her delivery. All standard laboratory tests were normal and direct radiographs of the pelvis showed no pathology. But computed tomography and magnetic resonance imaging demonstrated a fracture of the right sacral wing. In conclusion, stress fractures of the sacrum should be considered in the differential diagnosis of low back pain during the pregnancy and postpartum period. Computed tomography and magnetic resonance imaging is a useful technique for diagnosis.

BACKGROUND

During pregnancy, delivery and postpartum period, the female body undergoes some hormonal and anatomical changes that are due to hormonal influences and mechanical stresses. These changes cause, or contribute to the cause of, musculoskeletal conditions such as low back pain and buttock pain [1]. However delivery-related sacral stress fracture is an unusual condition that should be considered in the differential diagnosis of low back pain during the postpartum period [2]. We report the case of a woman without osteoporosis and trauma who had a stress fracture of the sacrum.

CASE PRESENTATION

A thirty one year old woman presented with low back and right buttock pain which started five months after her delivery. The patient did not experience pelvic or spinal pain during pregnancy, and there was no history of trauma or endocrine or metabolic diseases. No smoking or use of heparin was reported. The patient was primiparous, and she was breast-feeding her baby. She had dietary calcium intake and supplementary tablets including 500 mg of calcium per day during her pregnancy, but had not any supplement during the postpartum period. During the pregnancy, she gained 12 kg. No problems were reported after cesarean section and deliver a healthy 3600 g baby.

Five months after her delivery, the right sacroiliac joint was

excruciatingly painful with any slight motion. She had tenderness on her right sacroiliac joint with pressure and Milgram and Laseque tests were positive. There was no neurovascular abnormality. Blood cells counts, tests for inflammation, serum and urinary levels of calcium and phosphate, renal function and parathyroid function tests were normal (table 1). There was no evidence of osteomalacia in the laboratory studies. Plain radiographs of the pelvis and lumbar spine showed no osteoarticular abnormalities. According to these findings we thought that she had lumbar radiculopathy. So we decided to take magnetic resonance imaging (MRI) to demonstrate pathological findings. MRI of the pelvis demonstrated a stress fracture through the upper part of the right sacral wing and diagnosis was confirmed by Computed tomography (CT).

The patient was treated with conservative methods such as bed rest and analgesics. Two months later, her pain had resolved and the clinical outcome was favorable.

CONCLUSIONS

The cases of only nine patients who had a sacral fracture during pregnancy or the postpartum period have been reported in the world-wide literature as far as we know [2, 3, 4, 5, 6, 7, 8, 9]. However, the prevalence is probably underestimated since low back pain is common during pregnancy and usually resolves after delivery. Also it usually resolves during the postpartum period, so that imaging

studies are rarely performed to investigate this symptom [2].

The risk factors for sacral stress fractures during pregnancy and the postpartum period may include vaginal delivery of a high-birth-weight newborn, increased lumbar lordosis, excessive weight gain, a rapid vaginal delivery, selected obstetric maneuvers and forceps instrumentation, and sports activities such as jogging [2]. But our patient had no history of trauma in her cesarean section.

Fractures can be the initial manifestation of osteoporosis during pregnancy or postpartum [4, 7, 10]. Vertebral fractures and fractures of the femoral neck, pelvic, ribs and wrists have been reported. Many of these reported cases have occurred in primigravidas who had osteoporosis develop during the last trimester of pregnancy or shortly after delivery[4, 6]. However, a few patients with a sacral fracture associated with pregnancy-related osteoporosis have been reported [11]. Osteomalacia (vitamin-D deficiency) is another cause of nontrauma related fracture during pregnancy and the postpartum period [12]. However, in our patient, the MRI findings revealed normal bone-marrow signal intensity and the initial serum levels of

calcium, phosphorus and alkaline phosphatase were normal (table 1). The absence of relevant risk factors for an insufficiency or stress fracture makes the diagnosis unclear in this case. There was no history of trauma or endocrine or metabolic diseases. We believe that a delivery-related stress fracture is the most probable diagnosis in this patient.

Figure 1

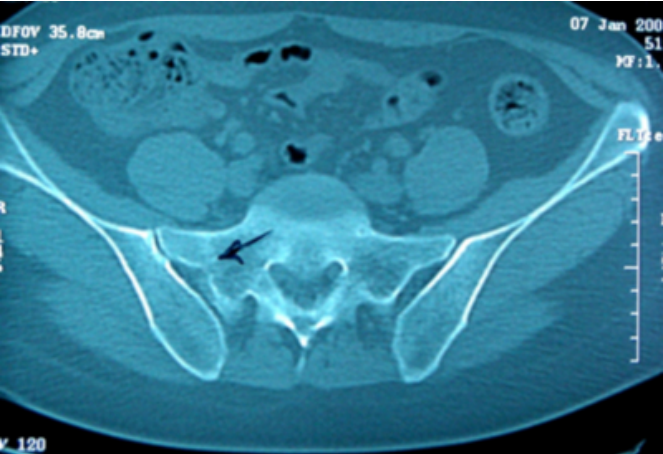
Table 1. Markers for calcium and phosphate metabolism

Markers	Values at presentation	Normal values
Total serum calcium	9.4	8.4-10.2 mg/dl
Serum phosphate	4.5	2.3-4.7 mg/dl
Serum alkaline phosphatase	84	40-150 UI/L
Serum albumin	4.1	3.5-5.0 g/dl
Serum creatinine	0.67	0.6-1.3 mg/dL
Serum parathyroid hormone	58.2	10-72 pg/mL
Serum osteocalcin	14.5	2-21 ng/mL
Urinary	21	7-40 mg/dL

In this case, no pathology of the pelvis could be observed with plain radiographs. In all reported cases, the diagnosis was confirmed by MRI and/or CT. CT is both sensitive and specific and seems to be the imaging modality of choice for evaluating bone structure (figure 1); however, it is not recommended during pregnancy.

Figure 2

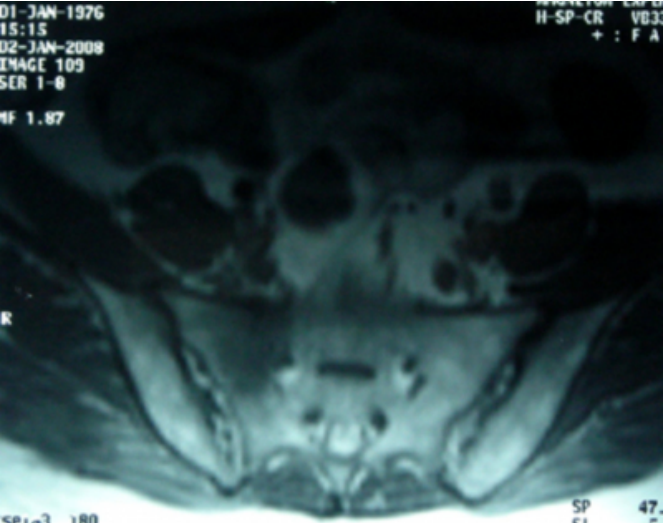
Figure 1. Computed tomography of the fracture



But our patient’s complaint started five months after her delivery. So we preferred CT and MRI which demonstrated a fracture of the right sacral wing. MRI studies have similar sensitivity and can be performed throughout pregnancy [6, 12]. In addition, MRI imaging can provide an evaluation of the soft tissues [13]. On T1-weighted images, the fracture was seen as a low-intensity line surrounded by a hypodense region of surrounding osseous edema (figure 2).

Figure 3

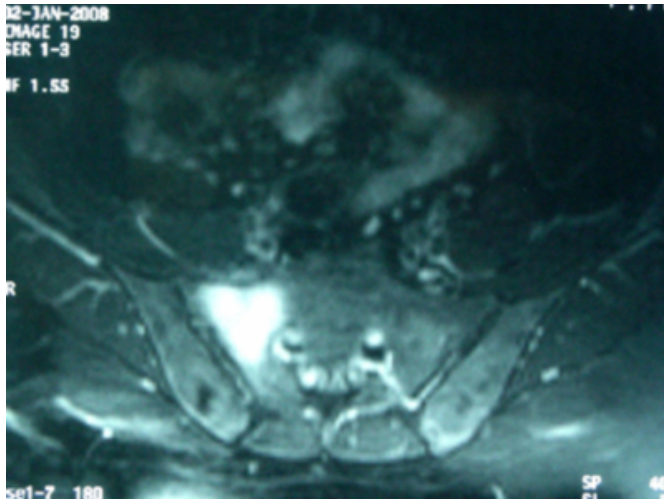
Figure 2. T1-weighted sequences showing the fracture



On T2- weighted sequences, the fracture line was seen as a moderate low-intensity signal or isosignal within the high signal area produced by the edema (figure 3).

Figure 4

Figure 3. T2-weighted sequences showing the fracture



These fractures have a low risk of complication; thus, conservative treatment is the recommended treatment modality. Analgesics and rest until resolution of the pain should be recommended[2]. In this case, two months later, the pain had resolved and the clinical outcome was favorable.

In conclusion, stress fractures of the sacrum should be considered in the differential diagnosis of low back pain during the pregnancy and the postpartum period. CT and MRI is a useful technique for diagnosis. But CT is not recommended during pregnancy.

References

1. Hecman JD, Sassard R. Musculo-skeletal considerations in pregnancy. *J Bone Joint Surg* 1994;76:1720-30.
2. Burgos AA, Royo P, Diaz L, Aquerreta JD. Labor-related sacral and pubic fractures: a case report. *J Bone Joint Surg* 2007;89:396-98.
3. Hoang TA, Nguyen TH, Daffner RH, Lupetin AR, Deeb ZL. Case report 491: stress fracture of the right sacrum. *Skeletal Radiol.* 1998;17:364-7.
4. Khovidhunkit W, Epstein S. Osteoporosis in pregnancy. *Osteoporos Int.* 1996;6:345-54.
5. Leroux JL, Denat B, Thomas E, Blotman F, Bonnel F. Sacral insufficiency fractures presenting as acute low-back pain. Biomechanical aspects. *Spine.* 1993;18:2502-6.
6. Rousiere M, Kahan A, Job-Deslandre C. Postpartal sacral fracture without osteoporosis. *J Bone Spine* 2001;68:71-3.
7. Schmid L, Pfirrmann C, Hess T, Schlumpf U. Bilateral fracture of the sacrum associated with pregnancy: a case report. *Osteoporos Int.* 1999;10:91-3.
8. Sibilia J, Javier RM, Werle C, Kuntz JL. Fracture of the sacrum in the absence of osteoporosis of pregnancy: a rare skeletal complication of the postpartum. *Br J Obstet Gynaecol.* 1999;106:1096-7.
9. Thienpont E, Simon JP, Fabry G. Sacral stress fracture during pregnancy- a case report. *Acta Orthop Scand.* 1999;70:525-6.
10. Blanch J, Pacifici R, Chines A. Pregnancy-associated osteoporosis: report of two cases with long-term bone density follow-up. *Br J Rheumatol.* 1994;33:269-72.
11. Breuil V, Brocq O, Eueller-Ziegler L, Grimaud A. Insufficiency fracture of the sacrum revealing a pregnancy associated osteoporosis. First case report. *Ann Rheum Dis.* 1997;56:278-9.
12. Brahme SK, Cervilla V, Vint V, Cooper K, Kortman K, Resnick D. Magnetic resonance appearance of sacral insufficiency fractures. *Skeletal Radiol.* 1990;19:489-93.
13. Berquist TH. Imaging of articular pathology: MRI, CT, arthrography. *Clin Anat.* 1997;10:1-13.

Author Information

Deniz ESKIN, MD

Orthopaedist, Department of Orthopaedics and Traumatology, Faculty of Medicine, Trakya University

Serdar MEMISOGLU, MD

Orthopaedist, Department of Orthopaedics and Traumatology, Faculty of Medicine, Trakya University

Cem COPUROGLU, MD

Assistant Professor in Orthopaedics and Traumatology, Department of Orthopaedics and Traumatology, Faculty of Medicine, Trakya University

Mert OZCAN, MD

Assistant Professor in Orthopaedics and Traumatology, Department of Orthopaedics and Traumatology, Faculty of Medicine, Trakya University