

# Carpal Bossing With Trapezium-Trapezoid Fusion: Report Of A Rare Case

B Jagannath Kamath, P Bhardwaj

## Citation

B Jagannath Kamath, P Bhardwaj. *Carpal Bossing With Trapezium-Trapezoid Fusion: Report Of A Rare Case*. The Internet Journal of Orthopedic Surgery. 2006 Volume 4 Number 2.

## Abstract

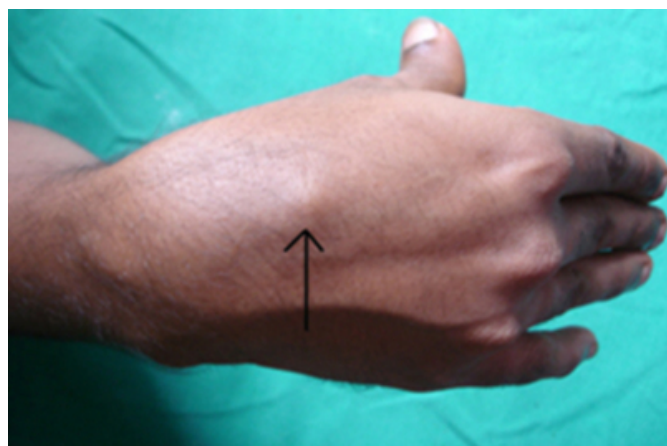
Carpal bossing is appearance of a bony and often painful mass in the region of the second and third carpometacarpal joint [1]. Its etiology is not known and its association with carpal coalition, which is an asymptomatic condition, is an interesting phenomenon, which may give a clue to its etiology. This combination is reported only once in the literature in which the coalition involved the capitate and trapezoid [1]. We report an interesting case of carpal bossing with coalition between the trapezium-trapezoid. This is the first case reporting such combination.

## CASE REPORT

A 28-yrs-old male patient presented to us with a painful bony prominence on the dorsal aspect of his dominant right hand (Fig. 1).

Figure 1: The clinical picture showing the prominence i.e. carpal bossing (Arrow).

**Figure 1**

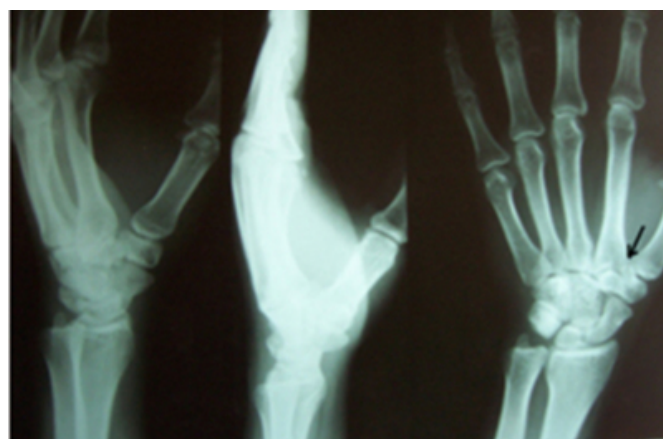


Patient noticed the swelling about 2 years back. Pain was aggravated with activities especially those requiring power grip. On examination, a bony prominence was felt just proximal to the base of the second metacarpal. Tenderness was present over the prominence. The prominence was fixed to the underlying bone. The range of movements at the wrist and the metacarpophalangeal joints were full range, but were associated with pain at extremes of movement. Clinching fist was painful. Radiographs showed, carpal bossing and

coalition between the trapezium and trapezoid. CT scan confirmed the coalition and showed that the coalition was bony and complete. The patient responded well with local injection of steroid and lignocaine and splinting for 3 weeks.

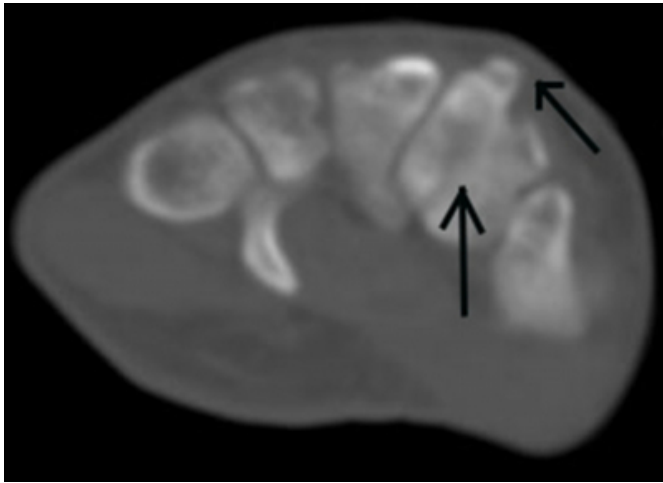
**Figure 2**

Figure 2: Radiograph showing the carpal bossing and coalition between the trapezium and trapezoid (Arrow).



### Figure 3

Figure 3: CT scan showing the complete bony coalition between the trapezium and trapezoid and the carpal bossing (Arrow).



### DISCUSSION

The carpal boss is an unmovable bony prominence on the dorsum of the hand located in the region of the second and third carpometacarpal joints, which is often painful [1,2]. It is a relatively frequent problem and is often misinterpreted as a ganglion [1]. Many reports of carpal bossing have been published since its initial description by Fiolle in 1931 [2]. The etiology of carpal bossing remains obscure. The various explanations, which have been put forward, are: presence of an accessory carpal bone (styloid bone); childhood fracture; rupture of dorsal ligament; congenital predisposition; traumatic periostitis secondary to pulling of the extensor carpi radialis brevis insertion; repeated minor trauma and physiological overgrowth of bone in response to stress factors [1].

Carpal coalition or synostosis of carpal bones usually is a chance finding in radiographs taken for unrelated reasons. It is usually congenital but may also be acquired [3]. The term is in true sense a misnomer, as it is not truly a fusion of carpal bones rather it is failure of cavitation and separation of carpal bone in the process of development of the embryo which becomes apparent only after the bones ossify [4]. The carpal fusion may occur in two or more adjacent bones. Multiple bone fusion is mainly seen as a part of various syndromes [5]. A non-syndromal fusion usually involves two bones and is more common of the two. The fusion between

the two adjacent bones is reported in almost all the combinations with lunate-triquetral being the commonest type [3]. Those on the ulnar side and occupying the same row are more commonly involved. Fusion between the trapezium and trapezoid is one of the rarest one. Fusion can be complete or incomplete, fibrous or bony [3].

Carpal coalition is mostly asymptomatic and does not interfere with the external appearance or function of the hand, but at times may cause pain and discomfort due to the alteration in the normal mechanics of the wrist and thus predisposing the surrounding joints and soft tissues to abnormal stresses [3]. Geutjens [1] in 1994 reported a case of carpal coalition causing an overgrowth of the bone in response to stress resulting in carpal bossing. This suggests that the carpal coalition is not a totally benign condition and also proves one of the proposed etiologies for carpal bossing. This is the only case in the literature reporting the coexistence of these two conditions. The coalition in their case was between the trapezoid and capitate. This is the first ever-case report of trapezium-trapezoid coalition in association with the carpal bossing. We agree with Geutjens that loss of movement between the fused bones may result in compensatory increase of movement at the joint between the synostosis and the surrounding bones and extra stress may cause carpal bossing. We believe that the bossing may result because of either stress-induced hypertrophy of the bone or because of healing of the micro-fractures resulting from the abnormally high stress.

### CORRESPONDENCE TO

Dr. B. JAGANNATH KAMATH Jyothi Mansion, Opposite Prabhat Theatre, K. S. Rao Road, Mangalore, India. Pin-575001. Phone: 91-0824-2440233; Mobile: 91-9845235747 E-mail: bjkamath@satyam.net.in

### References

1. Geutjens G. Carpal bossing with capitate-trapezoid fusion- a case report. *Acta Orthop Scand* 1994; 65(1): 97-98.
2. Lamphier TA. Carpal Bossing. *Arch. Surgery* 1960; 81: 1013-1015.
3. Singh P, Tuli A, Choudhry R, Mangal A. Intercarpal Fusion- A review. *J Anat. Soc. India* 2003; 52(2): 183-188.
4. Cockshott WP. Carpal fusion. *Am. J Roentgenol., Rad. Therapy & Nuclear Med.* 1963; 89: 1260-1271.
5. Poznanski AK, Holt JF. The carpal bones in congenital malformation syndromes. *Am. J Roentgenol., Rad. Therapy & Nuclear Med.* 1971; 112(3): 443-449.

**Author Information**

**B. Jagannath Kamath**

Associate Professor of Orthopaedics, Kasturba Medical College

**Praveen Bhardwaj**

Assistant Professor of Orthopaedics, Kasturba Medical College