

Solitary Extramedullary Plasmacytoma Of The Thyroid Gland: A Case Report And Review Of Literature

S Chaganti, R Gurunathan, E McNaboe

Citation

S Chaganti, R Gurunathan, E McNaboe. *Solitary Extramedullary Plasmacytoma Of The Thyroid Gland: A Case Report And Review Of Literature*. The Internet Journal of Head and Neck Surgery. 2006 Volume 2 Number 1.

DOI: [10.5580/15ad](https://doi.org/10.5580/15ad)

Abstract

The authors present a case of a Solitary extramedullary non mucosal plasmacytoma of the Thyroid gland in a 72 year old male who presented with an asymptomatic right thyroid lobe swelling. Histopathological examination of the operative specimen together with immunocytochemical staining confirmed the diagnosis of plasmacytoma. Haematological work up for Multiple myeloma was negative. The diagnostic criteria of solitary extramedullary plasmacytoma and its management aspects are discussed.

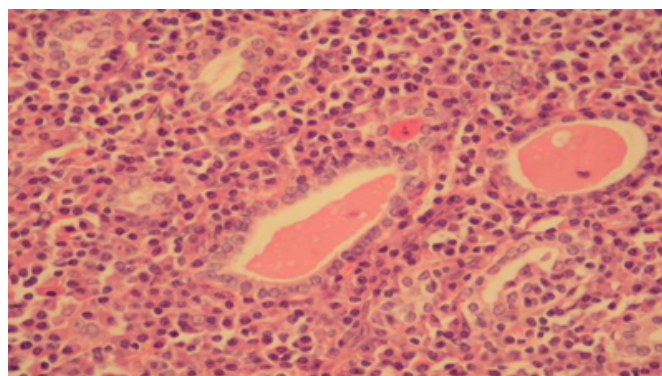
CASE REPORT

A 71 year old male presented to the outpatient ENT clinic with a 6 month history of asymptomatic, slow growing, hard nontender lump in the right lobe of thyroid gland. Clinical examination was otherwise non contributory. Past medical history included hypertension and otosclerosis. Fine needle aspiration cytology of the thyroid mass showed a diffuse infiltration of lymphocytes with a differential diagnosis of either lymphocytic thyroiditis or a lymphoma. Thyroid function tests showed evidence of sub clinical hypothyroidism and autoimmune screen showed positivity for antimicrosomal antibody. Ultrasound scan showed 3x3 cm solitary nodule on the right lobe of thyroid gland with no other abnormality. Subsequently right hemithyroidectomy was performed. Histopathological examination of specimen showed abundant desmoplastic reaction with diffuse lymphoid follicles confined to the thyroid parenchyma with no extra capsular spread. Immunocytochemical staining revealed evidence of monoclonalism of plasma cells with light chain restriction and predominant staining for kappa chains and minimal staining for lambda chain which is in favour of a diagnosis of plasmacytoma. A complete multiple myeloma workup was carried out including bone marrow biopsy, whole body CT scan, complete skeletal survey, MRI scan of thoracic lumbar spine, immunoelectrophoresis of serum and urine, urine for Bence- Jones proteins, quantitative serum immunoglobulin assay, serum biochemistry including calcium, renal function tests, and

FBC including platelet count were performed and all turned out to be negative. The only abnormality found was a moderate rise in beta 2 micro globulin which has persisted even in subsequent follow up assays. Clinical follow up for a 24 month period remained uneventful and subsequent investigations including radiology, serum and urine for para proteins remains negative.

Figure 1

Figure 1: Histopathological slide picture demonstrating Plasmacytoma of Thyroid gland



DISCUSSION

Solitary extramedullary extramucosal plasmocytomas are extremely rare and found principally in elderly people (5 – 6 th decade) with male preponderance. (3:1). They occur predominantly in head and neck region (> 90%) and account for 0.4 % of all head and neck neoplasms. (Alexiou, 1999; Dimopoulos, 1999; Galieni, 2000; Wiltshaw, 1976;

Liebross, 1999) It has a tendency to involve sub mucosal tissues of the upper aero digestive tract in majority of the patients and probably is related to long-term stimulation by inhaled irritants or viral infection. (Wiltshaw, 1976) About twenty percent of them showed spread to the regional lymph nodes and 14 to 25% had serum para protein detected while only less than 5 % had urine Bence- Jones proteins. (Knowling, 1983; Liebross, 1998) In our case neither was positive.

Solitary extramedullary plasmacytoma is a localised collection of monoclonal plasma cells. It is divided into solitary bone plasmacytoma and Solitary extramedullary plasmacytoma involving the soft tissues excluding the bone. Solitary extramedullary plasmacytoma is biologically and prognostically different from other plasma cell neoplasms. About 20 % of Solitary extramedullary plasmacytoma and >50 % of solitary bone plasmacytoma will eventually progress to multiple myeloma on long term follow up.

Histopathological analysis alone is not sufficient to make a diagnosis of Solitary extramedullary plasmacytoma as multiple myeloma has to be excluded through skeletal survey, bone marrow biopsy and serum and urine screen for para proteins. Diagnosis by fine needle aspiration needs a high index of suspicion and often the material is insufficient for immunocytochemical analysis.

Treatment for Solitary extramedullary plasmacytoma consists of eradication of the local lesion and in submucosal lesions radiotherapy is the first line of choice. Surgery remains the best modality of treatment wherever the lesion is localised and easily removable. Eg. Thyroid, salivary glands, tonsils etc.

Radiation adjunct with surgery has also been used but the role of radiotherapy after a complete excision with tumour free margins is contradictory. In our case only surgical extirpation was done and as the margins were clear, radiotherapy was not advocated.

Knowling et al in his study with 822 patients of plasma cell neoplasms found 94 % had multiple myeloma, 3% had solitary bone plasmacytoma and other 3 % had Solitary extramedullary plasmacytoma. The aetiology of Solitary extramedullary plasmacytoma is unknown and the proposed risk factors are the chronic antigenic stimuli like inhaled irritants, viral and other infections, smoking, radiation exposure and genetic predisposition. However none of these was found in our patient.

Abemayor et al recommended a FBC including a platelet count, complete serum biochemistry, bone marrow biopsy, urine examination in addition to the nuclear imaging and MRI scan has to be done as a part of multiple myeloma workup.

Batsakis has classified Solitary extramedullary plasmacytoma into 5 types based on the course of the disease after treatment.

- localised solitary lesion well controlled by surgery or radiation or both
- localised recurrent tumor controlled by additional treatment
- localised but aggressive tumour- uncontrolled persistent or recurrent
- loco-regional spread to the regional lymph nodes
- Local disease disseminated or developed into multiple myeloma.

Galieni et al have given certain diagnostic criteria for Solitary extramedullary plasmacytoma

They are

- biopsy of tissue showing monoclonal plasma cell histology
- bone marrow plasma cell infiltration < 5% of all nucleated cells
- absence of any osteolytic bone lesion
- absence of hypercalcemia or renal failure
- low serum M protein concentration if present

Our case satisfied all the criteria described above.

Wiltshaw (1976) classified soft tissue plasmacytoma into 3 clinical stages:

- Stage I - Limited to an extramedullary site
- Stage II - Involvement of regional lymph nodes
- Stage III - Multiple metastasis (although it is no longer a solitary plasmacytoma)

The therapeutic and prognostic value of this classification

needs further evaluation.

Rubin et al reviewed 40 cases of Solitary extramedullary plasmacytoma involving thyroid gland and found certain contrasting features when compared to other sites. Solitary extramedullary plasmacytoma in thyroid gland had equal sex distribution, regional lymph node involvement in 43% of tumours, 50 % of patients are found to be hypothyroid at diagnosis and 63 % of patients had chronic lymphocytic thyroiditis (Hashimoto's Thyroiditis) suggesting an autoimmune reaction. (Our case also had sub clinical hypothyroidism and FNAC suggestive of lymphocytic thyroiditis) Treatment consisted of surgery alone in 40%, surgery and radiotherapy in 44% of cases and radiotherapy alone in 14% of patients. No difference of outcome was noted between each group.

Relapse in Solitary extramedullary plasmacytoma can occur by 3 different modes .i.e. local recurrence or loco regional spread and dissemination and progression into multiple myeloma. Our patient on 24 months follow up has no relapse and is on continued follow up.

CONCLUSION

In view of extreme radio sensitivity of the Solitary extramedullary plasmacytoma treatment of first choice is radiotherapy. However if the lesion is localised and amenable to surgery, it could be the first choice since it definitely carries less morbidity to the patient both in terms of duration of treatment and the side effects. Regular follow up with monitoring of serum and urine for paraproteins and other appropriate investigations is necessary as there is a definite risk for progression to multiple myeloma in 5 to 20 % of the patients.

References

1. Bourtsos EP, Bedrossian CW, De Frias DV, Nayar R: Thyroid plasmacytoma mimicking medullary carcinoma: a potential pitfall in aspiration cytology; *Diagn Cytopathol*. 2000 Nov; 23(5):354-8.
2. Salazar JE, Nelson JF, Winer-Muram HT.:

- Extramedullary plasmacytoma of the thyroid. *Can Assoc Radiol J*. 1987 Jun;38(2):136-8.
3. Schiller VL, Gray RK, Mackey JK, Terpenning M.: Plasmacytoma of the thyroid gland, an unusual site of extraosseous multiple myeloma. *AJR Am J Roentgenol*. 1994 Sep; 163(3):751-2
 4. De Schrijver I, Smeets P.: Thyroid enlargement due to extramedullary plasmacytoma. *JBR-BTR*. 2004 Mar-Apr;87(2):73-5
 5. Alexiou C, Kau RJ, Dietzfelbinger H, et al: Extramedullary plasmacytoma: tumor occurrence and therapeutic concepts. *Cancer* 1999 Jun 1; 85(11): 2305-14
 6. Dimopoulos MA, Kiamouris C, Mouloupoulos LA: Solitary plasmacytoma of bone and extramedullary plasmacytoma. *Hematol Oncol Clin North Am* 1999 Dec; 13(6): 1249-57
 7. Galieni P, Cavo M, Avvisati G, et al: Solitary plasmacytoma of bone and extramedullary plasmacytoma: two different entities? *Ann Oncol* 1995 Sep; 6(7): 687-91
 8. Galieni P, Cavo M, Pulsoni A, et al: Clinical outcome of extramedullary plasmacytoma. *Haematologica* 2000 Jan; 85(1): 47-51
 9. Liebross RH, Ha CS, Cox JD, et al: Clinical course of solitary extramedullary plasmacytoma. *Radiother Oncol* 1999 Sep; 52(3): 245-9
 10. Wiltshaw E: The natural history of extramedullary plasmacytoma and its relation to solitary myeloma of bone and myelomatosis. *Medicine (Baltimore)* 1976 May; 55(3): 217-38
 11. Liebross RH, Ha CS, Cox JD, et al: Clinical course of solitary extramedullary plasmacytoma. *Radiother Oncol* 1999 Sep; 52(3): 245-9
 12. Knowling MA, Harwood AR, Bergsagel DE: Comparison of extramedullary plasmacytomas with solitary and multiple plasma cell tumors of bone. *J Clin Oncol* 1983 Apr; 1(4): 255-62
 13. Abemayor E, Canalis RF, Greenberg P, Wortham DG, Rowland JP, Sun NC. Plasma cell tumors of the head and neck. *J Otolaryngology* 1988, 17:376-381.
 14. Batsakis JG, Fries GT, Goldman RT, Karlseberg RC. Upper respiratory tract plasmacytoma. *Arch Otolaryngol* 1964, 79:613-618
 15. Batsakis JG. Plasma cell tumors of the head and neck. *Ann Otol Rhinol Laryngol* 1992, 92:311-313
 16. Rubin J, Johnson JT, Killeen R, Barnes L. Extramedullary plasmacytoma of the thyroid associated with a serum monoclonal gammopathy. *Arch Otolaryngol* 1990, 116:855-859
 17. Galieni P, Cavo M, Avvisati G, et al: Solitary plasmacytoma of bone and extramedullary plasmacytoma: two different entities? *Ann Oncol* 1995 Sep; 6(7): 687-91
 18. Galieni P, Cavo M, Pulsoni A, et al: Clinical outcome of extramedullary plasmacytoma. *Haematologica* 2000 Jan; 85(1): 47-51

Author Information

S. Chaganti

Craigavon Area Hospital

R. K. Gurunathan

Craigavon Area Hospital

E.J. McNaboe

Craigavon Area Hospital