

# Steroid Responsive Nephrotic Syndrome in IgA Nephropathy With FSGS

K Lau, N Delos Santos, M Hastings, B Ault, L Gaber, R Wyatt

## Citation

K Lau, N Delos Santos, M Hastings, B Ault, L Gaber, R Wyatt. *Steroid Responsive Nephrotic Syndrome in IgA Nephropathy With FSGS*. The Internet Journal of Nephrology. 2007 Volume 4 Number 2.

## Abstract

IgA nephropathy (IgAN) and focal segmental glomerulosclerosis (FSGS) are common chronic glomerulopathies that are usually not responsive to corticosteroids treatment. We describe a young African-American patient with nephrotic syndrome, whose renal biopsy showed mesangial IgA deposition and focal segmental sclerosis. Her clinical course resembles minimal change disease.

## INTRODUCTION

Both IgAN and FSGS are commonly seen chronic glomerulopathy in children.<sup>1,2,3</sup> Nephrotic syndrome is the most frequent presenting manifestation in children with FSGS, but is not a common presenting feature in pediatric IgAN. Response to steroids is usually unsatisfactory in both conditions. We describe a young African-American child presenting with nephrotic syndrome associated with IgA nephropathy and histology of FSGS who showed a clinical course of steroid responsiveness resembling those with minimal change disease.

## CASE

A 9-year-old African-American girl presented with facial and bilateral ankle swelling of three weeks duration. She denied any recent episodes of sore throat or skin infection. Systemic reviews did not show any skin rash, joint symptom or gastrointestinal problem. History of discoloration of urine was absent. There was no history of recent travel. There was no known allergy and all of her immunizations were up to date. Family history was unremarkable.

Initial physical examination showed a non-febrile young child with a weight of 36.8 kg (90<sup>th</sup> percentile) and a height of 145 cm (95<sup>th</sup> percentile). Blood pressure was normal at 115/65 mmHg. Systemic examination showed mild pitting edema of both ankles. No rash or joint swelling was found. Chest and abdominal examinations were normal. Her hemoglobin was 14.6 g/dl, platelet count was  $338 \times 10^3/\text{mm}^3$  and erythrocyte sedimentation rate was 60 mm/h. Serum creatinine was 0.4 mg/dl and serum albumin was 2.4 g/dl.

Cholesterol was 307 mg/dl. Hepatitis B surface antigen and hepatitis C virus antibody were negative, anti-streptolysin O titre was less than 14 IU/ml (0 – 200 IU/ml), serum C3 concentration was 172 mg/dl (90 – 180 mg/dl) and C4 was 31.4 mg/dl (10 – 40 mg/dl). Anti-nuclear antibody was negative. Urinalysis showed a specific gravity of 1.015 with 2+ protein and 1 + blood by dipstick. No casts or dysmorphic red blood cells were documented. Urine protein to creatinine ratio was 1.43. The urine culture was negative. A diagnosis of idiopathic nephrotic syndrome was made and she was discharged home after beginning prednisone at 60 mg/m<sup>2</sup>/day (2 mg/kg/day).

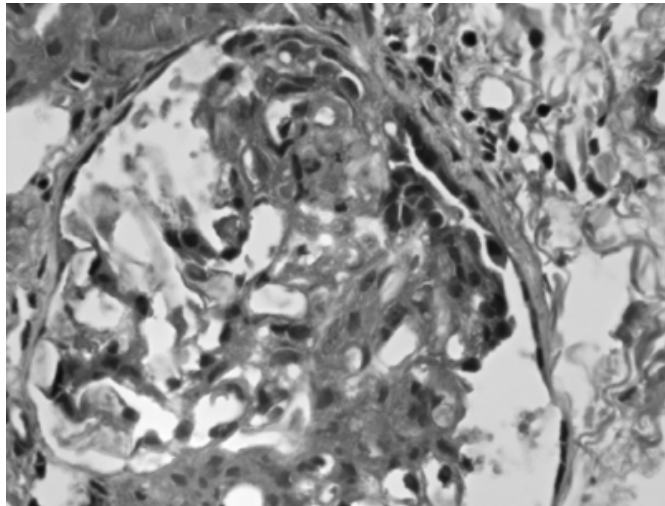
After eight weeks of prednisone, she did not achieve a complete remission and was admitted again for renal biopsy. She gained 8.6 kg and had a moderately Cushingoid appearance. Her blood pressure was 128/66 mmHg. Her serum creatinine was 0.7 mg/dl and serum albumin was 3.3 g/dl. Urine protein to creatinine ratio was 1.4.

The biopsy consisted of renal cortex with 15 glomeruli per section. Mild to severe mesangial proliferations were present in most of the glomeruli seen. The glomeruli with severe mesangial proliferation appeared to have proliferations extended to the capillary loops as well. Two glomeruli displayed features of segmental sclerosis with increased matrix, capillary loop sclerosis, capsular adhesion and a mild degree of podocyte hypertrophy (Fig. 1). Otherwise, there was no interstitial fibrosis. The histology is compatible with FSGS not otherwise specified (NOS).<sup>4</sup> Immunofluorescence staining showed 3+ (3 out of 4) of both IgA and IgM in mesangium, trace amount of C1q, and staining for IgG, C3

and properdin were negative. The pathology was compatible both IgAN and primary FSGS.

## Figure 1

Figure 1: A glomerulus with features of segmental sclerosis. (Trichrome stain; original magnification X 630)

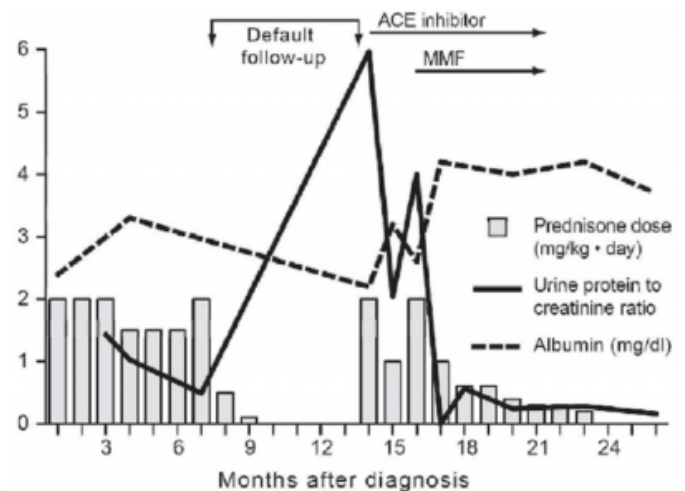


She was continued on daily oral prednisone with a tapering schedule with the addition of the angiotensin converting enzyme inhibitor (ACE inhibitor), lisinopril at 10 mg per day. Her proteinuria decreased gradually. At 4 months after the biopsy, the urine protein to creatinine ratio was 0.49. She was lost to follow up and not seen until almost 1 year after the biopsy. Her mother reported that she had taken no medication for 3 months. Her weight and height were 50.6 kg and 153 cm respectively. Urinalysis now showed a specific gravity of 1.020 with 4+ protein and negative blood. Serum creatinine and albumin were 0.4 mg/dl and 2.2 g/dl, respectively. A random urine protein to creatinine ratio was 6.0. Treatment with prednisone and lisinopril was reinstituted. When she came back for follow up 4 weeks later, her proteinuria improved to 1+ by dipstick. Serum creatinine was 0.5 mg/dl, and her albumin had increased to 3.3 g/dl. Urine protein to creatinine ratio was 2.04. The dosage of steroid was decreased accordingly to a tapering schedule. However, after her dose was dropped to 40 mg/m<sup>2</sup>/every other day (0.625 mg/kg/day), her proteinuria increased at her follow up about 1 month later. She had a 3+ proteinuria and the urine protein to creatinine ratio increased to 4.0. Her serum albumin dropped to 2.6 g/dl. Prednisone dosage was increased back to 60 mg/m<sup>2</sup>/day. She was followed up again after 4 weeks and her proteinuria had completely resolved with the urine protein to creatinine ratio dropping to less than 0.1 and serum albumin increasing to 4.2 g/dl. Her response to treatment at this juncture was

typical for steroid sensitive nephrotic syndrome. Prednisone was tapered again to an alternate day regimen and mycophenolate mofetil was started. At her last follow up, she was in remission; albeit she had again self discontinued all of her medicines including the MMF and lisinopril for more than 3 months. Fig. 2 depicts the clinical course of the patient.

## Figure 2

Figure 2: The laboratory values and prednisone dose of the patient from diagnosis to last follow-up. ACE inhibitor = angiotensin converting enzyme inhibitor; MMF = mycophenolate mofetil



## DISCUSSION

IgA nephropathy is the most frequent form of chronic glomerulonephritis in children and adolescents.<sup>3,5</sup> Clinical manifestations including hematuria and variable degrees of proteinuria are commonly seen at presentation. In a recent study from Memphis, Tennessee, 59% of African-Americans and 25% of Caucasians patients with IgA nephropathy had initial presentations with heavy proteinuria (more than 3 gm/1.73m<sup>2</sup>/day).<sup>6</sup> Although proteinuria is a common presenting feature, nephrotic syndrome at time onset occurred in only 2 to 10% of children with IgA nephropathy from the United States<sup>7,8</sup> and Yoshikawa et al. found only 12% of their patients had acute nephritic/ nephrotic syndrome at presentation.<sup>9</sup> On the other hand, the histology of our patient was also compatible with the diagnosis of FSGS. The prevalence of FSGS is increasing particularly in African-Americans<sup>3</sup> and is about 2 to 4 times<sup>10,11</sup> that of the Caucasians. Contrast to IgA nephropathy, 90% of children with primary FSGS present with nephrotic syndrome<sup>12</sup> and the presence of nephrotic range of proteinuria has been associated with a poor outcome with 50% of patients reached ESRD over 6 to 8 years.<sup>12</sup> Since spontaneous

remissions occur in less than 6% of patients,<sup>13</sup> despite a lack of level one evidence from randomized controlled trials; therapy is strongly recommended based on lower levels of evidence.<sup>14</sup> In an early study among 80 nephrotic adults with FSGS, complete remission was achieved in 40% of the 53 patients treated with steroid only.<sup>15</sup> Similarly, in another retrospective study on 51 adult patients with FSGS and nephrotic syndrome, steroid therapy alone was followed by remission in 62.5% of patients.<sup>16</sup> Although Cattran et al reported a 47% complete remission with high dose prednisone in their pediatric patients,<sup>17</sup> most studies show that only about 20% of children with FSGS will achieve remission after an 8-week course of daily corticosteroids.<sup>18,19</sup> As shown in Fig. 2, our patient not only responded to the steroid therapy rapidly with relative short course of oral corticosteroids, her clinical course resembled those with minimal change disease. She had a relapse when she self-discontinued her medicine, but she reclaimed her remission status rapidly after the steroid was restarted. Since patients with IgA nephropathy and nephrotic syndrome are rarely sensitive to steroid therapy, it is possible that our patient had a steroid sensitive nephrotic syndrome with FSGS, and the IgA deposits were just a coincidental concurrence. The presence of mesangial IgA deposit as an incidental finding in the general population was first proposed by Sinniah.<sup>20</sup> His study described that predominant IgA mesangial deposition was found in 4% of non-IgA patients in 200 consecutive necropsies. In the same year, Mustonen described the first case of steroid responsive idiopathic nephrotic syndrome in a patient with IgA nephropathy.<sup>21</sup> Since then, there had been increasing disputes of whether steroid responsive nephrotic syndrome in IgA nephropathy represents coincidence or a different clinical entity. There were several other case reports of patients with steroid responsive nephrotic syndrome with biopsy proven IgA nephropathy and minimal change histology.<sup>22,23,24,25,26,27,28,29,30,31</sup> And in a study from Korea, 16.8% of the 363 patients with minimal change diseases were found to mesangial IgA deposits.<sup>29</sup> In spite of patients with minimal change steroid sensitive nephrotic syndromes, associated with mesangial IgA deposits, had been observed to have easy relapsing course,<sup>24</sup> whether the presence of IgA deposition entails a relapsing course or not is still unknown. On the other hand, IgA deposits in sclerotic areas of glomerulus in patients with nephrotic syndrome and FSGS are not rare, albeit inconstant and usually weak in intensity.<sup>32</sup> Fofi et al. also described an adult patient with ulcerative colitis, who developed nephrotic syndrome, his renal biopsy showed FSGS histology with mesangial IgA

deposits.<sup>33</sup> The patient showed rapid response to steroid. Like our patient, whether some or all of these previous cases of IgA deposits and minimal change were just coincidence rather than being a distinct disease entity remains unknown. The dispute will likely continue until a diagnostic test for IgA nephropathy becomes clinically available. One of the tests that may be available in the near future is the lectin-binding test for galactose-deficient IgA1.<sup>34</sup> Although steroid therapy alone has been successful in some patients with nephrotic syndrome due to FSGS, nevertheless, similar experience in patients with nephrotic syndrome and IgA nephropathy with a histological picture of FSGS is lacking. Level 1 randomized controlled trial that used combined intravenous and oral steroid was only available for adult patients with IgA nephropathy,<sup>35,36</sup> which showed a significantly better 10-year renal survival and improvements in proteinuria, a similar level of study in treatment of IgAN and FSGS, especially in pediatric patients, is not available.<sup>37</sup> However, based on a lower level of evidence, oral steroids are still recommended in both adult and pediatric patients with IgA nephropathy having heavy proteinuria and FSGS.<sup>37,38,39,40,41,42,43,44</sup> Cyclosporin A has been reported to induce remission in some patients.<sup>35</sup> We recommended treatment of our patient with MMF, but as was likely in her early course, adherence to treatment protocol is questionable. And a randomized trial of the advantage of MMF in patients with IgA nephropathy is underway;<sup>45</sup> but for pediatric patients will not be clear until this and other trials are completed.

## CONCLUSION

Although steroids are generally not helpful in patients with either IgA nephropathy or FSGS, we have a patient with nephrotic syndrome with IgA nephropathy and FSGS histology who had a dramatic response to oral steroids. Further investigation is required in order to delineate whether steroid responsive IgAN should be considered as a distinct disease entity.

## CORRESPONDENCE TO

Keith K. Lau Department of Pediatrics 2516 Stockton Blvd.  
Sacramento, CA 95817 U.S.A. Tel: (916) 734 8118 Fax:  
(916) 734 0629 E-mail: keith.lau@ucdmc.ucdavis.edu

## References

1. Yoshikawa N, Tanaka R, Iijima K. Pathophysiology and treatment of IgA nephropathy in children. *Pediatr Nephrol* 2001;16:444-57.
2. Delos Santos NM, Wyatt RJ. Pediatric IgA nephropathies: clinical aspects and therapeutic approaches. *Semin Nephrol* 2004;24:269-86.
3. Bonilla-Felix M, Parra C, Dajani T, Ferris M, Swinford

- RD, Portman RJ. et al. Changing patterns in the histopathology of idiopathic nephrotic syndrome in children. *Kidney Int* 1999;55:1885-90.
4. D'Agati VD, Fogo AB, Bruijn JA, Jennette JC. Pathologic classification of focal segmental glomerulosclerosis: a working proposal. *Am J Kidney Dis*. 2004;43:368-82.
5. Yoshikawa N, Iijima K, Ito H. IgA nephropathy in children. *Nephron* 1999;83:1-12.
6. Lau KK, Gaber LW, Delos Santos NM, Fisher KA, Grimes SJ, Wyatt RJ. Pediatric IgA nephropathy: clinical features at presentation and outcome for African-Americans and Caucasians. *Clin Nephrol* 2004;62:167-72.
7. Southwest Pediatric Nephrology Study Group. A multicenter study of IgA nephropathy in children. *Kidney International* 1982;22:643-52.
8. Wyatt RJ, Kritchewsky SB, Woodford SY, Miller PM, Roy S 3rd, Holland NH, et al. IgA nephropathy: long-term prognosis for pediatric patients. *J Ped* 1995;127:913-9.
9. Yoshikawa N, Iijima K, Ito H. IgA nephropathy in children. *Nephron* 1999;83:1-12.
10. Ingulli E, Tejani A. Racial differences in the incidence and renal outcome of idiopathic focal segmental glomerulosclerosis with nephritic syndrome in children. *Ped Nephrol* 1991;5:393-7.
11. Kitiyikara C, Kopp JB, Eggers P. Trends in the epidemiology of focal segmental glomerulosclerosis. *Sem Nephrol* 2003;23:172-82.
12. Korbet SM, Schwartz MM, Lewis EJ. Primary focal segmental glomerulosclerosis: clinical course and response to therapy. *Am J Kidney Dis* 1994;23:773-83.
13. Korbet SM. Clinical picture and outcome of primary focal segmental glomerulosclerosis. *Nephrol Dial Transplant (Suppl)* 1999;14:68-73.
14. Banfi G, Moriggi M, Sabadini E, Fellin G, D'Amico G, Ponticelli C. The impact of prolonged immunosuppression on the outcome of idiopathic focal-segmental glomerulosclerosis with nephrotic syndrome in adults. A collaborative retrospective study. *Clin Nephrol* 1991;36:53-9.
15. Ponticelli C, Villa M, Banfi G, Cesana B, Pozzi C, Pani A, Passerini P, Farina M, Grassi C, Baroli A. Can prolonged treatment improve the prognosis in adults with focal segmental glomerulosclerosis? *Am J Kidney Dis*. 1999;34:618-25.
16. Goumenos DS, Tsagalis G, El Nahas AM, Shortland JR, Davlouros P, Vlachojannis JG, Brown CB. Immunosuppressive treatment of idiopathic focal segmental glomerulosclerosis: a five-year follow-up study. *Nephron Clin Pract*. 2006;104:c75-82.
17. Cattran DC, Rao P. Long-term outcome in children and adults with classic focal segmental glomerulosclerosis. *Am J Kidney Dis* 1998;32:72-9.
18. Eddy AA, Symons JM. Nephrotic syndrome in childhood. *Lancet* 2003;362:629-39.
19. Burgess E. Management of focal segmental glomerulosclerosis: evidence-based recommendations. *Kid Int (Suppl)* 1999;70:S26-32.
20. Sinniah R. Occurrence of mesangial IgA and IgM deposits in a control necropsy population. *J Clin Pathol* 1983;36:276-9.
21. Mustonen J, Pasternack A, Rantala I. The nephrotic syndrome in IgA glomerulonephritis: response to corticosteroid therapy. *Clin Nephrol* 1983;20:172-6.
22. Furuse A, Hiramatsu M, Adachi N, Karashima S, Hattori S, Matsuda I. Dramatic response to corticosteroid therapy of nephrotic syndrome associated with IgA nephropathy. *Int J Pediatr Nephrol* 1985;6:205-8.
23. Sinnassamy P, O'Regan S. Mesangial IgA deposits with steroid responsive nephrotic syndrome: probable minimal lesion nephrosis. *Am J Kidney Dis* 1985;5:267-9.
24. Barbiano di Belgiojoso G, Mazzucco G, Casanova S, Radaelli L, Monga G, Minetti L. Steroid-sensitive nephrotic syndrome with mesangial IgA deposits: a separate entity? Observation of two cases. *Am J Nephrol*. 1986;6:141-5.
25. Lai KN, Lai FM, Chan KW, Ho CP, Leung AC, Vallance-Owen J. An overlapping syndrome of IgA nephropathy and lipoid nephrosis. *Am J Clin Pathol* 1986;86:716-23.
26. Laurent J, Rostoker G, Belghiti D, Lagrue G. A case of adult steroid responsive nephrotic syndrome with IgA deposition; the significance of a concomittant allergic state. *Clin Nephrol* 1987;28:49-50.
27. Rambaek M, Waldherr R, Rauterberg W, Andrassy K, Ritz E. Mesangial IgA nephropathy and idiopathic nephrotic syndrome. *Nephron* 1987;47:190-3.
28. Cheng IK, Chan KW, Chan MK. Mesangial IgA nephropathy with steroid-responsive nephrotic syndrome: disappearance of mesangial IgA deposits following steroid-induced remission. *Am J Kidney Dis* 1989;14:361-4.
29. Choi J, Jeong HJ, Lee HY, Kim PK, Lee JS, Han DS. Significance of mesangial IgA deposition in minimal change nephrotic syndrome: a study of 60 cases. *1990;31:258-63*.
30. Rostoker G, Belghiti D, Maadi AB, Lang P, Lagrue G, Weil B. Disappearance of IgA mesangial deposits in nephrotic patients after steroid-induced remission. *Am J Kidney Dis* 1990;16:171-2.
31. Pritchard NR, Milford DV, O'Donoghue DJ. Cyclosporin A therapy in frequently relapsing nephrotic syndrome and IgA nephropathy. *Nephrol Dial Transplant* 1997;12:2402-4.
32. Olsen JL. The nephrotic syndrome. Chapter XII In: Heptinstall RH, ed. *Pathology of the kidney*. 4th Edition. Little, Brown and Company. Boston/Toronto/London, 1992; Volume 2: p 824.
33. Fofi C, Nicoletti MC, Onetti Muda A, Giulio S. Focal segmental glomerulosclerosis with IgA deposits in a patient with ulcerative colitis. *G Ital Nefrol*. 2003;20:641-4.
34. Lau K, Wyatt R, Moldoveanu Z, Tomana M, Julian B, Hogg R, Lee J, Huang WQ, Mestecky J, Novak J. Serum levels of galactose-deficient IgA in children with IgA nephropathy and Henoch-Schoenlein purpura. *Ped Nephrol* 2007;22:2067-72.
35. Pozzi C, Bolasco PG, Fogazzi GB, Andrulli S, Altieri P, Ponticelli C, et al. Corticosteroids in IgA nephropathy: a randomised controlled trial. *Lancet* 1999;353:883-7.
36. Pozzi C, Andrulli S, Del Vecchio L, Melis P, Fogazzi GB, Altieri P, et al. Corticosteroid effectiveness in IgA nephropathy: long-term results of a randomized, controlled trial. Corticosteroid effectiveness in IgA nephropathy: long-term results of a randomized, controlled trial. *J Am Soc Nephrol* 2004;15:157-63.
37. Wyatt RJ, Hogg RJ. Evidence-based assessment of treatment options for children with IgA nephropathies. *Pediatr Nephrol* 2001;16:156-67.
38. Hogg RJ. A randomized, placebo-controlled, multicenter trial evaluating alternate-day prednisone and fish oil supplements in young patients with immunoglobulin A nephropathy. Scientific Planning Committee of the IgA nephropathy study. *Am J Kidney Dis* 1995;26:792-6.
39. Nolin L, Courteau M. Management of IgA nephropathy: evidence-based recommendations. *Kidney Int (Suppl)* 1999;70:S56-62.
40. Yoshikawa N, Ito H, Sakai T, Takekoshi Y, Honda M, Awazu M, et al. A controlled trial of combined therapy for newly diagnosed severe childhood IgA nephropathy. The Japanese Pediatric IgA Nephropathy Treatment Study

Group. J Am Soc Nephrol 1999;10:101-9.

42. Katafuchi R, Ikeda K, Mizumasa T, Tanaka H, Ando T, Yanase T, et al. Controlled, prospective trial of steroid treatment in IgA nephropathy: a limitation of low-dose prednisolone therapy. Am J Kidney Dis 2003;41:972-83.

43. Evidence suggesting under-treatment in adults with idiopathic focal segmental glomerulosclerosis. Am J Med 1987;82:938-44.

44. Focal segmental glomerular sclerosis in adults:

presentation, course and response to treatment. Am J Kidney Dis 1995;25:534-42.

45. Focal segmental glomerulosclerosis with idiopathic nephrotic syndrome: three types of clinical response. J Pediatr 1982;101:40-5.

46. Hogg RJ, Wyatt RJ, and Scientific Planning Committee of the North American IgA Nephropathy Study. A randomized controlled trial of mycophenolate mofetil in patients with IgA nephropathy. BMC Nephrol 2004;25:3.

**Author Information**

**Keith K. Lau, MD**

Department of Pediatrics,, University of California, Davis

**Noel M. Delos Santos, MD**

Department of Pediatrics, University of Tennessee Health Science Center

**Margaret C. Hastings, MD**

Department of Pediatrics, University of Tennessee Health Science Center

**Bettina H. Ault, MD**

Department of Pediatrics, University of Tennessee Health Science Center

**Lillian W. Gaber, MD**

Department of Pathology, University of Tennessee Health Science Center

**Robert J. Wyatt, MD, MS**

Department of Pediatrics, University of Tennessee Health Science Center