

A False Positive Lung Scan In A Middle Aged Man Due To Encasement Of Pulmonary Vasculature By Atypical Mediastinal Carinoid Tumour Demonstrated On SPECT/CT

V Caristo, R Mansberg, V Mansberg, L Emmet, H Van der Wall

Citation

V Caristo, R Mansberg, V Mansberg, L Emmet, H Van der Wall. *A False Positive Lung Scan In A Middle Aged Man Due To Encasement Of Pulmonary Vasculature By Atypical Mediastinal Carinoid Tumour Demonstrated On SPECT/CT*. The Internet Journal of Nuclear Medicine. 2006 Volume 3 Number 2.

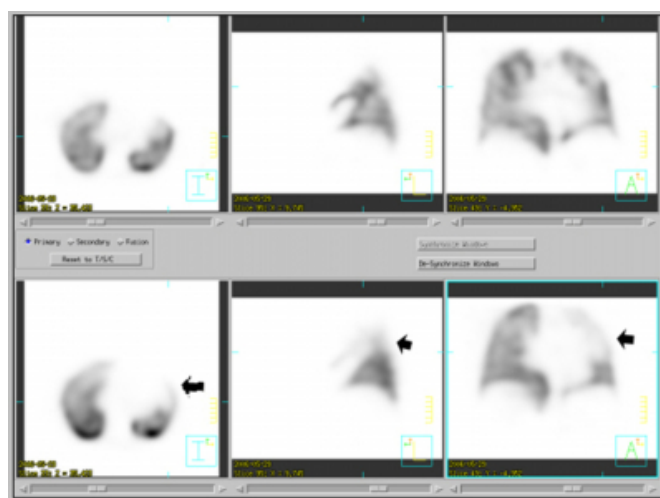Abstract

Encasement of the arterial pulmonary vascular bed is a recognized, albeit uncommon, cause for false positive results in ventilation/perfusion imaging. We present a case of a 49 year-old man with a history of atypical mediastinal carcinoid tumour of unknown primary who had a false positive ventilation/perfusion lung scan, which was shown by C.T. P.A. (computed tomographic pulmonary angiogram) to be due to selective encasement of the pulmonary vessels. The accurate diagnosis prevented inappropriate anticoagulation and the patient was managed symptomatically.

CASE REPORT

A 49 year old man was referred for a lung scan for investigation of rising right ventricular pressures on echocardiography. He was asymptomatic. Tomographic ventilation and perfusion images were obtained after inhalation of ^{99m}Tc Technegas and injection of ^{99m}Tc MAA with CT attenuation correction on a Phillips Precedence camera. Ventilation images demonstrated normal tracer distribution to both lungs. Perfusion images demonstrated reduced perfusion to both upper lobes and the apical segment of the left lower lobe with normal perfusion elsewhere (Fig 1).

Figure 1

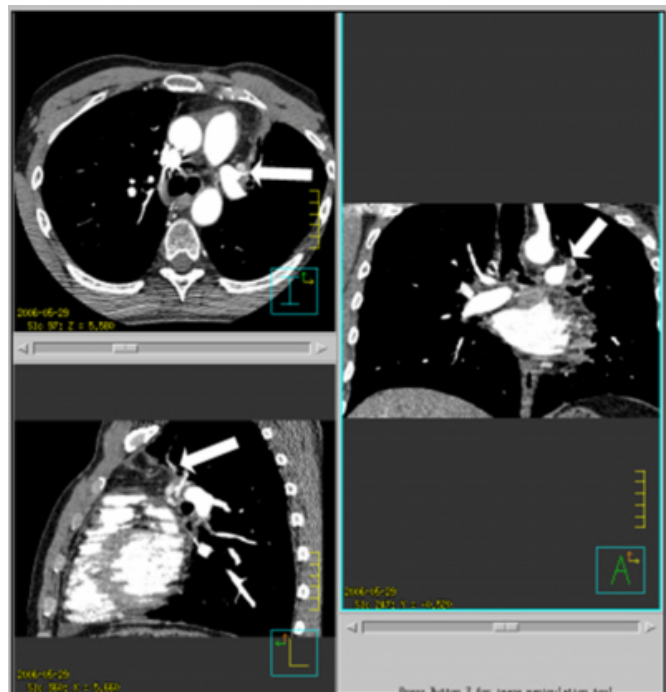


The study was reported as a high probability study for pulmonary embolism, although the lobar distribution raised the suspicion of a false positive result, and consequently a C.T. P.A. was performed.

The C.T. P.A. revealed a widespread mediastinal soft tissue mass corresponding to the known atypical mediastinal carcinoid tumour. The soft tissue mass resulted in some extrinsic compression on the origin of the right pulmonary artery which had a stent in situ. There was also mild/moderate extrinsic compression of the origin of the left pulmonary artery with some extrinsic compression of the origin of the left superior pulmonary artery. The mass also

extended inferiorly to extrinsically compress the left atrium, and the origin of the superior left pulmonary vein was markedly narrowed and was encased by tumour (Fig 2).

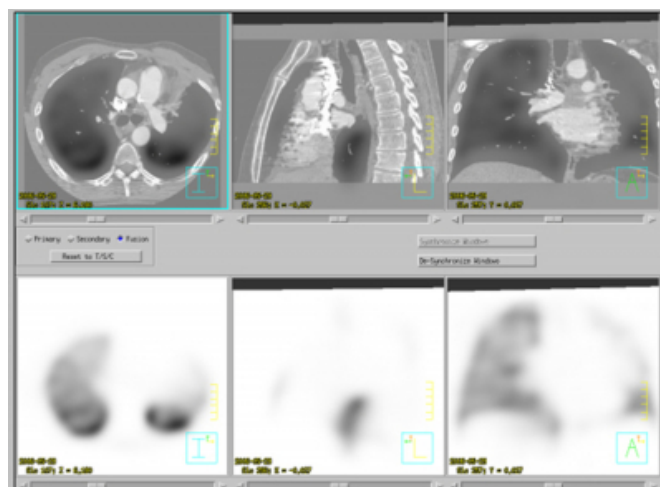
Figure 2



A displaced stent was noted within the inferior right pulmonary artery, and there was good flow of contrast to distal vessels in this region. Enhancing lymph nodes were noted adjacent to the aortic arch and in a subcarinal location. The lungs were clear.

The SPECT/CT fusion imaging demonstrates that the perfusion defects correspond to the areas of vascular encasement by the mediastinal tumour (Fig 3).

Figure 3



The patient's elevated right ventricular pressures on echocardiography were therefore attributed to progressively increased vascular resistance in the central pulmonary arterial bed that also resulted in the S.P.E.C.T. findings. False positive lung scan findings have been previously reported from acquired extrinsic and intrinsic causes such as benign and malignant tumours^{1,2,3,4,5,6,7} congenital causes such as vascular atresia^{8,9}. The development of hybrid SPECT/CT cameras will allow further characterization of false positive lung scans and aid in correct diagnosis and avoidance of unnecessary treatment.

CORRESPONDENCE TO

Dr Robert Mansberg, Department of Nuclear Medicine, Concord Repatriation General Hospital, Concord, NSW 2139, Australia. Tel: +61 2 9767 6339 Fax: +61 2 9767 5376 Email: mansberg@mail.usyd.edu.au

References

1. Delany SG, Doyle TC, Bunton RW, Hung NA, Joblin LU, Taylor DR. Pulmonary artery sarcoma mimicking pulmonary embolism. Chest 1993; 103:1631-1633.
2. Veatch MD, Lewin JM, O'Brien RF, Crausman RS. Small cell carcinoma as the cause for a nondiagnostic V/Q lung scan. Am J Emerg Med 1996; 14:183-185.
3. Gandhi V, Shapiro JM. Unilateral absent pulmonary perfusion due to bronchogenic carcinoma. South Med J 1998; 91:392-394.
4. Cei M, Mumoli N, Mariotti F, Pardelli R. The importance of clinical suspicion in diagnosing pulmonary embolism: a case of false-positive high probability radionuclide perfusion lung scan. Eur J Emerg Med. 2004 Aug;11(4):234-6.
5. Palevsky HI, Cone L, Alavi A. A case of "false-positive" high probability ventilation-perfusion lung scan due to tuberculous mediastinal

adenopathy with a discussion of other causes of "false-positive" high probability ventilation-perfusion lung scans. J Nucl Med. 1991 Mar;32(3):512-7.

6. Bateman NT, Croft DN.

False-positive lung scans and radiotherapy.

Br Med J. 1976 Apr 3;1(6013):807-8.

7. Hammoud D, Chin B.

False-positive ventilation-perfusion scan in a patient with a transplanted lung.

Clin Nucl Med. 2003 Jun;28(6):472-5.

8. Yapar AF, Aydin M, Kilic D, Reyhan M, Tercan F, Sukan A.

Ventilation-perfusion mismatch resulting from an aberrant systemic arterial supply to basal segments of the right lung. Clin Nucl Med. 2005 Jul;30(7):521-2.

9. Mansberg R, Wong CL, Drivas I.

A false-positive lung scan in an elderly man resulting from congenital absence of the right pulmonary artery.

Clin Nucl Med. 2004 Oct;29(10):659-61.

Author Information

V. Caristo, MBBS FRANCR

Department of Nuclear Medicine, Concord Repatriation General Hospital

R. Mansberg, MBBS FRACP

Department of Nuclear Medicine, Concord Repatriation General Hospital

V. Mansberg, MBBS FRANCR

Department of Nuclear Medicine, Concord Repatriation General Hospital

L. Emmet, MBBCh FRACP

Department of Nuclear Medicine, Concord Repatriation General Hospital

H. Van der Wall, MBBS PhD FRACP

Department of Nuclear Medicine, Concord Repatriation General Hospital