

Metastatic Melanoma: A Case of Unknown Site of Primary Origin

A Tak

Citation

A Tak. *Metastatic Melanoma: A Case of Unknown Site of Primary Origin*. The Internet Journal of Gastroenterology. 2005 Volume 4 Number 2.

Abstract

The small bowel is the commonest site of metastasis from melanoma. Other sites for metastases are stomach, esophagus, rectum and colon. Metastatic melanoma to colon is found in 22-28% of patients at autopsy. (1, 2) Initial signs and symptoms of colonic metastatic melanoma include bowel obstruction, gastrointestinal bleeding or a palpable mass. We describe an interesting case of extensive metastatic melanoma in a 72 year old, elderly white male with unknown site of primary origin, with brief history of abdominal discomfort who died within few weeks of diagnosis.

BACKGROUND

Malignant melanoma represents 1-3% of cancers in the United States. (1) Melanoma originates from melanocytes, which are derived from neural crest. The neural crest migrates during embryologic development and may be found in non-cutaneous sites, with predisposition to the possibility of developing melanoma in adult life.

About 7500 patients die from malignant melanoma in the United States each year. Malignant melanoma is the most common tumor to metastasize to gastrointestinal tract. The incidence of gastrointestinal metastasis from melanoma found in various studies has been around 68% liver, 58% small bowel, 22% colon, 20% stomach, 12% duodenum, 5% rectum and 1% anus. (3, 4)

CASE REPORT

A 72-year-old white male with history of hypertension presented to his primary care provider with vague abdominal discomfort of one month's duration. Over the course of this month he had lost about 20 pounds and his appetite had significantly gone down. The patient had no history of nausea or vomiting. He had no diarrhea or constipation and had noticed no rectal bleeding or melena. Physical examination was remarkable for a left axillary lymph node 2.5 x 2.5 cm and left inguinal lymph node 7 cm in size. Abdominal examination was unremarkable but stool was positive for occult blood. CBC revealed mild normocytic anemia. He had a high LDH level, high globulin level and thrombocytosis. Hepatic function tests were otherwise

normal. Patient had a normal EGD and the colonoscopy revealed three polyp like lesions in the transverse colon each about 2.5cm to 3cm in size. Interestingly these lesions appeared amelanotic and had no pigmentation on gross examination. Histopathology of these lesions came back as metastatic melanoma. S-100 staining was strongly positive and HMB-45 focally positive.

At this point patient was carefully examined for any cutaneous melanoma lesions but none was found. Patient denied any type of skin lesion in the past. CT of the chest revealed left axillary and mediastinal adenopathy. CT of abdomen and pelvis revealed normal liver, spleen, kidney and pancreas but extensive retroperitoneal, periaortic and mesenteric lymphadenopathy. CT of the left lower extremity showed 4.5 cm mass in the femoral triangle. Patient agreed to the excision of these two lesions. The histology revealed metastatic melanoma almost completely replacing the lymph nodes. Treatment options were discussed with the patient and he declined to have any further intervention. The patient died within 8 weeks of initial presentation.

Figure 1

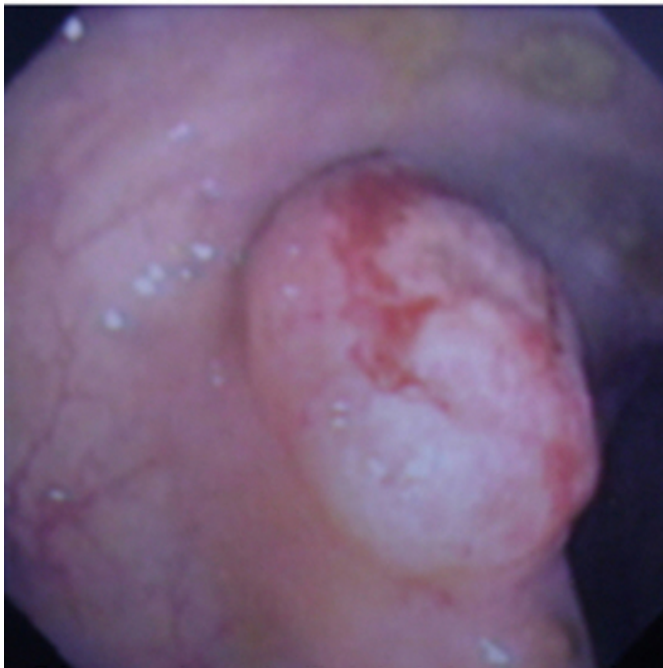


Figure 2

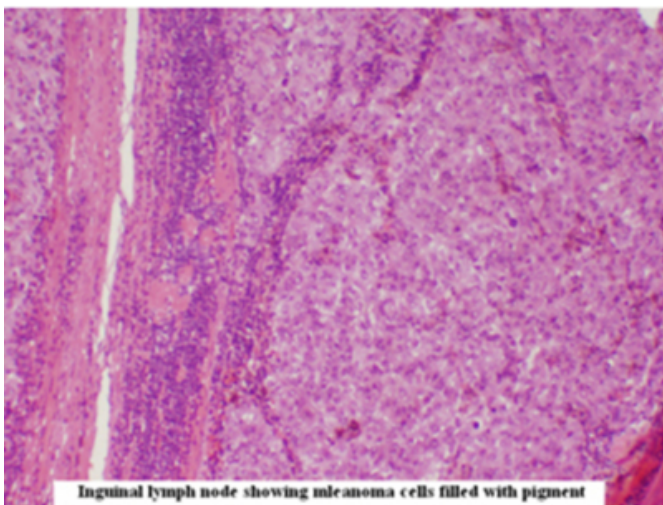


Figure 3

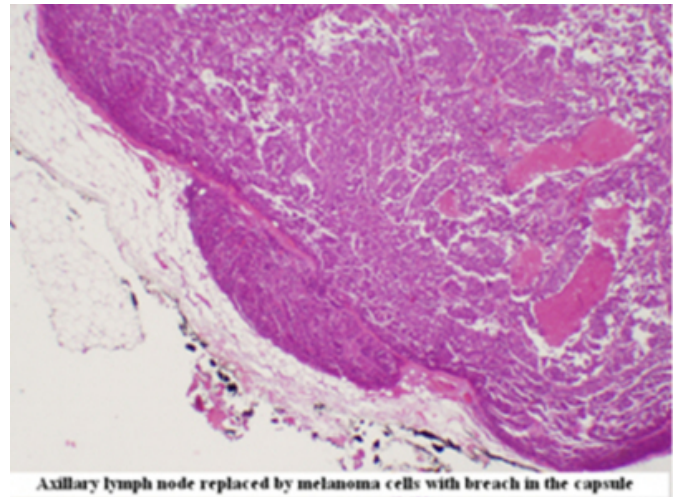
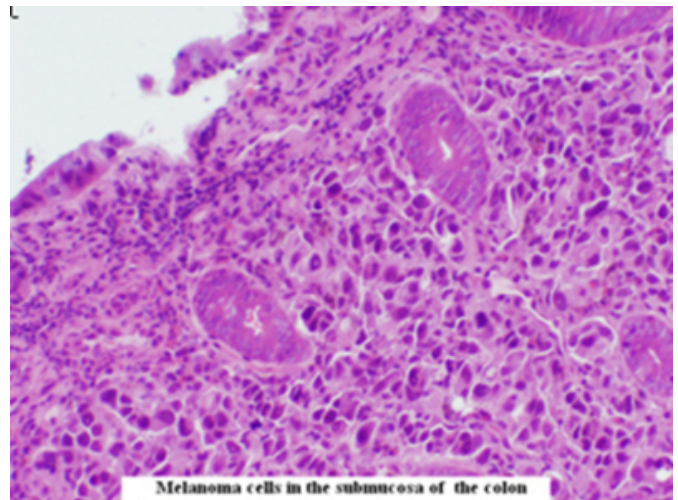


Figure 4



DISCUSSION

When melanoma is found in gastrointestinal tract, a primary cutaneous lesion is nearly always documented. (2) Metastatic melanoma should be suspected in any patient with a history of melanoma who develops abdominal pain, nausea, vomiting, distension, diarrhea, melena or anemia. Symptomatic primary melanoma of the colon is rare, with some authors arguing that the primary site of the disease was either missed or regressed spontaneously (5, 6), as 20% of patients had no history of melanoma and do not have a primary lesion at the time of presentation with metastatic disease. (7) Our case illustrates and probably fits into a case of regressed primary with metastasis to colon and lymph nodes. Since majority of melanomas are diagnosed below 50 years of age, it is hard to justify gastrointestinal screening by endoscopy without gastrointestinal symptoms. But as melanoma most commonly metastasizes to gastrointestinal

tract and about 22% metastasize to colon, a colonoscopy even without any gastrointestinal symptoms would be beneficial for an early diagnosis and a favorable outcome. At endoscopy all lesions or polyps must be biopsied with the concern for melanoma in mind, as they may appear as simple polyps and even amelanotic. This case illustrates the importance of late and unusual presentation of extensive malignant melanoma. We stress the need for periodic gastrointestinal endoscopy in any patient with history of melanoma given the fact that micrometastases to the gastrointestinal tract may have occurred at the initial diagnosis.

References

1. Das Gupta TK, Brasfield RD; Metastatic melanoma of the gastrointestinal tract. Arch Surgery 1964; 88: 969-73
2. Alsayed AM, Albahara M et al. Malignant Melanomas in the small intestine; A study of 103 patients. Am J Gastroenterol 1996; 91:1001-6
3. Adam YG. Cutaneous malignant melanoma: Current views on pathogenesis, diagnosis and surgical management. Surgery 183;93481-494
4. McClnathan JH. Long term survival after resection of metastatic melanoma of colon. Dis Colon Rectum 2000;43: 431-2
5. Poggi SH, Madison JF et al. Colonic Melanoma, primary or regressed primary. J clin Gastroenterol 2000; 30: 441-4
6. Baab GH, McBride CM. Malignant Melanoma: The patient with unknown site of primary origin. Arch Surg 1975; 110: 896-900
7. Tassier DJ et al. Melanoma metastatic to colon. Diseases of the colon and rectum; 2003 Apr ; 46(4) : 441-7

Author Information

Abdul Momin Tak, M.D.

Department of Internal Medicine, Brooks Memorial Hospital