

# Sclerosis Of Large Renal Cyst With Improved Hypertension: Case Report

R Anitha, T Wayne, R Rajnikanth, B Hari

## Citation

R Anitha, T Wayne, R Rajnikanth, B Hari. *Sclerosis Of Large Renal Cyst With Improved Hypertension: Case Report*. The Internet Journal of Nephrology. 2005 Volume 3 Number 2.

## Abstract

Simple renal cysts are often incidental findings on Ultrasound and CT scans. They are generally asymptomatic, and rarely present with flank pain, hypertension, infection, hematuria or erythrocytosis. We present a case of 64 year old woman with a large right renal cyst associated with moderately controlled hypertension and managed on multiple medications. The cyst was treated by CT guided percutaneous aspiration and alcohol sclerosis, resulting in well controlled blood pressure on less medicine. Utilization of cyst aspiration in this manner may avoid unnecessary surgical interventions. We found only two cases in the literature [3,4] that show the same course when applied to treatment of hypertension. Our case is a third example.

## INTRODUCTION

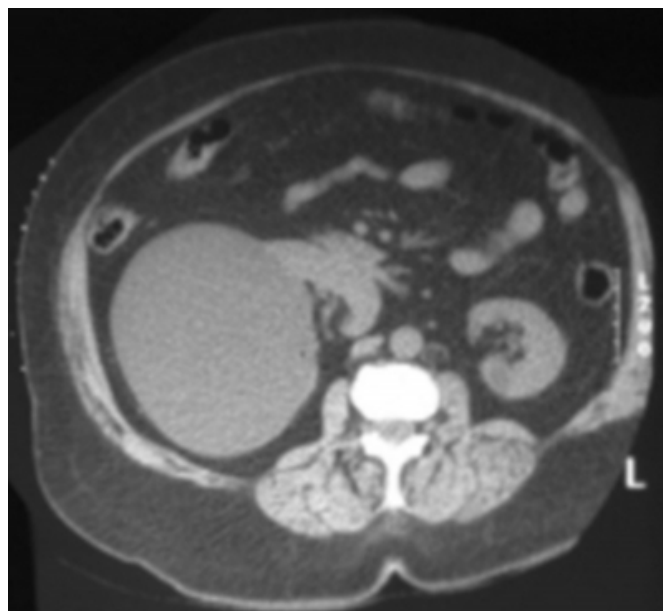
Simple renal cysts are often incidental findings on Ultrasound and CT scans. They are generally asymptomatic, and rarely present with flank pain, hypertension, infection, hematuria or erythrocytosis. We present a case of 64 year old woman with a large right renal cyst associated with moderately controlled hypertension and managed on multiple medications. The cyst was treated by CT guided percutaneous aspiration and alcohol sclerosis, resulting in well controlled blood pressure on less medicine. Utilization of cyst aspiration in this manner may avoid unnecessary surgical interventions. We found only two cases in the literature [3,4] that show the same course when applied to treatment of hypertension. Our case is a third example.

## CASE REPORT

A 64 year old white female presented for evaluation of moderately controlled hypertension. At the time of presentation, the patient was managed on multiple antihypertensives, which included atenolol 32 mg daily, spiroolactone 50 mg daily, bisoprolol/HCTZ (Ziac) 10/6.25 mg daily, methyl dopa 250 mg twice a day, doxazosin 2 mg daily and a catapres TTS 2 patch every week. Her blood pressure ranged between 152-158 mm Hg systolic and 84-90 mm Hg diastolic on these medications. She had a history of right renal cyst, which was an incidental finding on previous CT scan of her abdomen. Physical examination of the patient was normal. She had normal blood work including complete blood count, electrolytes, urinalysis, urinary catecholamines,

VMA and metanephrines. MRA of the renal arteries was normal but confirmed the presence of a large right kidney cortical cyst measuring approximately 13 cm and causing anteromedial displacement of the right kidney (Fig 1).

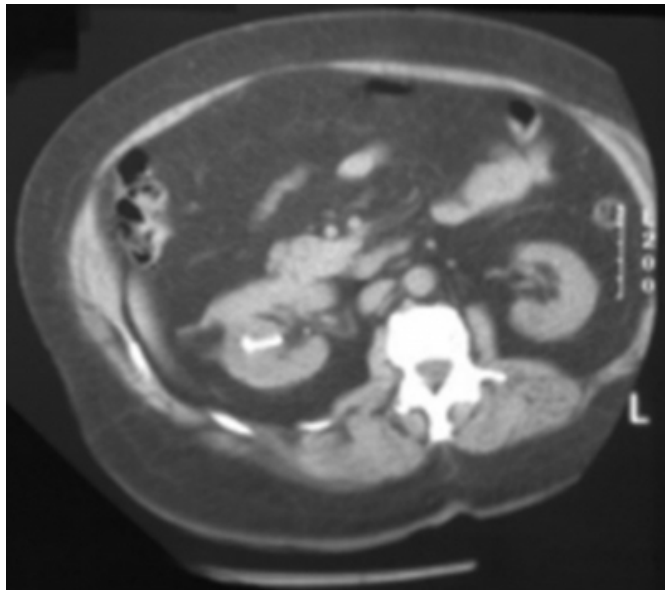
Figure 1



Stimulated plasma renin came back high as 11.9 ng/ml/hr (Normal 1.31-3.95). The patient then went to CT scan guided aspiration of the right renal cyst. A total of 800 ccs of clear fluid was drained. Later, contrast was injected demonstrating no communication between the cyst and the collecting system. Finally, the cyst was sclerosed with 95%

ethanol. The cyst reduced in size significantly (Fig 2).

**Figure 2**



A week after aspiration of the cyst, the blood pressure dropped to 120/62 mm Hg. Pathology of the cystic fluid showed no malignant cells. After the procedure, the patient has been followed every six months for past four years. She is currently only on a single antihypertensive medication Hyzaar 100/25 mg daily. Her blood pressure has been well controlled and is around 136/80 mm Hg. Her last ultrasound demonstrated resolution of the original cyst. Her recent stimulated plasma renin is 2.01 ng/ml/hr.

### DISCUSSION

The incidence of simple renal cysts increases with age. They are found in one third of patients, fifty years of age or older [1]. As a cause, their association with hypertension is rare. Large cysts cause ischemia by compressing the adjacent renal tissue and /or renal arteries, thereby stimulating the renin-angiotensin- aldosterone system, resulting in hypertension [2]. Surgical removal or percutaneous decompression of the cyst has shown to improve the blood pressure in these patients [3,4,5,6,7,8,9,10,11,12,13,14,15,16,17]. Renal cysts can be managed by percutaneous aspiration with [3,4] or without [12,13,14,15,16] injection of sclerosing agents, marsupialisation [17] and laparoscopic/open surgery [5,6,7,8,9,10,11].

Percutaneous aspiration of the renal cyst and injection of a sclerosing agent has been studied in the literature and has shown to deliver better results in terms of symptom control and recurrence of the cyst. Aspiration alone has the

disadvantage of a high recurrence rate [26,27,28,29]. Sclerosing agents cause inflammation and fibrosis of the cyst wall, thereby shrinking and preventing recurrence of the cyst. Different sclerosing agents like alcohol [3,4,18,19,20,21,22,23,24,25,26,27,28,29], minocycline [31], tetracycline [32], vibramycin [3] and polidocanol [30] have been used, all with good success. In our case we choose CT guided aspiration and injection of alcohol since it is effective, minimally invasive, has fewer complications when compared to surgical methods and can be performed in an outpatient setting. It was also diagnostic and therapeutic, as the blood pressure dropped and remained easier to control after the cyst was aspirated, proving the causal relationship between renal cyst and hypertension. We chose 95% alcohol as the sclerosing agent as it is inexpensive and had shown good results with no complications in the long term [18,19,20,21,22]. We have followed the patient for four years with blood pressure measurements, and serial ultrasounds to look for the residual cyst size. There are only two case reports in literature where renal cyst with associated hypertension was managed by percutaneous cyst aspiration and instillation of the sclerosing agent alcohol, both with good results [3,4]. Our case is a third case, which lends credence to the desirability of this procedure under appropriate circumstances.

### CONCLUSIONS

In conclusion, percutaneous aspiration and alcohol sclerosis is an effective, safe and minimally invasive therapeutic option for renal cysts causing hypertension. If the blood pressure doesn't respond to aspiration of the cyst, then other causes of hypertension should be looked for.

We, therefore, suggest percutaneous cyst aspiration and sclerosis as the first line of treatment for renal cysts suspected as a cause for hypertension before proceeding to invasive surgical procedures.

### References

1. Tada S, Yamagishi J, Kobayashi H, Hata Y, Kobari T, The incidence of simple renal cyst by computed tomography. Clin Radiol 34(4), 1983, pp 437-439
2. Page I.H, The production of persistent arterial hypertension by cellophane perinephritis, JAMA, 113, 1939, pp 2046
3. Giannakopoulos X, Charalabopoulos K, Charalabopoulos A, Golias C.H., Peschos D, Sofikitis N, Giant simple renal cyst complicated with hypertension, Int J Clin Pract Suppl, (147), 2005, pp 69-71
4. Churchill D, Kimoff R, Pinsky M, Gault M.H., Solitary intrarenal cyst: correctable cause of hypertension, Urology, 6(4), 1975, pp 485-488
5. M. Lezrek, H. Fassi-Fehri, L. Badet, J.M. Marechal, X. Martin, Remission of erythrocytosis and hypertension after treatment of a giant renal cyst. Urology 60(1), 2002, pp 164

6. Adam J. Singer, Samuel K. Lee, Simple renal cysts causing loss of kidney function and hypertension, *Urology* 57(2), 2001, pp 363-364
7. Gelabert i Mas A, Alvarez-Vijande R, Cortadellas R, Gomez F, Resolution of hypertension after retroperitoneal removal of a solitary renal cyst, *Urol Int*, 38(5), 1983, pp 314-316
8. Watts R.W., Frewin D.B., Maddern J.P., High renin hypertension in association with a solitary renal cyst, *Med J Aust*, 1(4), 1982, pp 185-187
9. Rose H.J., Pruitt A.W., Hypertension, hyperreninemia and a solitary renal cyst in an adolescent, *Am J Med*, 61(4), 1976, pp 579-582
10. Hoard T.D., O'Brien D.P. 3rd, Simple renal cyst and high renin hypertension cured by cyst decompression, *J Urol*, 115(3), 1976, pp 326-327
11. Babka J.C., Cohen M.S., Sode J., Solitary intrarenal cyst causing hypertension, *N Engl J Med*, 291(7), 1974, pp 343-344
12. Pearl M, Klein S, Simple renal cyst and hypertension, *Ann Radiol*, 29(3-4), 1986, pp 421-423
13. Renders G.A., Moonen W.A., Debruyne F.M., Resolution of hypertension after percutaneous puncture of a solitary renal cyst, *Acta Urol Belg*, 47(3), 1979, pp 555-559
14. Mang H.Y., Markovic P.R., Chow S, Maruyama A, Solitary intrarenal cyst causing hypertension, with plasma renin activity study before and after cyst aspiration, *N Y State J Med*, 78(4), 1978, pp 654-656
15. Kala R, Fyhrquist F, Halttunen P, Rauste J, Solitary renal cyst, hypertension and rennin, *J Urol*, 116(6), 1976, pp 710-711
16. Rockson S.G., Stone R.A., Gunnells J.C. Jr. Solitary renal cyst with segmental ischemia and hypertension, *J Urol*, 112(5), 1974, pp 550-552
17. Johnson J.D., Radwin H.M., High renin hypertension associated with renal cortical cyst, *Urology*, 7(5), 1976, pp 508-511
18. Paananen I, Hellstrom P, Leinonen S, Merikanto J, Perala J, Paivansalo M, Lukkarinen O, Treatment of renal cysts with single-session percutaneous drainage and ethanol sclerotherapy: long-term outcome, *Urology*, 57(1), 2001, pp 30-33
19. Aboutaieb R, Joual A, Ousehal A, el Mrini M, Benjelloun S, Percutaneous alcoholization of simple serous cysts of the kidney, *Ann Urol (Paris)*, 29(5), 1995, pp 280-283
20. Nishimura K, Tsujimura A, Matsumiya K, Oka T, Takaha M, Clinical experience of percutaneous renal cyst puncture in recent six years, *Hinyokika Kyo*, 39(2), 1993, pp 121-125
21. Garcia Novio F, Rey Rego R, Mateo Cambon L, Perez Mendana P, Asorey Fernandez A, Ruiz Diaz E, Symptomatic simple cyst of the kidney. Treatment using puncture-aspiration and sclerosis with 95% ethanol, *Arch Esp Urol*, 43(3), 1990, pp 269-272
22. Bean W.J., Renal cysts: treatment with alcohol, *Radiology*, 138(2), 1981, pp 329-331
23. Gasparini D, Sponza M, Valotto C, Marzio A, Luciani L.G., Zattoni F. Renal cysts: can percutaneous ethanol injections be considered an alternative to surgery? *Urol Int*, 71(2), 2003, pp 197-200
24. Delakas D, Karyotis I, Loumbakis P, Daskalopoulos G, Charoulakis N, Cranidis A, Long-term results after percutaneous minimally invasive procedure treatment of symptomatic simple renal cysts, *Int Urol Nephrol*, 32(3), 2001, pp 321-326
25. Hanna R.M., Dahniya M.H., Aspiration and sclerotherapy of symptomatic simple renal cysts: value of two injections of a sclerosing agent, *AJR Am J Roentgenol*, 167(3), 1996, pp 781-783
26. Martino P, Annunziata G, Saracino G.A., Palazzo S, Macchia M, de Ceglie G, Ricapito V, Selvaggi F.P., Aspiration versus aspiration plus ultrasonography-guided alcohol administration for simple renal cysts: recurrence and complications, *Arch Ital Urol Androl*, 74(4), 2002, pp 216-218
27. Ba U.R., Urenkov S.B., The diagnosis and treatment of simple kidney cysts, *Urol Nefrol (Mosk)*, (3), 1996, pp 8-12
28. Zama S., Percutaneous renal cyst puncture and ethanol instillation, *Hinyokika Kyo*, 40(1), 1994, pp 9-13
29. Ozgur S, Cetin S, Ilker Y, Percutaneous renal cyst aspiration and treatment with alcohol, *Int Urol Nephrol*, 20(5), 1988, pp 481-484
30. Ohta S, Fujishiro Y, Fuse H, Polidocanol sclerotherapy for simple renal cysts, *Urol Int*, 58(3), 1997, pp 145-147
31. Ohkawa M, Tokunaga S, Orito M, Shimamura M, Hirano S, Okasho A, Kosaka S, Percutaneous injection sclerotherapy with minocycline hydrochloride for simple renal cysts, *Int Urol Nephrol*, 25(1), 1993, pp 37-43
32. Van der Ent C.K., Van Dalen A, Enterman J.H., Antibiotic sclerotherapy for renal cysts, *Rofo*, 150(3), 1989, pp 339-341

**Author Information**

**Raj Anitha, M.D.**

Department of Internal Medicine, North Shore Medical Center

**Trebbin Wayne, M.D.**

Department of Internal Medicine, North Shore Medical Center

**Ravula Rajnikanth, M.D., M.P.H.**

Department of Internal Medicine, North Shore Medical Center

**Brundavanam Hari, M.D.**

Department of Internal Medicine, North Shore Medical Center