

Sertraline Induced Hepatotoxicity: A Case Report and Review of Literature

M Brahmania, Z Schwartz, G Rosenfeld, E Yoshida

Citation

M Brahmania, Z Schwartz, G Rosenfeld, E Yoshida. *Sertraline Induced Hepatotoxicity: A Case Report and Review of Literature*. The Internet Journal of Gastroenterology. 2010 Volume 10 Number 2.

Abstract

Introduction: Depression is a common disorder amongst the general population and frequently encountered by most physicians (1). Selective Serotonin Re-Uptake Inhibitors (SSRI's) have become the most commonly prescribed antidepressants due to their superiority compared to other antidepressants in the treatment of acute major depression (2). Although exceedingly rare, hepatotoxicity resulting from Sertraline use has been previously reported (3-7). In these case reports, the liver injury pattern was predominately hepatocellular. Unlike previous cases, we report the case of a patient presenting with markedly elevated cholestatic enzymes and painless jaundice while taking Sertraline for treatment of depression. **Case Presentation:** A 61-year-old Caucasian female presented with a history of fatigue, malaise, anorexia, and painless jaundice. She had taken Sertraline 100 mg daily for one year for management of her depression. However, due to a suboptimal therapeutic response, her dose was increased to 200 mg daily three weeks prior to presentation. She was also taking hormone replacement therapy (Premarin 0.625mg daily and Prometrium 100mg daily) to control menopausal symptoms. Liver enzymes obtained at the time of admission showed an ALT of 207 U/L, AST 161 U/L, Total Bilirubin 164 umol/L, Direct Bilirubin 135 umol/L, ALP 915 U/L, and GGT 4412 U/L. Laboratory and radiological investigations were inconclusive and a liver biopsy was consistent with a drug-induced hepatitis. Our patient's symptoms and liver biochemistry improved following cessation of Sertraline therapy.

Conclusion: Heightened awareness amongst prescribing physicians is warranted for patients taking Sertraline in the treatment of depression for the development of hepatotoxicity. These effects may be compounded by patients also on hormone replacement therapy.

INTRODUCTION

Depression is a very common disorder amongst the general population and frequently encountered by most physicians. The international consortium of psychiatric epidemiology (ICPE) estimates the lifetime prevalence at 16.9% in the United States (1) and we anticipate a similar prevalence in Canada. Over the past twenty years, Selective Serotonin Re-Uptake Inhibitors (SSRI's) have become the most commonly prescribed antidepressants. Recent evidence suggests Sertraline (a SSRI) may be superior in efficacy, acceptability, and tolerability compared to other antidepressants in the treatment of acute major depression (2). Side effects of Sertraline range from nausea and vomiting, headache and tremors, to sexual dysfunction. Asymptomatic elevations of transaminases have been documented in 0.8% of patients receiving Sertraline (3). Although exceedingly rare, hepatotoxicity resulting from Sertraline use has been previously reported. A review of the literature revealed eleven prior reports of Sertraline induced hepatotoxicity presenting with a predominately

hepatocellular injury pattern or mixed obstructive and hepatocellular picture. Reported symptoms ranged from asymptomatic elevation of transaminases to fulminant hepatitis (4-7). In these case reports, the liver injury pattern was predominately hepatocellular. Unlike previous cases, we report the case of a patient presenting with markedly elevated cholestatic enzymes and painless jaundice while taking Sertraline for treatment of depression. Our patient's symptoms and liver biochemistry improved following cessation of Sertraline therapy.

CASE PRESENTATION

A 61-year-old Caucasian female presented with a history of fatigue, malaise, anorexia, and painless jaundice. She was previously healthy, aside from a diagnosis of depression and anxiety for which she had taken Sertraline 100 mg daily for one year. However, due to a suboptimal therapeutic response, her dose was increased to 200 mg daily three weeks prior to presentation. In addition, she was taking hormone replacement therapy (Premarin 0.625mg daily and

Prometrium 100mg daily) for management of her menopausal symptoms for three years. Prior screening bloodwork obtained from the family physician revealed liver enzymes within normal limits, however, liver enzymes obtained at the time of admission showed an ALT of 207 U/L, AST 161 U/L, Total Bilirubin 164 umol/L, Direct Bilirubin 135 umol/L, ALP 915 U/L, and GGT 4412 U/L. There was no prior history of alcohol or substance abuse, nor was there any family history of liver disease or risk factors for viral hepatitis. An autoimmune workup, which included anti-nuclear antibody, anti-mitochondrial antibody, anti-smooth muscle antibodies and anti-tissue transglutaminase antibodies were all negative. Ceruloplasmin and alpha-1 antitrypsin levels were normal. Screening serologies for Hepatitis A, B and C were all negative. Abdominal imaging consisted of CT, ultrasound and MRCP all of which failed to reveal any intrahepatic or extrahepatic dilatation and the liver appeared normal. A Liver biopsy was consistent cholestatic hepatitis, with bile accumulation throughout the lobules. There were no eosinophils present, nor was there any evidence of steatohepatitis or fibrosis (Figure 1, 2). The biopsy was consistent with either a viral or drug-induced hepatitis. Sertraline, Estrogen and Progesterone were discontinued upon admission however, despite minimal improvement in cholestatic enzymes, the patient was clinically stable and therefore, discharged from hospital 5 days later with close outpatient follow up. The patient resumed her hormone replacement upon discharge. Two weeks later, her liver enzymes had not improved and she had increased symptoms with more abdominal pain, nausea and drenching night sweats. She again stopped her Estrogen and Progesterone and by one month after cessation of therapy, she was improving both symptomatically and biochemically with liver enzymes being GGT 2868 U/L, ALP 679 U/L, Total Bilirubin 51 umol/L, Direct Bilirubin 45 umol/L, ALT 112 U/L, and AST 101 U/L.

Table 1: Liver enzyme pattern

Figure 1

	AST	ALT	ALP	T. Bilirubin	D. Bilirubin	GGT	LDH	INR
Admission	161	207	915	164	135	4412	170	0.9
Post Admission Day 1	177		768	134	111		164	
Day 2	230	260	829	137		3898		
Day 3	183	235	872	146		4065		
Day 4	178	243	942	152	115	3858	160	1
Day 5	183	252	964	133	102	3946	143	0.9
Day 6	180	250	946	133	105	4250	153	0.9
Discharge (Day 7)	145	210	825	110		3774		
Follow Up (Day 12)	135	200	846	126	94	4276		
Follow Up (Day 18)	69	112	722	146	113	3414		1
Follow Up (Day 25)	103	130	701	57	48	2970		
Follow Up (Day 27)	76	101	655	50	38	2813		1
Follow Up (Day 28)	101	112	679	51	45	2868		
Follow Up (Day 34)	105	102	563	37	29	2518		
Follow Up (Day 40)	93	99	436	26	20	2138		0.9
Follow Up (Day 49)	42	55	312	17	10	1427		
Follow Up (Day 82)	20	24	148	9	2	584		
Follow Up (Day 104)	24	25	148	6	2	513		
Follow Up (Day 114)	19	32	142	7	1	357	175	1
Follow Up (Day 125)	19	24	147	7	1	422		
Follow Up (Day 136)	31	50	201	2	2	522		
Follow Up (Day 140)	21	37	181	2	2	502		
Follow Up (Day 146)	44	53	217	1	1	603		
Follow Up (Day 159)	29	46	202	2	2	575		
Follow Up (Day 166)	22	40	164	2	2	440		
Follow Up (Day 185)	29	35	109	2	2	289		

Figure 2

Figure 1: An H&E stain which is demonstrating bile stasis and accumulation as well as hepatocyte degeneration and inflammatory cell accumulation, in keeping with a cholestatic liver pattern

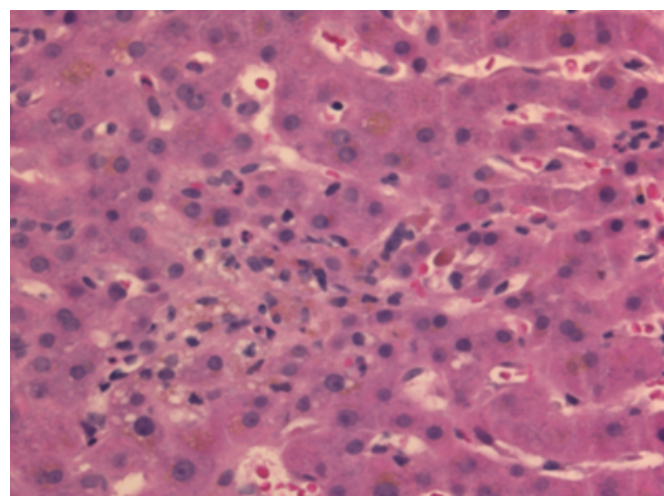
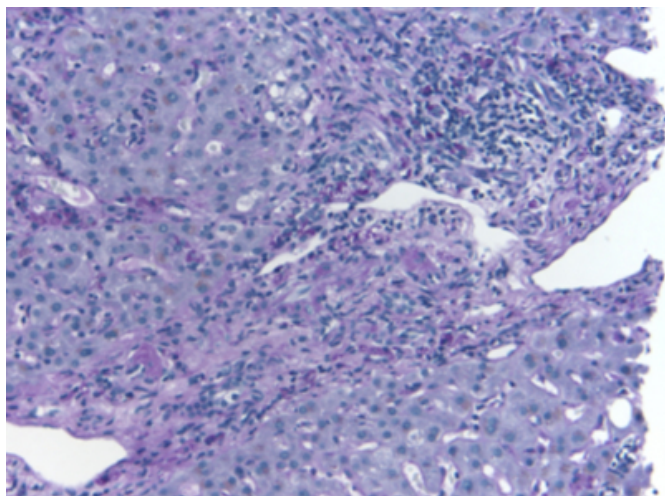


Figure 3

Figure 2: A PAS stain showing significant cellular debris within histiocytes in the portal tract and hepatic lobules. A number of inflammatory cells are also seen in this image, in keeping with hepatitis.



DISCUSSION

Our patient represents a case of severe cholestatic hepatic injury secondary to Sertraline use with a significant increase in GGT and ALP, which improved four weeks following discontinuation of therapy. While several prior case reports have documented a predominant rise in hepatocellular enzymes following initiation of Sertraline use, our patient demonstrated a primarily cholestatic pattern of liver injury. Hepatotoxicity is a rare side effect occurring in 0.8% of study patients on Sertraline. Increase in enzyme levels usually develop in the first one to nine weeks of treatment and usually respond to discontinuation of the medication (3). Eleven cases of Sertraline induced hepatotoxicity have been reported thus far ranging from asymptomatic elevation of liver transaminases to acute hepatic failure (4-7). The mechanism of Sertraline induced hepatotoxicity remains unclear. Because SSRI's inhibit the P450 2D6 enzyme system (8), they have the potential to increase the plasma concentration of other drugs metabolized by this enzyme. Prometrium is primarily metabolized by CYP 2C19 and CYP 3A4, which is a minor substrate of the 2D6 enzyme system. We postulate that an inhibition of 2D6 by Sertraline may have lead to an increase in circulating levels of Prometrium which in turn, may have contributed to the cholestatic pattern of liver injury seen in this patient. Alternatively, Sertraline is highly bound to plasma protein,

and protein-binding displacement potentially may increase free serum concentrations of other co-administered drugs such as the Estrogen or Progesterone taken by our patient resulting in steroid induced hepatotoxicity. In our case, the viral, autoimmune, and metabolic causes of liver toxicity were excluded. Radiographic imaging did not reveal any pathology and the lack of eosinophils in the liver following biopsy suggests this was not an immune related phenomenon. We believe that the rapid increase in the Sertraline dose caused the hepatic toxicity which may have been potentiated by the concomitant use of Estrogen and Progesterone for hormone replacement.

CONCLUSION

Physicians of all specialties frequently encounter patients taking SSRI's for treatment of depression and need to be aware of the potential serious and severe adverse side effect of hepatotoxicity related to the use of Sertraline. Physicians should be especially cautious when patients are taking hormone replacement therapy in conjunction with Sertraline as was illustrated by this case.

References

1. Andrade L, Caraveo-Anduaga JJ, Berglund P, Bijl RV, De Graaf R, Vollebergh W, Dragomirecka E, Kohn R, Keller M, Kessler RC, Kawakami N, Kiliç C, Offord D, Ustun TB, Wittchen HU. The epidemiology of major depressive episodes: results from the International Consortium of Psychiatric Epidemiology (ICPE) Surveys. *Int J Methods Psychiatr Res.* 2003;12(1):3-21.
2. Sertraline versus other antidepressive agents for depression. *Cochrane Database Syst Rev.* 2010 Apr 14;4:CD006117.
3. Roering Division of Pfizer, inc. Zoloft (sertraline hydrochloride) package insert. New York; October 1997.
4. Tabak F, Gunduz F, Tahan V, Tabak O, Ozaras R. Sertraline Hepatotoxicity: Report of a Case and Review of the Literature. *Dig Dis Sci.* 2009 Jul;54(7):1589-91. Epub 2008 Oct 29.
5. Collados V, Hallal H, Andrade RJ. Sertraline Hepatotoxicity: Report of a Case and Review of the Literature. *Dig Dis Sci.* 2010 Jun;55(6):1806-7.
6. Galan MV, Potts JA, Silverman AL, Gordon SC. The burden of acute nonfulminant drug-induced hepatitis in a United States tertiary referral center [corrected]. *J Clin Gastroenterol.* 2005 Feb;39(2):176.
7. Hautekeete ML, Colle I, van Vlierberghe H, Elewaut A. Symptomatic liver injury probably related to Sertraline. *Gastroenterol clin boil.* 1988;22:364.
8. Crewe HK, Lennard MS, Tucker GT, Woods FR, Haddock RE. The effect of selective serotonin re-uptake inhibitors on cytochrome P4502D6 (CYP2D6) activity in human liver microsomes. *Br J Clin Pharmacol.* 2004 Dec;58(7):S744-7;

Author Information

Mayur Brahmania, MD

Department of Medicine, Division of Gastroenterology, Vancouver General Hospital, University of British Columbia

Zachary Schwartz, MD

Department of Medicine, Division of Gastroenterology, Vancouver General Hospital, University of British Columbia

Greg Rosenfeld, MD

Department of Medicine, Division of Gastroenterology, Vancouver General Hospital, University of British Columbia

Eric Yoshida, MD

Department of Medicine, Division of Gastroenterology, Vancouver General Hospital, University of British Columbia