

Testis Sparing Surgery for Epidermoid Cyst of Testis in a 3-year-old Boy

A Ali, M Hassab

Citation

A Ali, M Hassab. *Testis Sparing Surgery for Epidermoid Cyst of Testis in a 3-year-old Boy*. The Internet Journal of Surgery. 2007 Volume 16 Number 2.

Abstract

We present a 3-year-old boy with a right testicular heterogeneous mass; testis-sparing surgery was performed based on clinical, laboratory and radiological findings and on intraoperative frozen sectioning. The aim of this report is to define the clinical criteria and complementary investigation results allowing conservative surgery for epidermoid cysts of the testis.

INTRODUCTION

An epidermoid cyst is a rare, benign tumour of the testis with no malignant potential that accounts for less than 1% of all testicular neoplasms. [1] Testis-sparing surgery is recommended as surgical treatment. [2] We present a 3-year-old boy with a testicular epidermoid cyst, who underwent testis-sparing surgery.

CASE REPORT

A 3-year-old boy presented with a 10-month history of painless right scrotal swelling which increased in size. There was no history of trauma and other systemic illness. Clinical examination revealed a non-tender, firm, nodular, right testicular mass, 2 x 2cm in diameter. The left testis was normal. Serum alpha-fetoprotein and β -human chorionic gonadotropin were within normal limits. Testicular ultrasonography revealed an 18 x 15mm heterogeneous and hypoechoic cystic mass in the lower pole of the right testis. [Fig. 1] Colour Doppler ultrasound did not show evidence of an increase in blood flow to the right testicular mass. Abdominal ultrasonography and CT were unremarkable. Through a right groin approach, the spermatic cord was isolated and occluded with a non-crushing clamp. [Fig. 2] The testis showed multiple keratinous, light yellowish materials beneath the tunica albuginea and an intratesticular cystic mass. Frozen section examination excluded malignancy.

Figure 1

Figure 1: Testicular ultrasonography revealed a well-circumscribed 18 x 15mm heterogenous and hypoechoic cystic mass in the lower pole of the right testis.

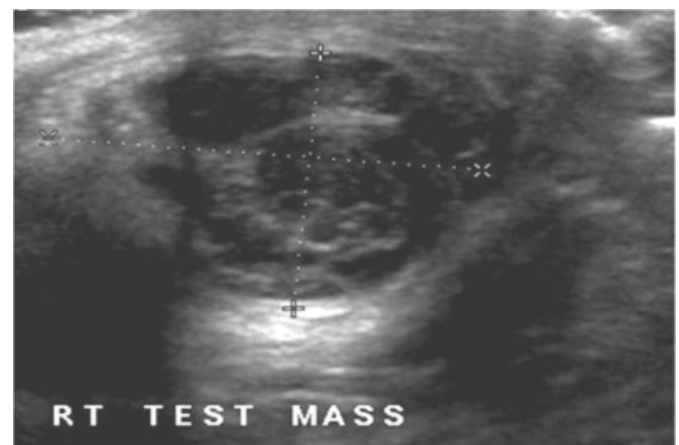
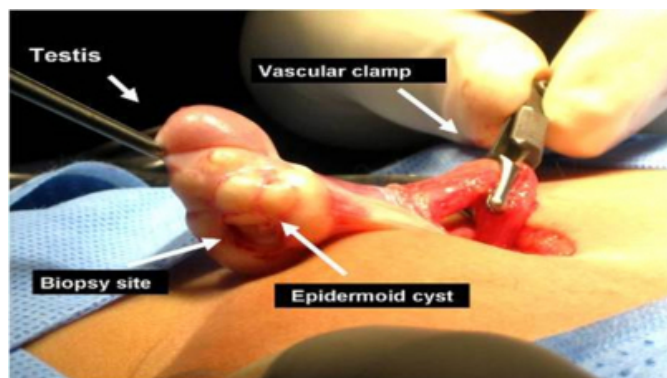


Figure 2

Figure 2: The intra-operative picture shows the multinodular testicular mass with sub-tunica yellowish keratinous material, the biopsy site and the clamping of the spermatic cord.



The testicular mass was enucleated completely, preserving the surrounding testicular tissue. Histological diagnosis was that of an epidermoid cyst of the testis. The postoperative period was uneventful.

DISCUSSION

An epidermoid cyst of the testis is defined as an intraparenchymal testicular cyst, which is filled with keratinized material and lined by squamous epithelium, but without teratomatous elements or cutaneous adnexal structures. Testicular epidermoid cysts are rare and benign tumours and their prevalence is approximately 1% of all testicular tumours. [2] Epidermoid cysts of the testis usually present as a painless nodule detected by the patient or during routine physical examination. [1]

The histogenesis of epidermoid cysts is unclear. The prevailing hypothesis is that they are of germ-cell origin, developing along the line of epidermal differentiation, as a monodermal expression of a teratoma. [2]

The ultrasonographic appearance may suggest the possibility of an epidermoid cyst; the findings include a mass with a target appearance of a central hypoechoic area surrounded by an echo-lucent rim, an onion-peel appearance of alternating rings of hyper- and hypoechogenicity and a well circumscribed mass with a hyperechoic rim. [3]

Intraoperative frozen section examination is highly sensitive and specific for differential diagnosis of benign and malignant testicular tumors. It is justified to base surgical management of testicular masses on the diagnosis of frozen section examination. [4]

For psychologic and cosmetic benefits and for preservation of fertility, organ-confining surgery should be favored by the surgeon, with frozen sectioning. [1] This approach has been recommended as the treatment of choice in prepubertal ages. [2] So we used testis-sparing surgery in our case.

In conclusion, a testicular epidermoid cyst is a rare benign tumour and it is classified as intraparenchymal testicular cyst without teratomatous elements. Based on clinical, laboratory and radiological findings and on intraoperative frozen section, organ-preserving surgery is suggested rather than orchiectomy, which is the current opinion in the literature.

References

1. Parlaktas BS, Köseoğlu RD, Uluocak, et al. Testis-sparing surgery for epidermoid cyst of testis in an infertile man. *Erciyes Medical Journal* 2005;27:75-77.
2. Somuncu S, Cakmak M, Atasoy P, et al. Testicular epidermoid cyst and organ-preserving surgery. *J Indian Assoc Pediatr Surg* 2006;11:99-100.
3. Moghe PK and Brady AP. Ultrasound of testicular epidermoid cysts. *The British Journal of Radiology* 1999;72:942-945.
4. Elert A, Olbert P, Hegele A, et al. Accuracy of frozen section examination of testicular tumors of uncertain origin. *European Urology* 2002;41:290-293

Author Information

Ali Moustafa Ali, MBBCH, MS, MD, MRCSEd

Department of Pediatric Surgery, King Fahd Medical City

Mohamed Hany Hassab, MBBCH, MS, FRCSEd

Department of Pediatric Surgery, King Fahd Medical City