

Posterior Leg Compartment Abscess Following Rupture of Infected Baker's cyst: A Complication of Intra-articular Corticosteroid Injection

L Mason, N Vannett, E Carpenter, J Davies

Citation

L Mason, N Vannett, E Carpenter, J Davies. *Posterior Leg Compartment Abscess Following Rupture of Infected Baker's cyst: A Complication of Intra-articular Corticosteroid Injection*. The Internet Journal of Orthopedic Surgery. 2007 Volume 10 Number 1.

Abstract

We report a case of a left leg posterior compartment abscess, developing from a ruptured Baker's cyst following intra-articular Depo-medrone injection into the knee. Initially the patient developed a suspected pyarthrosis following the Depomedrone injection, where *S. aureus* was grown on culture. The initial treatment with arthroscopy did not address the patients Baker's cyst which subsequently ruptured causing an abscess. The diagnosis was confirmed on an ultrasound scan and with magnetic resonance imaging. The patient was treated with incision and drainage of the abscess, which resulted in resolution of the problem over the following two months.

CASE REPORT

A 77 year old lady presented to her general practitioner with longstanding left-sided knee pain. She was known to have tricompartmental osteoarthritis which had been deteriorating clinically. Clinical examination was unremarkable and conservative treatment was instituted. Her knee was injected by her general practitioner with 80mg Depo-medrone with 1mg Lidocaine.

Over the next three days the patient began to develop increasingly severe knee pain and returned to her general practitioner unable to weight-bare. The movements of her knee had become restricted and was therefore referred to secondary care for further investigation and management.

On admission to hospital, the patient was pyrexial (38.9°C). Examination of the knee revealed a moderate effusion with swelling in the popliteal fossa. The knee was slightly warm to the touch with tenderness over the posteromedial joint line and proximal calf with a constrained range of movement (30-80°). Differential diagnosis of deep vein thrombosis was excluded with a doppler ultrasound scan. Blood tests revealed a white cell count of $12.8 \times 10^9/l$ and elevated inflammatory markers (erythrocyte sedimentation rate 115 mm in first hour and C-reactive protein >450 mg/l). Approximately 15mls was aspirated from the knee and sent for microscopy and culture. It revealed 10,000/mm³

leucocytes (90% polymorphs, 10% lymphocytes), no organisms and no crystals. There were no organisms grown on culture.

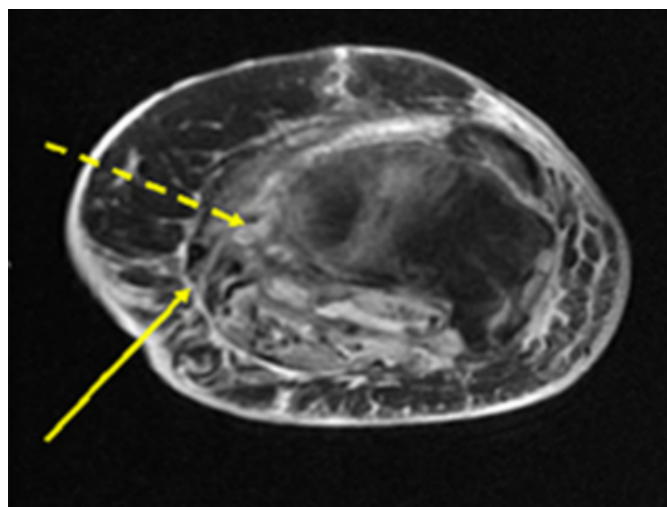
Clinical outlook necessitated the patient undergoing an urgent arthroscopic washout of her knee. This revealed a large quantity of pus like fluid, which was again sent for microscopy, culture and sensitivity along with synovial tissue. This grew *Staphylococcus aureus*, and intravenous antibiotics were instituted (Benzyl penicillin 1.2g QDS and Flucloxacillin 1g QDS). Postoperatively the patient was slow to improve clinically, with limited ability to weight-bare and a reduced range of movement.

Six days following arthroscopy the patient developed a very tender, swollen and erythematous proximal calf. The inflammatory markers had failed to settle (ESR 116 mm in first hour and CRP 206 mg/l). An ultrasound scan was organised, which revealed a 3 cm superficial abscess communicating with a deeper larger abscess in the posterior compartment of the left leg. Magnetic resonance imaging (Figure 1, 2 and 3) confirmed a loculated abscess with a superficial component overlying the medial aspect of the tibia and a deeper component superficial to the medial head of gastrocnemius. The loculi communicated via a small channel. The abscess was treated with incision and drainage and was left to heal by secondary intention over the next two

months.

Figure 1

Figure 1: Axial STIR MRI through upper tibia



A typical location for Baker's cyst running between medial head of gastrocnemius and semimembranosus tendon (solid arrow). Note unusual deep track on medial side of tibia (dashed arrow).

Figure 2

Figure 2 and 3: Axial T1 and STIR axial images of the upper tibia showing deep trilobed collection on medial aspect of proximal tibia.

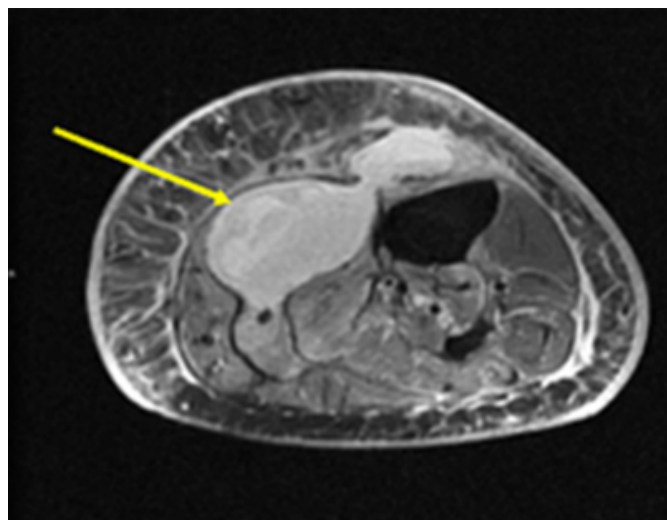
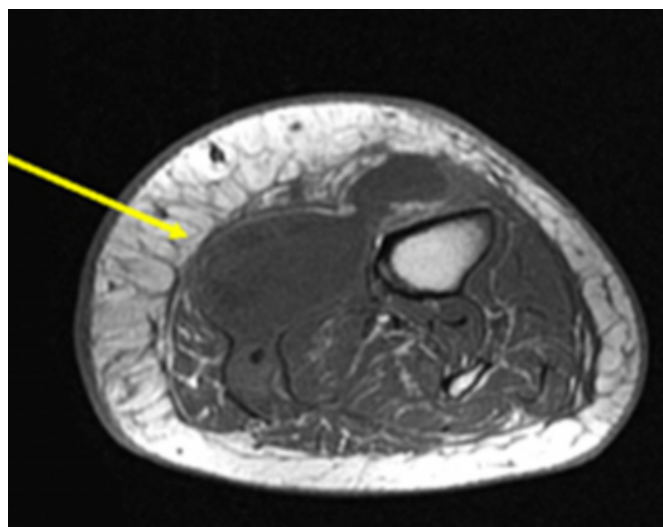


Figure 3



At 12 months follow-up she remains well with ongoing symptoms of osteoarthritis. Her inflammatory markers are now normal and she is currently awaiting total knee arthroplasty.

The appearances on the magnetic resonance scan suggest this to be a case of a pre-existing Baker's cyst that became secondarily infected as a consequence of a Depomedrone injection. It is likely that the Baker's cyst was infected at presentation, but was missed and so was not adequately treated. During arthroscopic drainage, the Baker's cyst was not dealt with and may even have encouraged cyst rupture by increasing its pressure within the cyst leading to tracking of the infection and subsequent abscess formation in the calf.

DISCUSSION

The popliteal cyst was first documented by Dupuytren in 1829 and later eponymously by Baker in 1872. Anatomically, the cyst is a distension of the gastrocnemius-semimembranosus bursae, which comprises two bursae, one anterior to the medial gastrocnemius tendon and between the tendon of gastrocnemius and semimembranosus (1). It classically occurs when there is a fluid leak through the posterior-medial joint capsule, as a consequence of knee joint effusions in association with meniscal tears, inflammatory and degenerative joint disease (1).

Intra-articular glucocorticoid injections are commonplace in the management of both symptomatic osteoarthritis of the knee and Baker's cysts (3,4). They have been shown to be both effective in the short term management of painful arthritis (5) and in reducing the size of Baker's cysts (3).

Complications are rare and are generally considered to be safe when administered by an experienced physician (6), the most common complication being sepsis (7). Septic arthritis complicating intra-articular glucocorticoid injection is between 1 in 3000 and 1 in 50,000 (0.002%) (8).

Although uncommon, to date there are approximately 20 reported cases of primary infected Baker's cysts in the literature, the majority are secondary to *Staphylococcus aureus* (8). Other detected organisms include; *mycobacterium tuberculosis*, *candida albicans* and *streptococcus pneumoniae* (8). Nevertheless, the literature does not contain any reported cases of Baker's cyst infection following intra-articular steroid injection. Most commonly the symptoms of infection usually occur 3-4 days following injection (6). Due to the anatomical connection between the Baker's cyst and the synovial cavity of the knee joint sepsis from one has a potential to spread to the other. As a result, rupture of these infected Baker's cysts can result in abscess formation (9,10).

In summary, we postulate that although the washout addressed the infection within the cavity of the knee joint, due to the continuity of the joint cavity with the cyst, the infection in the Baker's cyst remained untreated. This then ruptured and resulted in abscess formation in the calf. Although rare, this case illustrates that infection of a Baker's cyst may complicate septic arthritis leading to abscess formation which must not be overlooked.

This case illustrates two points, depomedrone injection can lead to infection of a Baker's cyst which can rupture and cause a calf abscess. Secondly, treatment of a pyarthrosis with an associated Baker's cyst needs to address the Baker's cyst, either through a separate incision or through

arthroscopy.

CORRESPONDENCE TO

Mr Lyndon Mason 2 Pantbach Avenue, Rhiwbina, Cardiff.
CF14 1UR E-mail: drlyndonmason@doctors.org.uk Tel:
07947038874

References

1. Fang CSJ, McCarthy CL, McNally EG. Intramuscular dissection of Baker's cysts: report on three cases. *Skeletal Radiology* 2004; 33: 367-371
2. Miller TT, Staron RB, Koenigsberg T, Levin TL, Feldman F. MR imaging of Baker's cysts: association with internal derangement, effusion and degenerative arthropathy. *Radiology* 1996; 201: 247-250
3. Acebes JC, Sanchez-Pernaute O, Diaz-Oca A, Herrero-Beaumont G. Ultrasonographic assessment of Baker's cysts after intra-articular corticosteroid injection in knee osteoarthritis. *Journal of Clinical Ultrasound* 2006; 34(3): 113-117
4. Schumacher HR, Chen LX. Injectable corticosteroids in treatment of arthritis of the knee. *The American Journal of Medicine* 2005; 118:1208-1214
5. Bellamy N, Campbell J, Robinson V, Gee T, Bourne R, Wells G. Intraarticular corticosteroid for treatment of osteoarthritis of the knee. *Cochrane Database of Systematic reviews* 2006, Issue 2. Art. No.: CD005328. DOI: 10.1002/14651858.CD005328.pub2
6. American College of Rheumatology Subcommittee on Rheumatoid Arthritis Guidelines. Guidelines for the management of rheumatoid arthritis: 2002 update. *Arthritis and Rheumatism* 2002; 46: 328-346.
7. Pal B, Morris J. Perceived risks of joint infection following intra-articular corticosteroid injections: a survey of rheumatologists. *Clin Rheumatol*, 1999; 18(3): 264-5.
8. Charalambous CP, Tryfounidis M, Sadiq S et al. Septic arthritis following intraarticular steroid injection of the knee: a survey of current practice regarding antiseptic technique used during intra-articular steroid injection of the knee. *Clinical Rheumatology* 2003; 22: 386-390
9. Stark RJ. Ruptured popliteal cyst and pyogenic arthritis. *BMJ (Clin Res Ed)* 1981; 282(6270): 1120-1.
10. Mannino M, Marino C, Chawla K. Ruptured pyogenic Baker's cyst. *J Natl Med Assoc* 1988; 80(9): 1018-9, 1022.

Author Information

Lyndon W. Mason, MRCS

Specialist Trainee in Trauma and Orthopaedics, Royal Glamorgan Hospital

Nicola Vannett, MRCS

Specialist Trainee Fixed Term in Trauma and Orthopaedics, Royal Glamorgan Hospital

Eleanor C. Carpenter, MRCS

Specialist Registrar in Trauma and Orthopaedics, Royal Glamorgan Hospital

Jonathan Davies, FRCS(Orth)

Consultant Surgeon in Trauma and Orthopaedics, Royal Glamorgan Hospital