

# Value Of Computerized Morphometric Analysis In Diagnosis Of Breast Lesions

B Arora, Renu, A Kakade, B Rekhi

## Citation

B Arora, Renu, A Kakade, B Rekhi. *Value Of Computerized Morphometric Analysis In Diagnosis Of Breast Lesions*. The Internet Journal of Pathology. 2006 Volume 6 Number 2.

## Abstract

Breast carcinoma cells develop significant nuclear and cytoplasmic alterations during the development of this cancer through its various stages. These alterations are the cornerstone for typing and grading various breast lesions, including carcinomas. The present study was undertaken to evaluate the role of computerized interactive morphometry (CIM) for objective analysis of cellular details by measuring parameters like mean nuclear area (MNA), mean cytoplasmic area (MCA), nuclear/cytoplasmic (N/C ratio) in 75 breast specimens including 10 cases of atypical ductal hyperplasia (ADH); 50 cases of infiltrating ductal carcinoma (IDC) and remaining 15 benign cases. MNA for benign lesions ( $24.33 \pm 0.77 \mu\text{m}^2$ ) was found to be significantly lower than in cases of ADH ( $42.21 \pm 1.84 \mu\text{m}^2$ ) ( $p < 0.05$ ). MNA was found to be significantly higher in cases of IDC, as compared to benign and atypical cases ( $p < 0.05$ ). While the values for MCA were found to be significantly higher in atypical vs benign cases, the same were not found to be significant between atypical and malignant cases. Significant differences were also obtained with N/C ratio amongst the various categories. CIM analysis can be included as a useful tool for objective assessment of various breast lesions. Among the parameters studied, MNA and N/C ratio are the most significant.

Breast carcinoma cells develop significant nuclear and cytoplasmic alterations during the development of this cancer through its various stages. These alterations are the cornerstone for typing and grading various breast lesions, including carcinomas. The present study was undertaken to evaluate the role of computerized interactive morphometry (CIM) for objective analysis of cellular details by measuring parameters like mean nuclear area (MNA), mean cytoplasmic area (MCA), nuclear/cytoplasmic (N/C ratio) in 75 breast specimens including 10 cases of atypical ductal hyperplasia (ADH); 50 cases of infiltrating ductal carcinoma (IDC) and remaining 15 benign cases. MNA for benign lesions ( $24.33 \pm 0.77 \mu\text{m}^2$ ) was found to be significantly lower than in cases of ADH ( $42.21 \pm 1.84 \mu\text{m}^2$ ) ( $p < 0.05$ ). MNA was found to be significantly higher in cases of IDC, as compared to benign and atypical cases ( $p < 0.05$ ). While the values for MCA were found to be significantly higher in atypical vs benign cases, the same were not found to be significant between atypical and malignant cases. Significant differences were also obtained with N/C ratio amongst the various categories. CIM analysis can be included as a useful tool for objective assessment of various breast lesions. Among the parameters studied, MNA and N/C ratio are the most significant.

## INTRODUCTION

Breast lesions are among the commonest biopsy specimens in surgical pathology<sup>1, 2</sup>. Carcinoma breast ranks among the most frequent female malignancies in metropolitan cities of India like Delhi, Mumbai etc.<sup>3</sup>. Several breast carcinoma cases in our country present at a locally advanced stage<sup>4</sup>. Breast cancer development reveals a train of event lesions viz. Normal breast -> ductal hyperplasia, usual type -> atypical ductal hyperplasia (ADH) -> Ductal carcinoma-In-situ (DCIS) -> invasive carcinoma -> nodal and distant metastasis<sup>5</sup>. Presence of certain breast lesions such as usual ductal hyperplasia in an otherwise benign biopsy indicates a risk of 1.6-1.9 of subsequent invasive cancer development.

Atypical ductal hyperplasia has even higher risk<sup>6,7</sup>. Hence, identification of these lesions assumes importance.

However, while dealing with breast lesions on biopsy, many times there is a morphological overlap, even though definite criteria have been established. Applications of ancillary techniques like immunohistochemistry, flow cytometry becomes imperative. Computerized interactive morphometry (CIM) forms another useful technique in providing an objective and a reproducible estimate of the various lesions<sup>8</sup>. Apart from enabling an appraisal of several parameters, CIM can also be used for automated analysis for several specimens.

The current study was aimed at analyzing the value of morphometric parameters like MNA, MCA, N/C ratio in various breast specimens including benign, atypical and malignant cases, with and without lymph node metastasis.

### MATERIAL AND METHODS

The proposed study was conducted on 75 cases of surgical breast specimens received in the Department of Pathology, Pt. B.D. Sharma Post Graduate Institute of Medical Sciences, Rohtak. The cases were categorized as follows:

**Figure 1**

1	Benign lesions	15 cases
2	Atypical lesions (ADH)	10 cases
3	Infiltrating ductal carcinoma (IDC) without lymph node metastasis	25 Cases
4	Infiltrating ductal carcinoma with lymph node metastasis	25 Cases

The routine diagnosis was made on hematoxylin and eosin (H&E) stained sections. Grading of IDC cases was done by Nottingham's modification of Richardson and Bloom's grading system<sub>10</sub>.

One representative section from every case was subjected to morphometric analysis by an independent observer to remove subjective bias. Frozen sections were excluded.

The quantitative study was done by an image analysis system. The digital images generated by a charge coupling device (CCD) video camera (Sony) linked to a Olympus microscope at a total magnification of 400X were stored on a host computer through a digital frame grabber. The processing was done by image analysis software viz. Image pro-express version 4.5 by Cyber Natics Inc. USA. This was integrated into the host computer.

A total of hundred cells were randomly selected and measured in each case. The cells of interest were identified on the screen and the contours of their nuclear and cytoplasmic profiles were traced. Inside each tracing, a semiautomatic procedure consisting of threshold based boundary detection was implemented to determine the nuclear and cytoplasmic areas.

With the help of an internal calibration, various parameters were studied like Mean nuclear area (MNA), mean cytoplasmic area (MCA) and mean N/C ratio.

### STATISTICAL ANALYSIS

Statistical analysis was carried out using SPSS system (version 14). The mean values  $\pm$  standard deviations (SD) were calculated for all the three variables including mean nuclear area (MNA), cytoplasmic area (MCA) and nucleocytoplasmic (N/C) ratio. Values for MNA and MCA followed normality of data, which was tested by graphical as well as statistical tests. One-way ANOVA (analysis of variance) was used to compare MNA and MCA among 4 categories. Posthoc comparison was done by using Dunnett C test. P value  $<0.05$  was considered as statistically significant.

N/C ratio did not follow normality of data despite log transformation. Thus, a non-parametric test i.e. Kruskal Wallis test was applied.

### RESULTS

The age of the patients selected for present study ranged from 15 to 80 years with a mean of  $43.68 \pm 14.96$  years. It was observed that maximum numbers of cases (22) were between 41-50 years of age group, forming 29.3% of the study group.

Out of 15 benign cases included in the study, 8 (32%) were of fibroadenoma, 5 cases (20%) were of fibroadenosis including epithelial hyperplasia of usual type and the remaining 2 cases (8%) were of duct ectasia.

Out of the 25 cases included in the category of infiltrating ductal carcinoma (IDC) without lymph node metastasis, 12 cases (48%) were of Grade-1, 10 cases (40%) were of Grade-2 while 3 cases (12%) were of Grade-3. Among 25 cases included in the category of IDC with lymph node metastasis, 7 cases (28%) were of Grade-1, 8 cases (32%) were of Grade-2 and 10 cases (40%) were of Grade-3.

Out of 25 cases of lymph nodes with positive metastatic deposits from infiltrating ductal carcinoma of breast studied, 7 cases (28%) were of Grade-I, 8 cases were of Grade-II forming 32% of the study group and 10 cases were of Grade-III, thereby forming 40% of the study group.

On morphometric analysis, MNA for benign, atypical and malignant cases, without and with lymph node metastasis was found to be  $24.33 \pm 0.77$ ,  $42.21 \pm 1.84$ ,  $52.17 \pm 14.87$ , and  $60.31 \pm 17.50 \mu\text{m}^2$  respectively. MCA for these various categories was found to be  $77.37 \pm 2.65$ ,  $115.85 \pm 5.43$ ,  $119.37 \pm 33.45$ , and  $138.28 \pm 40.74 \mu\text{m}^2$  respectively. N/C ratio in the categories was found to be  $0.31 \pm 0.005$  in benign

cases,  $0.36 \pm 0.003$  in cases of ADH,  $0.43 \pm 0.01$  in cases of IDC without lymph node metastasis and  $0.43 \pm 0.02 \mu\text{m}$  in cases of IDC with nodal metastasis. (Table 1), (Diagram 1), (Diagram 2).

Table 1: Comparison of mean nuclear area (MNA), mean cytoplasmic area (MCA) and mean N/C ratio in the various categories.

Figure 2

Category	No. of cases	MNA $\pm$ SD ( $\mu\text{m}^2$ )	MCA $\pm$ SD ( $\mu\text{m}^2$ )	N/C ratio $\pm$ SD
Benign Lesions	15	24.33 $\pm$ 0.77	77.37 $\pm$ 2.65	0.31 $\pm$ 0.005
Atypical Lesions	10	42.21 $\pm$ 1.84	115.85 $\pm$ 5.43	0.36 $\pm$ 0.003
Mammary tissue of IDC without lymph node metastasis	25	52.17 $\pm$ 14.87	119.37 $\pm$ 33.45	0.43 $\pm$ 0.010
Mammary tissue of IDC with lymph node metastasis	25	60.31 $\pm$ 17.50	138.28 $\pm$ 40.74	0.43 $\pm$ 0.024

Figure 3

Diagram 1: Representation of the mean nuclear area (MNA) in the various categories.

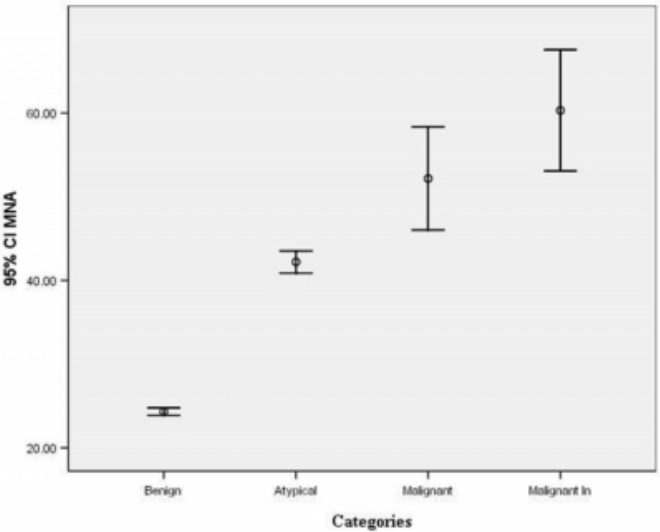


Figure 4

Diagram 2: Representation of the mean cytoplasmic area (MCA) in various categories.

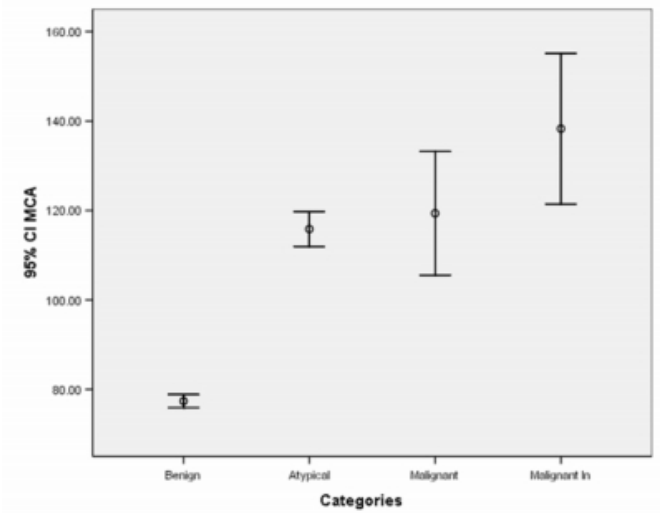
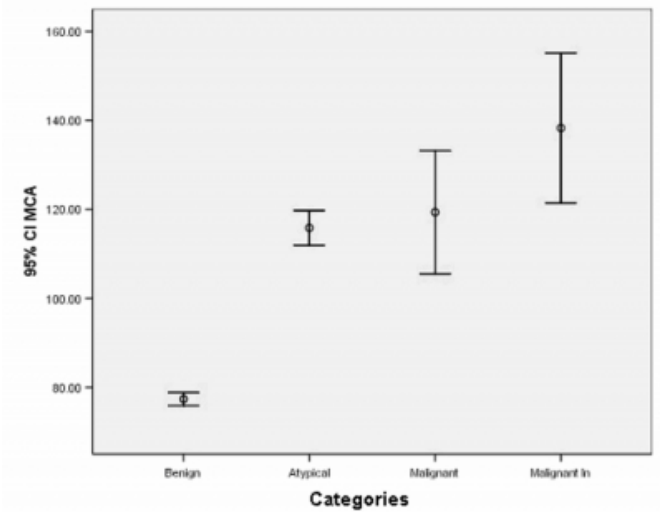


Figure 5

Diagram 3: Representation of the mean nuclear cytoplasmic ratio (N/C) in various categories.



Significant differences were observed with MNA in the various categories with lowest values in benign cases, intermediate in ADH cases, higher in IDC cases without nodal metastasis and highest in IDC cases with nodal metastasis. While significantly higher values for MCA were noted in atypical vs benign cases, the same were not found to be significant between atypical and malignant cases. Significant differences were also obtained with N/C ratio amongst the various categories ( $p < 0.05$ ).

DISCUSSION

While dealing with breast lesions in histopathology,

difficulties exist as a result of a morphologic overlap. There is considerable subjective variability in distinguishing between lesions like atypical ductal hyperplasia vs a well-differentiated low-grade DCIS<sub>8</sub>. Apart from this, predictability of certain tumor cases for metastatic potential is difficult. Nearly 30% of breast cancer cases with node negativity succumb to the disease<sub>11, 12</sub>. Morphological criteria supplemented with immunohistochemistry are available but at times their utility is limited as a result of subjective variability. Analysis of cellular measurements by CIM can be a useful adjunct in providing an objective and a more reproducible diagnosis for these lesions. A range of parameters can be evaluated like mean nuclear and cytoplasmic diameters and perimeters, MNA, MCA, N/C ratio, feret ratio, as studied by different authors in various cancers<sub>13 14, 15</sub>.

In the present study various parameters like MNA, MCA and N/C ratio were analyzed for differentiating benign vs atypical vs malignant breast cases with and without nodal metastasis.

Among the various parameters studied in the current study, MNA was found to be significantly different in various categories with lowest values in benign cases ( $24.33 \pm 0.77 \mu\text{m}^2$ ) and highest values in malignant cases having lymph node metastasis ( $60.31 \pm 17.50 \mu\text{m}^2$ ). While the observed values for malignant cases without lymph node metastasis ( $52.17 \pm 14.87$ ) were comparable to the findings of Pienta et al<sub>11</sub> (MNA= $55.30 \mu\text{m}^2$ ), the same were higher in cases of IDC with node metastasis. The values for atypical lesions ( $42.21 \pm 1.84 \mu\text{m}^2$ ) were found to be similar as observed by a manual morphometric analysis on breast lesions by Bhattacharjee et al<sub>15</sub> ( $42.50 \pm 7.32 \mu\text{m}^2$ ). In accordance with our study, these studies have observed MNA as a useful parameter for differentiating atypical lesions vs carcinoma cases. In their study, Skjorten et al<sub>16</sub> have highlighted MNA as a significant parameter in differentiating normal breast vs proliferating vs malignant breast lesions. This highlights importance of nuclear alterations as an important hallmark in development of breast cancer. In terms of malignant lesions, they found that there were no significant differences in MNA of in-situ and infiltrating carcinomas. This aspect is reflected in histopathological grading when the nuclear grade of in-situ carcinomas is observed to be similar to the adjacent foci of infiltrating ductal carcinomas. However, within the 3 grades of DCIS, MNA has been found to be increasing from grade I to grade III. In our study, the IDC cases were with or without

DCIS and the values were calculated from the cells in the IDC areas. Further, it would be worthwhile comparing MNA with the nuclear grade<sub>17</sub>. MNA has also been found to be significantly different in lobular vs ductal carcinomas<sub>16</sub>. The present study was however restricted to IDC as the included cancer subtype. Even in the spectrum of benign and proliferating lesions, MNA has been found to be useful as an objective parameter in differentiating fibroadenomas with and without atypia<sub>18</sub>.

In the current study, apart from MNA, N/C ratio was also found to be significant in differentiating benign vs atypical vs malignant cases with the lowest values in the former  $0.31 \pm 0.005$ , intermediate in the atypical group i.e.  $0.36 \pm 0.003$  and highest in the malignant category i.e.  $0.43 \pm 0.02$ .

Earlier studies<sub>8, 11, 13, 16, 17, 18, 19</sub> have indicated nuclear area as the most relevant parameter in distinguishing benign from malignant cases. However, cytoplasmic parameters like MCA help further to refine the predictive power of discriminant function. MCA was found to be useful in differentiating benign vs atypical lesions but was not found to be statistically significant in differentiating atypical vs malignant lesions.

Another observation in our study included an increase in MNA in IDC cases with lymph node metastasis vs node negative cases. There has always been a limitation to predict which IDC cases have metastatic potential. Certain invasion tumor suppressor genes have been implicated. Even though in a similar study, Pienta et al<sub>11</sub> did not observe significant differences of MNA values between node negative vs node positive cases like in our study, it can be suggested that there might be another mutation in primary lesion that could be implicated in both increase in nuclear area as well as metastatic potential.

In this way, evaluation of morphometric parameters including nuclear variables like MNA can form a useful adjunct in a more objective assessment of various breast lesions. In spite of obtaining an objective result with the help of morphometric analysis, however, errors occur due to individual and technical problems. Application of "Stepsize" algorithms can reduce technical problems in CIM in terms of overestimation of the size of the profile as a result of overriding the cytoplasmic/ nuclear contours during tracings, magnifications used, speed of conducting the analysis and the shape and size of object being traced<sub>20, 21</sub>. Internal calibration and standardization by an expert observer

performing correct tracings, as in the present study, can also reduce the errors. With the help of correct applications, CIM could form a part of an automatic screening process. A metanalysis of the various earlier studies would be useful in identifying exact values and relevance of this technique in the current pathology practice.

### References

1. Rosai J. Breast. In: Rosai J, editor. Rosai and Ackerman's Surgical Pathology. 8th ed. St. Louis: Mosby; 1996. p. 1565-8.
2. Bartow SA, Pathak DR, Black WC. Prevalence of benign, atypical and malignant breast lesions in populations at different risk for breast cancer: A forensic autopsy study. *Cancer* 1987; 60: 2751.
3. Siddiqi M, Sen U, Mondal SS; Patel DD; Yeole BB, Jussawala DJ, Pratinidhi A, Sunny L; Yeole BB, Jussawala DJ, Rao BN, Sunny L; Yeole BB, Jussawala DJ, Varsha S, Sunny L; Nair MK, Varghese C; Nair MK, Gangadharan P, Jayalakshmi P : Cancer statistics from non-ICMR registries: Population based registries, CRAB (Cancer Registry Abstract). Newsletter of the National Cancer Registry Project of India 2001, 8: 1, 47-59.
4. Ten year consolidated report of Hospital based cancer registries 1984-1993. National Cancer Registry programme. I.C.M.R. New Delhi 2001; p.88-93.
5. Van Diest PJ. Ductal carcinoma in situ in breast carcinogenesis. *J Pathol* 1999; 187: 383-4.
6. Carter CL, Corle DK, Micozzi MS, Schatzkin A, Taylor PR. A prospective study of the development of breast cancer in 16,692 women with benign breast disease. *Am J Epidemiol* 1988; 128: 467-77.
7. Dupont WD, Page DL. Risk factors for breast cancer in women with proliferative breast disease. *New Eng J Med* 1985; 312: 146-51.
8. Ruiz A, Almenar S, Callaghan RC, Llombart-Bosch A. Benign, preinvasive and invasive ductal breast lesions. A comparative study with quantitative techniques: morphometry, image- and flow cytometry. *Pathol Res Pract*. 1999; 195(11):741-6.
9. Ruiz A, Almenar S, Cerda M, Hidalgo JJ, Puchades A, Llombart Bosch A. Ductal carcinoma in situ of the Breast: A comparative analysis of histology, nuclear area, ploidy and neovascularization provides differentiation between low- and high- grade tumors. *The Breast J* 2002; 8(3): 139.
10. Frierson HF Jr, Wolber RA, Berean KW, Franquemont DW, Gafey MJ, Bojd JC, Wilbur DC. Interobserver reproducibility of the Nottingham's modification of the Bloom and Richardson histologic grading scheme for infiltrating ductal carcinoma. *Am J Clin Pathol* 1995; 103:195-198.
11. Pienta KJ, Coffey DS. Correlation of nuclear morphometry with progression of breast cancer. *Cancer* 1991; 68: 2012-6.
12. Clark GM, McGuire WL. Steroid receptors and other prognostic factors in primary breast cancer. *Semin Oncol* 1988; 15: 20-25.
13. Tan PH, Goh BB, Chiang G, Bay BH. Correlation of nuclear morphometry with pathologic parameters in ductal carcinoma in situ of the breast. *Mod Pathol*. 2001 Oct;14(10):937-41.
14. Arora B, Jain R, Kumar S, Rekhi B, Arora H, Arora DR. Morphometric analysis of AgNORs in lymph node lesions. *Adv Clin Pathol* 2002; 6: 95-99.
15. Bhattacharjee DK, Harris M, Faragher EB. Nuclear morphometry of epitheliosis and intraductal carcinoma of the breast. *Histopathol* 1985; 9: 511-6.
16. Skjorten F, Kaarsen R, Jacobsen U, Skaane P, Amlie E. Nuclear morphometry of benign and malignant breast lesions. *Eur J Surg Oncol*. 1991 Aug; 17(4):350-3.
17. Kronqvist P, Kuopio T, Jalava P, Collan Y. Morphometrical malignancy grading is a valuable prognostic factor in invasive breast cancer. *Br J Cancer* 2002; 87: 1275-1280.
18. Nijhawan R, Rajwanshi A. Cytomorphologic and morphometric limitations of the assessment of atypia in fibroadenoma of the breast. *Anal Quant Cytol Histol* 2005; 27: 273-276.
19. Paltomaa S, Lipponen P, Eskelinen M, Kosma VM, Haris S, Alhava E et al. The significance of nuclear and morphometric variables as prognostic predictors in breast cancer. *Anticancer Res* 1991; 11: 1663-70.
20. Marchevsky AM, Hauptman E, Gil J, Watson C. Computerized interactive morphometry as an aid in the diagnosis of pleural effusions. *Acta Cytol* 1987; 31 (2): 131-136.
21. Wied GL, Bibbo M, Bartels PH. Computer analysis of microscopic image: Application in cytopathology. *Pathol Annu* 1981; 16: 367-481.

**Author Information**

**B. Arora, M.D.**

Professor and Head, Dept of Pathology, P.G.I.M.S

**Renu, M.D.**

Dept of Pathology, P.G.I.M.S

**Anagha C. Kakade, MSC, DBM**

Clinical Research Secretariat, Tata Memorial Hospital

**Bharat Rekhi, MD, DNB, MIAC, MRCpath-1**

Asst Professor, Tata Memorial Hospital