

A Case Presentation and Literature Review of Successful Ketamine Administration in a Patient with Refractory Status Asthmaticus

D Galbis-Reig, M Rasansky

Citation

D Galbis-Reig, M Rasansky. *A Case Presentation and Literature Review of Successful Ketamine Administration in a Patient with Refractory Status Asthmaticus*. The Internet Journal of Internal Medicine. 2003 Volume 5 Number 1.

Abstract

Treatment options for Status Asthmaticus remain limited despite current advances in the understanding of the pathophysiology and medical management of this condition. Several anecdotal case reports and investigational studies demonstrate rapid recovery from Status Asthmaticus after infusion of ketamine hydrochloride. In this paper, the authors describe a case of successful administration of intravenous ketamine hydrochloride in a 47-year-old man with severe, refractory Status Asthmaticus and provide an extensive review of the available literature regarding the clinical experience and empiric data for ketamine administration in refractory Status Asthmaticus.

DISCLAIMER

Ketamine Hydrochloride is not approved by the Food and Drug Administration for the treatment of acute asthma exacerbations or Status Asthmaticus, epilepsy, or acute/chronic pain syndromes.

AUTHOR DISCLOSURE (S):

David Galbis-Reig, M.D. has received an Independent Investigator Grant from Pfizer, Inc. (the manufacturer of Ketalar®) to conduct research unrelated to the current brief report. (Specifically, to determine whether a relationship exists between undiagnosed, asymptomatic coronary artery disease in men over the age of 50, as determined by EBCT screening, and erectile dysfunction, as determined by responses to a validated screening tool – the IIEF-5 – developed by Pfizer, Inc.)

Dr. Galbis-Reig has also served as an independent consultant and/or received honoraria from numerous pharmaceutical companies including Aventis Pharmaceuticals, Bristol-Myers Squibb Pharmaceuticals, Cephalon, Inc., Glaxo-Wellcome, Merck Pharmaceuticals, Pfizer, Inc., and Roche Pharmaceuticals during the past five (5) years.

Dr. Galbis-Reig does not own stock or investment interest in any pharmaceutical company.

Marc A. Rasansky, M.D. - Nothing to disclose.

ABBREVIATIONS

CAS – Clinical Asthma Score
DBP – Diastolic Blood Pressure (figure 1)
DBRPC Trial – Double-Blind, Randomized, Placebo Controlled Trial (table 1)
DEA – Drug Enforcement Agency
ED – Emergency Department
FDA – Food and Drug Administration
HR – Heart Rate (figure 1)
IV – Intravenous
Kg – Kilogram (table 1)
L-NAME - N-Omega-Nitro-L-Arginine Methyl Ester
mg – Milligram (table 1)
NMDA – N-Methyl-D-Aspartic Acid
NO – Nitric Oxide
PCP – Phencyclidine
PE – Physical Exam (table 1)
PEF – Peak Expiratory Flow
SBP – Systolic Blood Pressure (figure 1)

INTRODUCTION

Science has been defined as the habit or faculty of observation... Only a quantitative difference makes observation scientific – accuracy.

Sir William Osler (1849-1919) *The Old Humanities and The New Science, in A Way of Life*, 26.

Treatment options for Status Asthmaticus remain limited

despite current advances in our understanding of the pathophysiology and medical management of this condition. Standard therapy includes beta-agonists, (both inhaled and injectable), leukotriene inhibitors, systemic and/or inhaled steroids, theophylline, and magnesium sulfate.^{1,2} In addition, use of HeliOx may be beneficial in a minority of patients,³ although meta-analysis does not show a statistically significant benefit of addition of HeliOx to standard therapy for Status Asthmaticus.⁴ Less well studied treatment options for refractory Status Asthmaticus include the use of intravenous (IV) ketamine or general inhalation anesthesia.⁵ In this paper the authors describe a case of successful administration of continuous intravenous ketamine in a 47-year-old man with Status Asthmaticus refractory to standard therapy. The authors also present an extensive review of published literature on the use of intravenous ketamine as treatment for refractory Status Asthmaticus.

CASE PRESENTATION

A 47-year-old man with a past medical history significant for chronic obstructive pulmonary disease, asthma, and major depression presented to the emergency department (ED) complaining of dyspnea and cough. He had experienced cough productive of yellow/green sputum for two days prior to admission. Over the course of the previous 24 hours, he had become increasingly dyspneic. On initial presentation, he could speak in two to three word phrases. He had no previous history of intubation and began using his albuterol inhaler prior to arriving in the ED without significant improvement. He admitted that he had continued to smoke one pack of cigarettes per day but denied drug use. He denied coryza, fevers, or chills. In addition to his albuterol inhaler, the patient was also taking azmacort, combivent, sertraline, methocarbamol, and over-the-counter advil. He had no known food or drug allergies. He reported good compliance with his medication regimen.

On arrival to the ED, he was tachycardic and tachypneic with an oxygen saturation of 93% on room air. He was initially lying in a hospital bed in minimal respiratory distress. He had no evidence of heart failure on physical exam but his lung exam revealed diffuse inspiratory and expiratory wheezes throughout both lung fields. The remainder of his exam was normal. His peak flow was measured to be 150 (baseline \approx 300). Chest X-ray demonstrated hyperinflated lungs bilaterally with a normal cardiac silhouette and no infiltrates. The electrocardiogram showed a sinus tachycardia and right axis deviation but was

otherwise unremarkable. Basic laboratory tests were within normal limits. He was immediately provided with a continuous albuterol nebulized solution and given 60 mg of oral prednisone. His clinical status improved and his wheezing resolved. His oxygen saturation on room air increased to 97%. He was started on prednisone and azithromycin and discharged to follow-up with his primary medical doctor at the Veterans Administration Hospital.

While waiting for his prescriptions to be filled by the ED pharmacy, the patient's respiratory status worsened. He returned to the ED where he immediately received another nebulized treatment. He remained tachycardic and tachypneic with an oxygen saturation that had decreased to 87% on room air. His oxygen saturation improved to 93% with four liters of oxygen delivered by facemask. He was noted to be sitting in a tripod position in severe respiratory distress with extensive use of all accessory muscles of respiration. There was minimal air movement upon examination with no wheezes or dullness to percussion. His arterial blood gas at this time demonstrated a pH of 7.42; pCO₂ of 46; and a SaO₂ of 96% with a FiO₂ of 40% delivered by facemask. His respiratory distress remained refractory to all standard therapy including continuous nebulized bronchodilators, intravenous magnesium sulfate, subcutaneous epinephrine, and intravenous solumedrol. He was emergently sedated, paralyzed, intubated, and admitted to the intensive care unit for further evaluation and treatment.

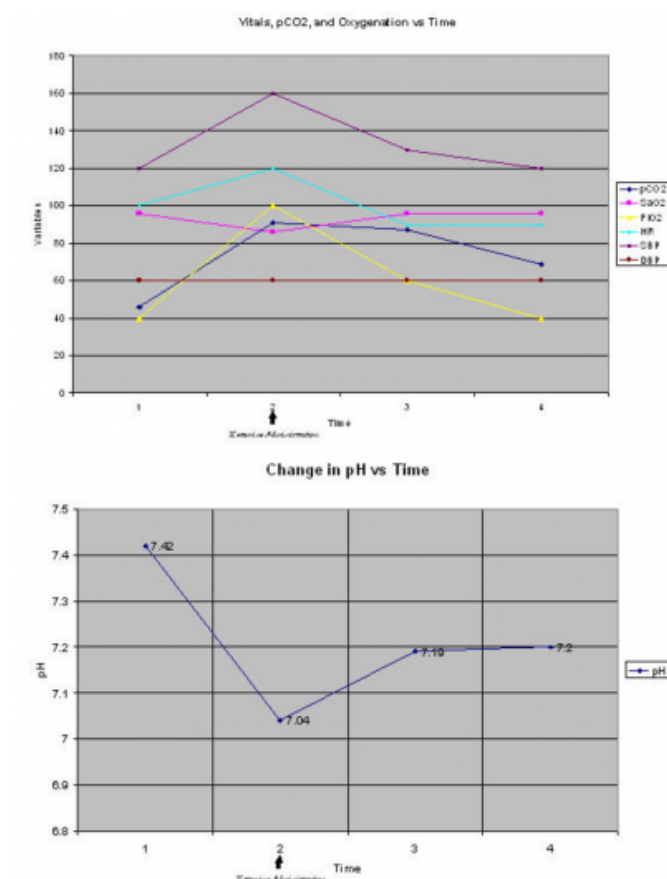
The patient remained difficult to ventilate with very high peak airway pressures (greater than 80 cmH₂O). Several ventilatory changes were attempted without change in the patient's condition. He continued to receive nebulized bronchodilators. An additional two grams of intravenous magnesium sulfate were administered along with subcutaneous terbutaline, epinephrine, and intravenous theophylline - all produced no noticeable effects on the patient's condition. In an attempt to improve laminar flow (and decrease airway resistance), the patient was changed to a HeliOx mixture without improvement. At this point, the patient's pH was 7.04; pCO₂ was 91; and SaO₂ was 86% on 100% FiO₂.

After a brief telephone consultation with the pulmonologist (MR), the patient was given a bolus of 25 mg of intravenous ketamine and started on a ketamine infusion at 15 mg/hr. Within minutes of administration, his airway resistance decreased rapidly such that peak airway pressures fell to 36

cmH₂O; the patient was then placed on assist control with rapid improvement in ventilation (pH increased to 7.19 within 30 minutes). The ketamine infusion was continued for 72 hours and then gradually weaned while maintaining adequate sedation with midazolam. Ketamine was discontinued after 80 hours without occurrence of emergence phenomena or significant dysphoria. The patient was extubated successfully on hospital day five and discharged to home on hospital day 9.

Figure 1

Figure 1: TOP $\hat{\wedge}$ – Graph demonstrating change in pCO₂, SAO₂, FiO₂, heart rate (HR), systolic blood pressure (SBP), and diastolic blood pressure (DBP) Before and After Ketamine Infusion; BOTTOM $\hat{\wedge}$ – Graph demonstrating change in pH Before and After Ketamine Infusion.



DISCUSSION

Ketamine (Ketalar®; Ketaject® - Pfizer, Inc.), or 2-o-chlorophenyl-2-methylaminocyclohexanone, was initially developed at Parke-Davis Laboratories by Calvin Stevens in 1962 to replace phencyclidine (PCP) as an anesthetic agent.⁶ Because of its significant potential for abuse, ketamine was classified as a Schedule 3 drug by the Drug Enforcement Agency (DEA) in 1998.⁷ It's current Food and Drug

Administration (FDA) approved indications include induction and maintenance of general anesthesia, analgesia, and sedation.^{7,8} Off-label uses of ketamine (and potential uses currently under investigation) include adjunctive use in the management of refractory Status Asthmaticus,⁹ treatment of epilepsy,^{10,11,12,13} and intranasal administration for chronic or severe pain.¹⁴

The potential efficacy of ketamine in Status Asthmaticus was first described in the English-language literature in a case report by Betts and Parkin in 1971.¹⁵ In this paper, the authors describe the use of ketamine as an anesthetic agent in a 5¼ year old with severe asthma undergoing extensive allergy skin testing. The patient received a bolus of ketamine over 60 minutes. The authors noted that audible wheezing cleared completely when the patient became unconscious and reappeared each time light sedation was reached. These clinical observations suggested that ketamine might possess intrinsic bronchodilatory effects when used in an asthmatic patient.

One year later, Corssen, et al., published a second case report of a severely asthmatic 5 year old who received ketamine by bolus administration over 30 minutes for surgical removal of an adhesion on the conjunctiva.¹⁶ The authors reported that audible wheezing with a prolonged expiratory phase, dyspnea, and cyanosis disappeared rapidly following the initial bolus of intravenous ketamine. Approximately every 8-10 minutes, signs and symptoms of bronchospasticity returned but would quickly disappear after readministration of ketamine. While neither of these case reports dealt specifically with the treatment of status asthmaticus by ketamine, the observations of both of these early case reports appeared to suggest that ketamine possessed a unique, yet profound, intrinsic bronchodilatory effect.

Figure 2

Table 1: Tabular List of Case Reports and Clinical Investigations of Ketamine Use in Acute Asthma and Status Asthmaticus. DBRPC denotes Double-Blind, Randomized, Placebo-Controlled Trial.

Author(s) Publication Year	No. of Patients	Age	Study Design	Dose of Ketamine	Duration of Infusion	Intubated	Measures of Improvement
Fisher, 1977 ²¹	One	5 y/o	Case Report	200 mg IV bolus	Bolus only	Yes	Improved ABGs
Strube and Hallam, 1986 ²²	One	13 y/o	Case Report	1.4 mg/kg IV bolus 2.5 mg/kg/hr IV infusion	6 hours	No	Decreased Respiratory rate and wheezing. Improved ABGs. Improved Mental Status.
Rock, et al. 1986 ²³	Two	4 y/o 10 y/o	Case Report	0.5 mg/kg IV bolus 1 mg/kg IV bolus 1 mg/kg/hr IV infusion	24 Hours	Yes	Improved Effective tidal Respiration. Improved ABGs. Increased tidal volume and improved inspiratory pressure.
Hemming, et al. 1994 ²⁴	One	28 y/o	Case Report	2.5 mg/kg/hr infusion	26 Hours	Yes	Increased Compliance (20→30). Improved gas exchange. PE with decreased wheezing and improved air movement.
Nehama, et al. 1996 ²⁵	One	8 Month	Case Report	1.4 mg/kg IV bolus X 2. 0.2 mg/kg/hr IV infusion (decreased to 0.15 mg/kg/hr after 4 hours)	40 Hours	Yes	Decrease in peak Inspiratory pressure (44→33). Decrease in PECO ₂ from 50→41. PE with increased chest wall excursion and decreased wheezing.
Hawton, et al. 1996 ²⁶	53 pts	18-65 y/o	DBRPC Trial	0.2 mg/kg IV bolus 0.5 mg/kg IV infusion X 2 hrs	3 Hours	No	Increased peak flow and Borg score. Decreased respiratory rate. No statistically significant difference vs. placebo.
Youssef-Ahmed, Et al. 1996 ²⁷	17 pts	5 months to 17 y/o	Retrospective Chart Review	2 mg/kg IV bolus 20-40 mg/kg/min IV infusion	Variable	Yes	Improved gas exchange and dynamic compliance of the lungs.
Petrillo, et al. 2001 ²⁸	10 pts		Prospective Observational Study	1 mg/kg IV bolus. 0.75 mg/kg IV infusion	1 Hour	No	Decreased CAS score (15→7.5). Improved respiratory rate (29→30). Decreased O ₂ requirements. PEF Improved but not statistically significant.

Thanks in large part to these early case reports, bench research was carried out to determine the physiological mechanism(s) behind ketamine's bronchodilatory effects. Physiologic research to determine the mechanism(s) by which ketamine produces direct bronchodilation of airway smooth muscle were initially carried out in animal tissue models. In one study utilizing tissue from the canine trachea, investigators demonstrated a significant relaxing effect of ketamine administration on canine tracheal smooth muscle with an associated decrease in intracellular calcium concentration.²⁵ In a separate study, investigators sought to determine whether the relaxant effect of ketamine is independent of endothelial relaxing factors such as nitric oxide (NO) or prostanoids.²⁶ Utilizing tracheal smooth muscle from female guinea pigs, the investigators demonstrated that ketamine promotes relaxation of smooth muscle fibers despite blockade of NO synthase by N-omega-nitro-L-arginine methyl ester (L-NAME), a potent NO synthase inhibitor, and blockade of prostanoid production by the potent cyclooxygenase inhibitor, indomethacin.²⁶ The authors concluded that ketamine relaxes airway smooth muscle via an epithelial-independent mechanism. Additional bronchial smooth muscle relaxation in dogs or female guinea pigs has been attributed to ketamine's inhibitory effect on mediator release from mast cells,²⁷ but not to stimulation of the N-Methyl-D-Aspartic Acid (NMDA) receptor on tracheal smooth muscle.²⁸

Despite these investigations, the most convincing evidence

suggests that ketamine produces bronchodilation through its sympathomimetic activity on bronchial smooth muscle.²⁹ Ketamine has been shown to be a potent catecholamine reuptake inhibitor of postganglionic sympathetic nerve endings resulting in direct stimulation of catecholamine receptors on bronchial smooth muscle.^{29,30,31} Beta-adrenergic blockade, then, would be expected to inhibit (as has been shown to occur) the relaxation produced by ketamine following induction of bronchospasm via an antigen-mediated pathway.^{29,30,31}

From bench to bedside, however, the evidence is less clear. Since the initial case reports appeared in the 1970's, several additional case reports and investigations (table 1) have demonstrated improved gas exchange, compliance, and overall lung function after infusion of ketamine in patients with Status Asthmaticus refractory to standard therapy.^{15,16,17,18,19,20,21} In 1996, Youssef-Ahmed, et al. performed a retrospective chart review of 17 mechanically ventilated patients with refractory bronchospasm aged 5 months to 17 years who had received a ketamine infusion during mechanical ventilation.²³ The authors demonstrated a statistically significant improvement in gas exchange, as measured by the PaO₂/FiO₂ ratio, and dynamic compliance of the chest.²³ Additionally, a prospective observational study carried out by Petrillo, et al. in 2001 that included ten pediatric patients in the emergency department refractory to standard therapy for Status Asthmaticus demonstrated a statistically significant decrease in clinical asthma score (CAS), respiratory rate, and oxygen requirements.²⁴ Peak expiratory flow (PEF) also improved following Ketamine infusion but did not achieve statistical significance.

The only randomized, double-blind, placebo-controlled trial to assess the efficacy of ketamine in acute asthma was carried out by Howton, et al.²² In this study, the investigators randomized 53 consecutive patients aged 18 to 65 with a clinical diagnosis of an acute asthma exacerbation and peak expiratory flow rates less than 40% of predicted to receive either ketamine hydrochloride or placebo via intravenous infusion. All patients received oxygen, continuous nebulized albuterol, and methylprednisolone prior to trial medication and none of the patients required intubation. The investigators found no statistically significant differences in peak flow, Borg score, respiratory rate, and 1-second forced expiratory volume between the two study groups.²² The authors concluded that intravenous ketamine at doses low enough to avoid significant dysphoric reactions

demonstrated no increased bronchodilatory effect over standard therapy.

The intention of Howton, et al's investigation, however, was not to delineate the potential use of ketamine in Status Asthmaticus refractory to standard therapy, but rather to demonstrate the benefit (or lack thereof) of ketamine as an adjunct to standard therapy in the emergency department.²² While the study demonstrated that ketamine is not an appropriate adjuvant treatment for all patients with an acute asthma exacerbation, it did not address the potential efficacy of the drug as a "medication of last resort" in patients refractory to standard therapy. The mortality and morbidity in this group of patients is exceptionally high (having been reported to be as high as 38%₃₂) and treatment options remain quite limited.

CONCLUSION

Treatment options for Status Asthmaticus remain limited despite current advances in the understanding of the pathophysiology and medical management of the condition. Several anecdotal case reports demonstrate rapid recovery from Status Asthmaticus after infusion of Ketamine.^{15,16,17,18,19,20,21} A prospective observational study and a retrospective study both demonstrated marked improvement in respiratory parameters.^{23, 24} The only double-blind, randomized, placebo control trial of intravenous ketamine carried out by Howton, et al., demonstrated no increased bronchodilatory effect compared with standard therapy in emergency room patients with acute asthma exacerbations.²² The results of this study, however, should not be generalized to patients with Status Asthmaticus refractory to standard therapy.

The incidence of significant adverse reactions associated with ketamine relegate its use to those situations in which standard therapy has failed and in which the disease itself is associated with a very high morbidity and/or mortality. The ideal study design should be similar to that utilized by Howton, et al.²² with one very important difference: intravenous ketamine would only be randomized to patients with Status Asthmaticus who remain refractory to aggressive standard therapy.

Given the excellent results obtained during the management of the critically ill patient with Status Asthmaticus presented in this brief report, further investigation into the bronchodilatory effects of ketamine and its use in refractory Status Asthmaticus appear warranted.

ACKNOWLEDGMENTS

This case report was presented as an abstract entitled, "To Breathe or Not to Breathe: Ketamine for Status Asthmaticus?," at Aurora Scientific Day, 2004 in Milwaukee, Wisconsin held May 20, 2004 at the Pfister Hotel.

The authors are indebted to Mark A. Gennis, M.D. for critically reviewing the final manuscript and providing invaluable advice prior to submission of the manuscript.

CORRESPONDENCE TO

David Galbis-Reig, M.D. Department of Internal Medicine
1301 College Avenue, Bld. 6E South Milwaukee, WI 53172
Tel: 414-688-2204 E-Fax: 501-423-1588 E-Mail:
dgalbisreig@aol.com

References

1. Clancy K. British guidelines on the management of asthma. *Thorax*. 2004 Jan; 59(1): 81-82.
2. Roy SR. Asthma. *South Med J*. 2003 Nov; 96(11): 1061-1067.
3. Henderson SO, Acharya P, Kilaghbiham T, et al. Use of heliox driven nebulizer therapy in the treatment of acute asthma. *Ann Emerg Med*. 1999; 33: 1414-146.
4. Rodrigo GJ, Rodrigo C, Pollack CV, Rowe B. Use of helium-oxygen mixtures in the treatment of acute asthma. *Chest*. March, 2003; 123: 891-896.
5. Roy TM, Pruitt VL, Garner PA, Heine MF. The potential role of anesthesia in status asthmaticus. *Journal of Asthma*. 1992; 29(2); 73-77.5.
6. Jansen K. Ketamine: Dreams and Realities. 2001: Sarasota, Florida; Multidisciplinary Association for Psychedelic Studies (MAPS). Copyright Karl L. R. Jansen, M.D., Ph.D.
7. U.S. Drug Enforcement Administration. Drug Scheduling. <http://www.usdoj.gov/dea/pubs/scheduling.HTML>. Last downloaded February 15, 2004.7.
8. Rushman GB, Davies NJH, Cashman JN. Lee's Synopsis of Anaesthesia. 12th edition. Great Britain; Copyright Reed Educational and Professional Publishing Ltd, 1999. Pp. 191-194. ISBN: 0-7506-3247-X.
9. JBC Handbook, 4th Edition. Ketamine hydrochloride. 1997. <http://members.ozemail.com.au/~jamesbc/pages/drugs/141.htm>. Last downloaded February 15, 2004.
10. Fujikawa DG. Neuroprotective effect of ketamine administered after status epilepticus onset. *Epilepsia*. 1995; 36: 186-195.
11. Butterbaugh GG, Michelson HB. Anticonvulsant properties of phencyclidine and ketamine. *Nat Inst Drug Res Monogr Ser*. 1986; 64: 67-79
12. Celesia GG, Chen C, Bamforth BJ. Effects of ketamine in epilepsy. *Neurology*. 1975; 25: 169-172.
13. Corssen G, Little SC, Tavakoli M. Ketamine and epilepsy. *Anesth Analg*. 1974; 53: 319-335.
14. Innovative Drug Delivery Systems, Inc. Product Candidates - Intranasal Ketamine. <http://www.idds.com/product>. Last downloaded February 15, 2004.

15. Betts EK, Parkin CE. Use of ketamine in an asthmatic child. *Anesth Analg*. 1971; 50:420.
16. Corssen G, Gutierrez J, et al. Ketamine in the anesthetic management of asthmatic patients. *Anesth Analg*. 1972; 51: 588.
17. Fisher MM. Ketamine hydrochloride in severe bronchospasm. *Anesthesia*. 1977; 32: 771.
18. Strube PJ, Hallam PL. Ketamine by continuous infusion in status asthmaticus. *Anaesthesia*. 1986; 41: 1017-1019.
19. Rock MJ, Reyes de la Rocha S, L'Hommedieu CS, Truemper E. Use of ketamine in asthmatic children to treat respiratory failure refractory to conventional therapy. *Critical Care Medicine*. 1986; 14(5): 514-516.
20. Hemming A, MacKenzie I, Finfer S. Response to ketamine in status asthmaticus resistant to maximal medical treatment. *Thorax*. 1994; 49: 90-91.
21. Nehama J, Pass R, et al. Continuous ketamine infusion for the treatment of refractory asthma in a mechanically ventilated infant: case report and review of the pediatric literature. *Pediatric Emergency Care*. 1996; 12(4): 294-297.
22. Howton JC, Rose J, et al. Randomized, double-blind, placebo-controlled trial of intravenous ketamine in acute asthma. *Annals of Emergency Medicine*. February, 1996; 27(2): 170-175.
23. Youssef-Ahmed MZ, Silver P, Nimkoff L, Sagy M. Continuous infusion of ketamine in mechanically ventilated children with refractory bronchospasm. *Intensive Care Medicine*. Sep, 1996; 22(9): 972-976.
24. Petrillo TM, Fortenberry JD, Linzer JF, Simon HK. Emergency department use of ketamine in pediatric status asthmaticus. *Journal of Asthma*. Dec, 2001; 38(8): 657-664.
25. Pabelick CM, Jones KA, et al. Calcium concentration-dependent mechanisms through which ketamine relaxes canine airway smooth muscle. *Anesthesiology*. May, 1997; 86(5): 1104-1111.
26. Tetsumi S, Hirota K, et al. The relaxant effect of ketamine on guinea pig airway smooth muscle is epithelium-independent. *Anesthesia & Analgesia*. March, 1997; 84(3): 641-647.
27. Hirshman CA, Downes H, et al. Ketamine block of bronchospasm in experimental canine asthma. *British Journal of Anaesthesia*. 1979; 51: 713.
28. Sato T, Hirota K, Matsuki A, Zsigmond EK, et al. The role of the N-Methyl-D-Aspartic acid receptor in the relaxant effect of ketamine on tracheal smooth muscle. *Anesthesia and Analgesia*. 1998; 87: 1383-1388.
29. Takki S, Nikki P, Jaattela A, Tammisto T. Ketamine and plasma catecholamines. *British Journal of Anaesthesia*. 1972; 44: 1318.
30. White PR, Way WL, Trevor AI. Ketamine - its pharmacology and therapeutic uses. *Anesthesiology*. 1982; 56: 119.
31. Idrad I, Ahlgren I, et al. Ketamine infusion - pharmacokinetic and clinical effects. *British Journal of Anaesthesia*. 1979; 51: 1167.
32. Scoggin C, Sahn S, Petty T. Status asthmaticus: a nine-year experience. *JAMA*. 1977; 238: 1158-1162.

Author Information

David Galbis-Reig, MD

Department of Internal Medicine, Aurora Sinai Medical Center

Marc A. Rasansky, MD

Medical Director, Intensive Care Unit, Department of Internal Medicine, Pulmonary Medicine, and Critical Care, Aurora Sinai Medical Center