

A yolk sac tumor in a female newborn with a subcutaneous metastasis of the abdominal wall

A Wacker, F Neunhoeffler, J Fuchs, S Warmann, C Schwarze, K Sotlar, H Scheel-Walter, R Handgretinger

Citation

A Wacker, F Neunhoeffler, J Fuchs, S Warmann, C Schwarze, K Sotlar, H Scheel-Walter, R Handgretinger. *A yolk sac tumor in a female newborn with a subcutaneous metastasis of the abdominal wall*. The Internet Journal of Pediatrics and Neonatology. 2008 Volume 10 Number 2.

Abstract

Extragenital yolk sac tumors (YST) are extremely rare tumors. Only a few case reports can be found in the literature. We report about a female term newborn. After delivery a sacrococcygeal tumor was obvious. Alpha Fetoprotein (AFP) levels were in the upper normal range (91 006 ng/ml). The tumor was completely removed. Histological examinations revealed a typical YST. In the follow-up examinations a subcutaneous metastasis in the abdominal wall was found and excised at the age of 6 weeks. Curative polychemotherapy was induced. After 2 cycles AFP levels were decreased. However, the patient had a local relapse after the 4th cycle of chemotherapy and showed increased AFP levels. Therefore, hyperthermia combined with chemotherapy was applied and a second surgical resection was done. Despite of multiple therapy regime, the patient died due to tumor progress. This case demonstrates an uncommon dissemination of a primary YST. Therapeutic options in neonates are extremely difficult.

INTRODUCTION

Sacrococcygeal teratomas (SCT) are one of the most common teratomas. However, the malignant types of these tumors are still relatively rare (1). SCT are more common in girls than in boys. The majority of SCT in neonates are benign, but the probability of malignant degeneration advances in the first months of life (2). Yolk sac tumors (YST) are rare and highly malignant tumors, occurring in children as well as in young adults. In the past, the outcome of these tumors was very poor and the prognosis was almost always fatal. With the refinement of chemotherapeutic options in the last several decades survival rates have improved.

CASE REPORT

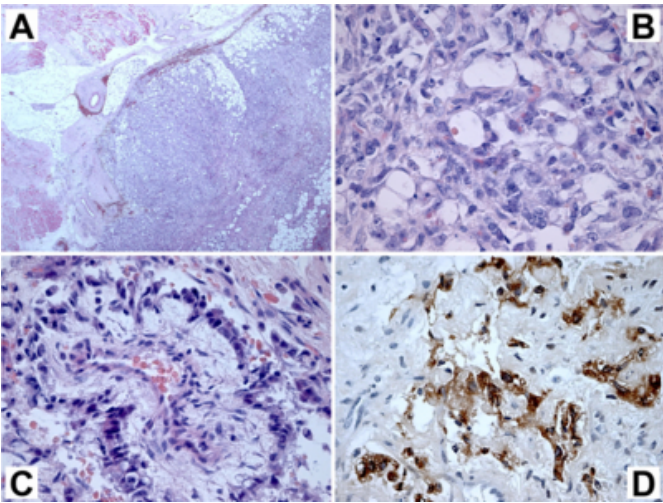
We report on a female term newborn (birth weight: 3580g) delivered by caesarean section, APGAR Score 9/10/10. After delivery an unknown sacrococcygeal tumor mass was visible. Neurological assessment was normal. There was no constipation or anuria. Physical examination revealed abdominal meteorism.

Ultrasound of the sacrococcygeal region showed a mass consisting solid and cystic parts as well as vascular signs

(diameter: 1,5 cm). The Alpha Fetoprotein (AFP) levels were in the upper normal range (91 006 ng/ml; normal range in newborns: mean 48406 +/- 34718 ng/ml). A complete tumor resection including the os coccygeum was performed. The resection margins were free of tumor. The preoperative clinical diagnosis was a teratoma, but histological examination of the surgical specimen revealed a typical yolk sac tumor of extragenital origin. Immunohistochemical evaluation of the tumor was positive of AFP and cytokeratin (AE1 /AE3).

Figure 1

Fig. 1: Morphological and immunohistochemical evaluation.

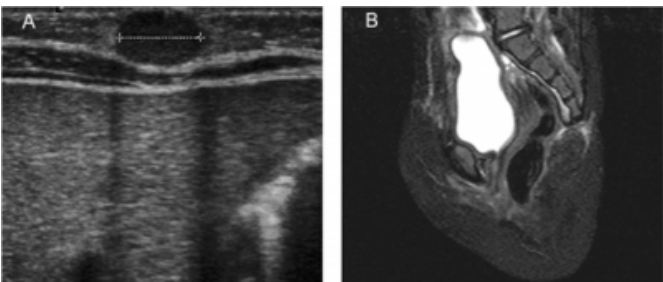


A, highly cellular non-capsulated yolk sac tumor showing an infiltrative growth into adjacent soft tissue structures. B, higher magnification in some areas revealed a microcystic growth pattern with a high degree of vascularization. C, lots of characteristic Schiller-Duval bodies were found, consisting of small tumor cells arranged in a perpendicular pattern around small thin walled blood vessels. D, immunohistochemistry revealed a cytoplasmic expression of AFP in a subset of tumor cells.

Postoperative staging examinations revealed the occurrence of a secondary metastasis with a diameter of 7 mm in the abdominal wall, which was completely resected at the age of six weeks.

Figure 2

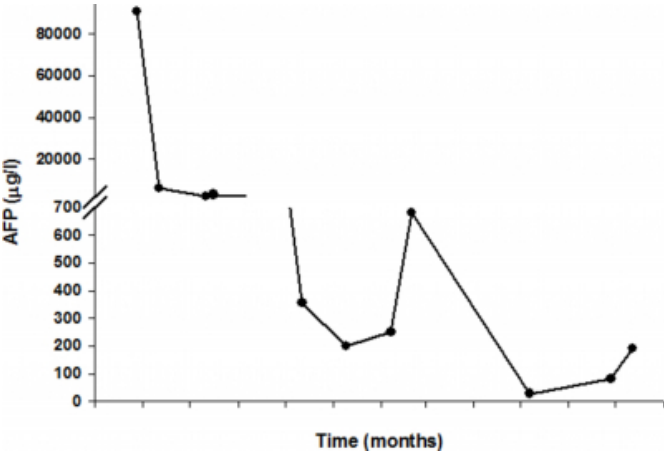
Fig. 2: Secondary metastasis of the yolk sac tumor in the abdominal wall (A) and the pre-sacral relapse (B)



The newborn received four cycles of a chemotherapy, containing cisplatin (20 mg/m² for 5 days) and etoposide (100 mg/m² for 3 days). AFP levels decreased after two cycles.

Figure 3

Table 1 : Alpha Fetoprotein



A local relapse in the pre-sacral region was diagnosed after 4 cycles (AFP maximum: 682 ng/ml). 4 cycles of hyperthermia (41- 41.6°C) combined with cisplatin, etoposide, cyclophosphamide day 1 and 4 and etoposide and cyclophosphamide day 2 and 3 followed. A complete surgical resection of the relapsed tumor including the top of the os sacrum was performed after the third cycle. Despite of the multimodal therapeutic regime, the patient died due to rapid tumor progress.

DISCUSSION

The YST was first identified as a germ cell tumor by Teilum in 1946 (3). It is found in the testes, ovaries, and several extragonadal sites including the pre-sacral area and anterior mediastinum. Whereas most of the benign tumors are seen in newborns, the malignant form occurs predominantly after the first year. Malignant YST in newborns are extremely rare. The incidence of teratomas with YST is about 5.8 %. 2 to 10 % of these tumors are malignant up to the age of four months. After this age, the rate of malignancy increases steeply up to 50-90% (1). The event free survival rates at presentation are about 70 %.

A YST of the sacrococcygeal region with dissemination in the abdominal wall is uncommon and has not been reported in the literature. The unusual way of dissemination has to be discussed.

The histogenesis of primary YST is still unclear. First, it has been suggested that YSTs might originate from the germ cells that escaped their migration course from the yolk sac to the genital ridge during embryogenesis (4,5). Second, the embryonic cell theory favors the persistence of pluripotent embryonic cells, which escaped from the influence of the

differentiation process during embryogenesis.

Yolk sac tumors show an infiltrative growth into adjacent soft tissue structures, higher magnification in some areas revealed a microcystic growth pattern with a high degree of vascularisation. Lots of characteristic Schiller-Duval bodies can be found, consisting of small tumor cells arranged in a perpendicular pattern around small thin walled blood vessels. Immunohistochemistry reveals a cytoplasmic expression of AFP in a subset of tumor cells (6).

YST express high blood levels of AFP. But age depended normal values of AFP in newborns have to be considered.

Heerema-McKenney et al. even found no correlation between AFP elevation above mean values for gestational age and the presence of YST at all (7).

Therapeutic regimes are scarce and not well established. Radical surgical resection is the most important strategy (7).

The most effective chemotherapeutic agent is cisplatin but in newborns this drug is an extremely toxic agent. However, the outcome of malignant sacrococcygeal germ cell tumors, which were not treated with cisplatin, is almost always fatal (8). Therefore combined chemotherapy with reduced doses, in combination with hyperthermia might be a new therapeutic strategy. Due to the rare cases, experience in this strategy is missing.

Second-look surgical procedures of residual tumors (primary or metastatic site) may improve the survival rates.

Radiotherapy was not planned to avoid growth disturbances and to receive the fecundity.

Significant improvement of survival rates might be obtained

by a combination of surgery, chemotherapy and radiotherapy (9).

Better characterisation of the biologic and pathologic features of this tumor entity is still needed as well as the knowledge of the clinical behaviour to improve the survival rates. Due to the rare incidence in neonates clinical studies are needed but missing.

References

1. Ein SH, Mancer K, Adeyemi SD. Malignant Sacrococcygeal teratoma- endodermal sinus, yolk sac tumor- in infants and children: a 32 year review. *Journal of Pediatric Surgery* 1985;5: 473- 477.
2. Raney BR, Chatten J., Littman P, Jarrett P, Schnauffer L, Bishop H, D'Angio GJ. Treatment Strategies for infants with malignant sacrococcygeal teratoma. *Journal of Pediatric Surgery* 1981;16 : 573-577.
3. Green DM, Brecher ML, Grossi M, Simpson L, Fisher JE, Allen JE, Cooney DR, Jewett TC, Freeman AI. The use of different induction and maintenance chemotherapy regimens for the treatment of advanced yolk sac tumors. *Journal of Clin Oncol* 1983;1: 111-116.
4. Hart WR. Primary endodermal sinus tumor of the liver. First reported case. *Cancer* 1975;35: 1453-1458.
5. Natori T, Teshima S, Kikuchi Y. Primary yolk sac tumor of the liver, an autopsy case with ultrastructural and immunohistochemical studies. *Acta Pathol Jpn* 1983;33: 555-564.
6. Gilbert KL, Bergman S, Dodd LG, Volmar KE, Creager AJ. Cytomorphology of yolk sac tumor of the liver in fine-needle aspiration: a pediatric case. *Diagn Cytopathol.* 2006 Jun; 34:421-3.
7. Heerema-McKenney A, Harrison MR, Bratton B, Farrell J, Zaloudek C. Congenital teratoma: a clinicopathologic study of 22 fetal and neonatal tumors. *Am J Surg Pathol.* 2005; 29 :29-38.
8. Hawkins E, Isaacs H, Cushing B, Rogers P. Occult malignancy in neonatal sacrococcygeal teratomas. *The American Journal of Pediatric Hematology and Oncology* 1993; 15: 406-409.
9. O'Sullivan P, Daneman A, Chan HS, Smith C, Robey G, Fitz C, Martin DJ. Extragonadal endodermal sinus tumors in children: a review of 24 cases. *Pediatr Radiol.* 1983;13: 249-57.

Author Information

Annette Wacker, MD

University Children's Hospital, Hoppe-Seyler Str. 1, D-72076 Tübingen, Germany

Felix Neunhoeffer, MD

University Children's Hospital, Hoppe-Seyler Str. 1, D-72076 Tübingen, Germany

Jörg Fuchs, PhD

University Children's Hospital, Hoppe-Seyler Str. 1, D-72076 Tübingen, Germany

Steven Warmann, PhD

University Children's Hospital, Hoppe-Seyler Str. 1, D-72076 Tübingen, Germany

Carl-Philipp Schwarze, MD

University Children's Hospital, Hoppe-Seyler Str. 1, D-72076 Tübingen, Germany

Karl Sotlar, PhD

University of Tübingen, Institute of Pathology, Calwerstr.3, D- 72076 Tübingen, Germany

Hans-Gerhard Scheel-Walter, MD

University Children's Hospital, Hoppe-Seyler Str. 1, D-72076 Tübingen, Germany

Ruppert Handgretinger, PhD

University Children's Hospital, Hoppe-Seyler Str. 1, D-72076 Tübingen, Germany