

Posterior fossa surgery in the sitting position in a pregnant patient with medulloblastoma

A Aravind, S Shakeel, M Potdar, P Gujjar, L Dewoolkar

Citation

A Aravind, S Shakeel, M Potdar, P Gujjar, L Dewoolkar. *Posterior fossa surgery in the sitting position in a pregnant patient with medulloblastoma*. The Internet Journal of Anesthesiology. 2007 Volume 16 Number 2.

Abstract

Primary brain tumors and pregnancy rarely occur together and the incidence of medulloblastoma in pregnancy is still rarer. We describe a 19-yr-old woman in the 30th week of pregnancy who underwent emergency surgery in the sitting position for a posterior fossa medulloblastoma which was causing significant mass effect. Continuous monitoring of both mother and fetus was performed. Particular attention was given to maintain stable maternal hemodynamics and to detect venous air embolism. The surgical procedure and postoperative period were uneventful. This case demonstrates that when absolutely necessary, anesthesia and neurosurgery for posterior fossa lesions can be successful during the third trimester of pregnancy. Furthermore, with meticulous intraoperative monitoring, the operation can be performed safely with the patient in the classical sitting position.

Implications Statement: Anesthesia and neurosurgery for posterior fossa lesions can be performed safely in the sitting position during the third trimester of pregnancy.

INTRODUCTION

The frequency of non-obstetric surgery during pregnancy is low, approximately 2 per 1000 cases.¹ The main reasons for such interventions are emergency intra-abdominal disorders. Central nervous system disorders seldom require immediate surgical attention, and cases that do are usually vascular in nature, such as subarachnoid hemorrhage. The incidence of subarachnoid hemorrhage is estimated to be approximately 1 per 2500 pregnancies,² while the concurrence of primary brain tumors and pregnancy is even rarer. Although a sufficiently large epidemiologic study concerning the incidence of brain tumors during pregnancy has not yet been carried out, several authors have claimed that the incidence of such tumors may be lower than that in non-pregnant women.^{3,4,5,6} We report a case of a 19-yr-old woman in the 30th week of pregnancy who underwent emergency craniectomy in the sitting position for medulloblastoma.

CASE DESCRIPTION

A 19-yr-old woman in the 30th week of pregnancy (as per ultrasonography) presented with complaints of severe headache and vomiting since one month. She had no previous medical history and the pregnancy had been uneventful till then. An MRI scan of brain showed a SOL in

the posterior fossa ($3.2 \times 3.1 \times 2.8$ cm). She was admitted to the neurosurgery department and was treated conservatively with corticosteroids and mannitol to lower her intracranial pressure. In consultation with the obstetric department, it was decided to perform a caesarian section around the 34th week of gestation, following which definitive neurosurgery was planned. However, she clinically deteriorated within the next forty eight hours and became drowsy and unresponsive to verbal commands. It was then decided to perform emergency craniectomy while attempting to conserve the pregnancy. The condition of the fetus was good, and all laboratory values were within normal limits.

The patient (weight 56kg) was given ranitidine 50 mg iv prior to surgery. Before induction, a wedge was placed under the right hip to displace the uterus to the left and increase vena caval blood flow. After preoxygenation, anesthesia was induced with 1 mg of midazolam, 100µgm fentanyl and 300 mg thiopentone intravenously. Rocuronium 50 mg was used to facilitate orotracheal intubation and the relaxant used for maintenance was vecuronium. Sellicks maneuver was used to prevent aspiration of gastric contents. Anesthesia was maintained with low-dose isoflurane (0.5%) and 50% nitrous oxide in oxygen, with continuous infusion of fentanyl 0.15–0.25 mg/hour. In addition to standard monitoring (ECG, pulse oximetry, oxygen analyzer, end-tidal carbon dioxide concentration, urine output), invasive arterial pressure, central venous catheter and esophageal stethoscope were used. Fetal heart rate was monitored using a fetoscope

and the obstetricians were standby to intervene in case of fetal compromise. With constant monitoring of central venous pressure, heart rate and arterial pressure and judicious administration of 0.9% normal saline, the patient was gradually given sitting position with continuous monitoring for hemodynamics. A midline suboccipital craniectomy was performed and the mass completely resected. Intra operative blood loss was 500ml. Histopathology confirmed the diagnosis of medulloblastoma. Monitoring of the mother and fetus was continued throughout surgery and periodically during the first 24 hours after operation.

Throughout surgery, ETCO₂ and esophageal stethoscope monitoring was done to detect any episode of air embolism. There was no venous air embolism detected. All vital parameters were stable throughout the procedure. Arterial blood gases were assessed periodically with mean values as follows: pH 7.38–7.49, PaCO₂ 26-32 mm Hg, PaO₂ 195-225 mm Hg. Plasma electrolyte concentrations and blood glucose were within normal limits intraoperatively. After surgery neuromuscular blockade was reversed with glycopyrrolate and neostigmine.

After adequate reversal of neuromuscular blockade and full recovery of protective airway reflexes, the patient was extubated. Post operatively, the patient was transferred to the neurosurgical ICU and shifted to the ward after 24 hours. Subsequent obstetric and ultrasound checks were normal. She was discharged on the 4th postoperative day. The rest of her pregnancy was uneventful and she subsequently had a full term normal delivery (Birth weight 2.9kg and Apgar score 9/10 at one minute). Both the mother and baby are presently well and the mother is scheduled to undergo postoperative radiotherapy.

Figure 1

Figure 1 : Pre operative MRI

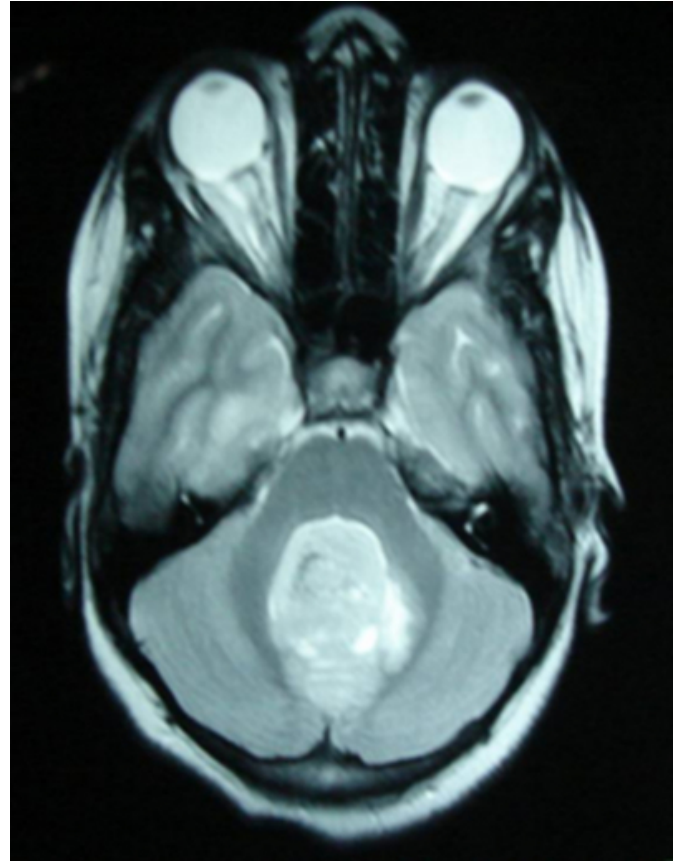
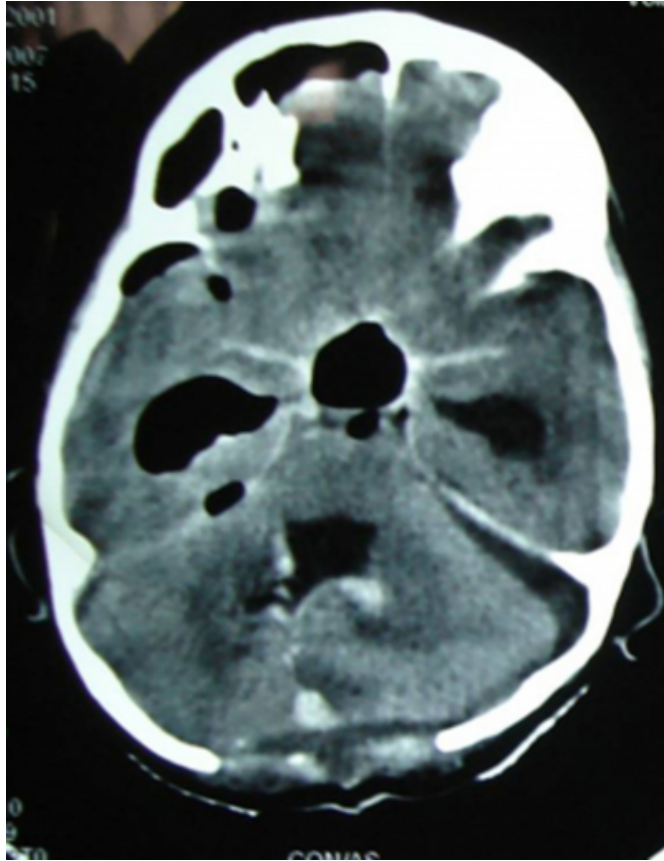


Figure 2

Figure 2 : Postoperative CT



DISCUSSION

Medulloblastoma is rare in adults, accounting for <1% of all adult brain neoplasia⁷. Surgery and radiotherapy are the standard of care in the treatment of adulthood medulloblastoma⁸. However, the management of medulloblastoma patients during pregnancy poses a difficult dilemma. This includes the patient and fetus's well being weighed against treatment toxicities. In the third trimester, an early delivery should be considered as the outcome of individual cases cannot be guaranteed. However, if the surgery is an emergency, pregnancy should not affect the decision to proceed. A medulloblastoma causing brainstem compression is an emergency, in which case delay could endanger the life of the mother and fetus. Furthermore, premature labor does not seem to be a frequent outcome of surgery during pregnancy⁹, and fetal mortality and morbidity are minimal when surgery is unavoidable¹⁰. However, the data regarding non-obstetric surgery during pregnancy refer mainly to abdominal surgery (often laparotomy), and reports on neurosurgery for brain tumors (particularly at the subtentorial site) in pregnancy are scarce.

Respiratory function during late pregnancy is known to be

more favorable in the semi-sitting position than in the supine or lateral positions, and in any position other than the full left lateral decubitus position, precautions must be taken to ensure that the gravid uterus is not impinging on the inferior vena cava, aorta or iliac vessels¹¹. We believe that the sitting position offers many advantages with acceptable risks in adult neurosurgical patients. It not only aids clear surgical access, but also improves cerebral venous drainage, lowers intracranial pressure (ICP) and promotes drainage of cerebral spinal fluid. We decided to operate in the sitting position as the prone position is contraindicated by the presence of the fetus. Almost all posterior fossa surgeries are performed at our institute with the patient in the sitting position, and therefore the surgical team is fully experienced in this particular surgical approach.

Anesthetic induction in such a case provides the clearest example of the need to reconcile competing clinical goals. A rapid-sequence induction designed to prevent aspiration does little to prevent the hemodynamic response to intubation that can be catastrophic for the patient who has an intracranial SOL or increased ICP. At the same time, a slow "neuro induction" with thiopental, a narcotic, a nondepolarizing muscle relaxant, and mask ventilation does little to decrease the risk of aspiration. We preferred not to use succinylcholine mainly for fear of increasing intracranial pressure. On balance, it seemed that the least risk for our patient was to proceed with careful induction that ensured hemodynamic stability and good oxygenation. Cricoid pressure was maintained from the point at which consciousness was lost until intubation was confirmed by capnography.

It was important for us to maintain an adequate arterial pressure to avoid uterine hypo perfusion and fetal hypoxia. Moreover, decreased uterine perfusion can also cause premature uterine contractions¹². It is our routine practice to insert an esophageal stethoscope and a central line in all sitting position cases. A CVP catheter is valuable as a means of assessing the effectiveness of the methods to raise venous pressure; in addition, if air does enter the circulation, it provides a potential method for aspiration.

The likelihood of premature labor and delivery following a neurosurgical procedure is less than with an intra-abdominal procedure. We preferred to use isoflurane to decrease uterine contractility during surgery. Moreover, use of an isoflurane - fentanyl combination provided stable hemodynamics with adequate arterial blood pressure to avoid uterine hypo perfusion and fetal hypoxia.

Fetal heart rate monitoring is believed to be useful for identifying intraoperative conditions leading to impaired uteroplacental blood flow and fetal oxygenation. In a review, Rosen advocated fetal monitoring whenever possible ¹³. However, Horrigan et al concluded that there is no documented evidence that FHR monitoring is required during nonobstetric surgical procedures in the pregnant patient, provided the mother is not hypoxic or hypotensive ¹⁴. Balki and Manninen reported successful management of a case similar to our patient without FHR monitoring ¹⁵.

In summary, this case demonstrates that anesthesia and neurosurgery for posterior fossa lesions can be performed safely during the third trimester of pregnancy. If the team is experienced, surgery in the sitting position is a valid option. Continuous monitoring of both mother and fetus is essential. It is important to prevent arterial hypotension which may lead to substantial reduction in uteroplacental perfusion, and to maintain normal PaO₂, PaCO₂ and pH, to avoid fetal hypoxia and acidosis.

References

1. Kammerer WS. Nonobstetric surgery in pregnancy. *Med Clin North Am* 1987; 71: 551-60
2. Rosen MA. Cerebrovascular lesions and tumors in the pregnant patient. In: Newfield P, Cottrell JE, eds. *Neuroanesthesia: Handbook of Clinical and Physiologic Essential*. Boston: Little, Brown and Company, 1991; 230-48
3. Haas JF. Pregnancy in association with a newly diagnosed cancer: A population-based epidemiologic assessment. *Int J Cancer* 1984; 34: 229-235.
4. Haas JF, Janisch W, Staneczak W. Newly diagnosed primary intracranial neoplasms in pregnant women: a population-based assessment. *J Neurol Neurosurg Psychiatry* 1986; 49: 874-880.
5. Roelvink NC, Kamphorst W, van Alphen HA, Rao BR. Pregnancy-related primary brain and spinal tumors. *Arch Neurol*. 1987 Feb; 44(2):209-215.
6. Simon RH. Brain tumors in pregnancy. *Semin Neurol*. 1988 Sep; 8(3):214-21.
7. Rutka JT. Medulloblastoma. *Clin Neurosurg* 44: 571-585, 1997.
8. Wolden SL, Dunkel IJ, Souwaidane MM et al. Patterns of failure using a conformal radiation therapy tumour bed boost for medulloblastoma. *J Clin Oncol* 21: 3079, 2003.
9. Amos JD, Schorr SJ, Norman PF, et al. Laparoscopic surgery during pregnancy. *Am J Surg* 1996; 171: 435-37.
10. Roelvink NCA, Kamphorst W, van Halphen HAM, Rao BR. Pregnancy-related primary brain and spinal tumors. *Arch Neurol* 1987; 44: 209-15.
11. Smith BE. Obstetrics. In: Martin JT, Warner MA, eds. *Positioning in Anesthesia and Surgery*, 3rd Edn. Philadelphia: WB Saunders Company 1997; 267-79.
12. Gianopoulos JG. Establishing the criteria for anesthesia and other precautions for surgery during pregnancy. *Surg Clin North Am* 1995; 75: 33-45
13. Rosen MA. Management of anesthesia for the pregnant surgical patient. *Anesthesiology*. 1999 Oct; 91(4):1159-63.
14. Horrigan TJ, Villarreal R, Weinstein L. Are obstetrical personnel required for intraoperative fetal monitoring during nonobstetric surgery? *J Perinatol* 1999; 19: 124-6.
15. Balki M, Manninen PH. Craniotomy for suprasellar meningioma in a 28-week pregnant woman without fetal heart rate monitoring. *Can J Anesth* 2004; 51: 573-76.

Author Information

Ajay Aravind, MD

Senior Resident, Department of Anaesthesiology, Seth G. S. Medical College and KEM Hospital

S Mohammed Shakeel, MBBS

Junior Resident, Department of Anaesthesiology, Seth G. S. Medical College and KEM Hospital

Meenoti P Potdar, MD

Lecturer, Department of Anaesthesiology, Seth G. S. Medical College and KEM Hospital

Pinakin Gujjar, MD

Professor, Department of Anaesthesiology, Seth G. S. Medical College and KEM Hospital

L. V. Dewoolkar, MD

Professor and Head, Department of Anesthesiology, Seth G. S. Medical College and KEM Hospital