

Femoral Anteversion : Comparison By Two Methods

S Rokade, A Mane

Citation

S Rokade, A Mane. *Femoral Anteversion : Comparison By Two Methods*. The Internet Journal of Biological Anthropology. 2008 Volume 3 Number 1.

Abstract

This study gives comparative data on femoral anteversion obtained by two different methods. The angle was measured mechanically on 144 adult dry femora by method 1 –centre head neck line to retrocondylar line and method 2- anterior head trochanter line to retrocondylar line. These two methods give significantly different mean angles, method-1 8.68o (+/-6.37) and method-2 16.34o (+/- 7.7). The angle in Indians is lower than African and English population. Bilateral variation was observed in the angle (left > right, p<.05). The incidence of retroversion was higher when observed with method-1. Conversion factor for method-1 to method-2 is $10.408 + 0.683 \times (\text{anteversion angle})$ and for method- 2 to method -1 is $1.054 + 0.047 \times (\text{anteversion angle})$. Method-2 is more reliable. The data established in this study will help to decide the validity and accuracy of clinical data obtained using advanced techniques. The conversion equations will make available data obtained by either method for future studies. The study will also be useful in general human osteology and forensic anthropology as far as the academics, clinical knowledge or research is concerned.

INTRODUCTION

Any increase or decrease in the angle of femoral anteversion is associated with various clinical conditions. The increased angle of anteversion is associated with failure of treatment of CDH, Perthes disease, slipped epiphysis of femoral head, cerebral palsy, anterior poliomyelitis, medical femoral torsion, postural defects, squinting patellae, apparent genu valgum, external tibial torsion , flat foot, and intoeing.^[1,2] The decreased femoral torsion has been shown to be associated with toeing out, rickets, chondrodystrophy.^[34] In the past few decades, researchers worldwide have used various methods to measure the angle. They measured the angle mechanically on cadaveric bones ^[256] as well as in patients by using roentgenography ^[7], ultrasound ^[18], computerised tomography ^[89] and MRI ^[10]. However earlier few studies have revealed that some of these methods are not accurate enough. The method described by Terjeson and Anda, 1987 ^[11] to measure the femoral anteversion by using ultrasound observed a poor correlation between the angle measured on dry bones and by USG. Murphy et al (1987) ^[9] revealed that the widely used CT method consistently underestimated the femoral anteversion by 10°. Another CT method was found to be reproducible within +/- 6°^[12]. Hence to decide the accuracy and validity of the data obtained by using these techniques and methods, data obtained mechanically from cadaveric femora is required. The data on angle of anteversion of femora of Indian origin is scarce. An earlier

study by Eckhoff, 1994 ^[13] revealed that the angle varies in populations. Thus the data from western countries may not be applicable to Indian population. Hence the Indian data needs to be established.

Various points and hence lines on femur are used by researchers to define the angle of femoral anteversion. Anatomically, the angle between the centre head neck line and retrocondylar line is taken as the angle of anteversion. Kirby et al, 1993^[2] in a study on 20 femora, revealed that the method using the surface landmarks on femur is more reproducible and hence they recommended it to measure the anteversion. However as the datum lines used to measure the angle are different, the values for femoral anteversion obtained by these two methods may differ. There is no documentation of comparative data by these two methods. We report such a study.

MATERIAL AND METHODS

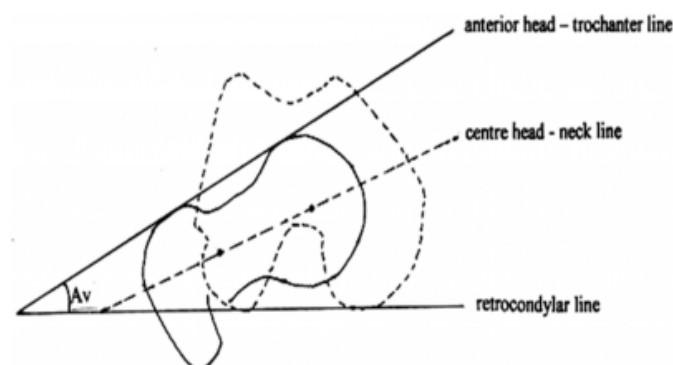
69 right and 75 left intact, dried adult human femora (unpaired) of unknown sex were studied. These femora are derived from the cadavers obtained from various parts of western India. Any femur that showed a significant bony or arthritic deformity was excluded from the study.

Each femur was placed with the posterior surface of its condyles and greater trochanter touching the smooth horizontal surface of the osteometric board. The centre head

neck line, anterior head - trochanter line and retrocondylar line were determined.

Figure 1

Figure 1: The Angle of Femoral Anteversion



Centre head - neck line: Centre of head was the centre of maximum anteroposterior thickness of head of femur. The centre of neck was the centre of maximum anteroposterior thickness at the base of the neck. Both these points were determined with the help of sliding caliper and were marked on the surface of head and neck respectively. The line passing through these points was the centre head - neck line. A fine needle was stuck with plasticine along this line. The femur was placed against the vertical wall of the osteometric board with a paper pinned to it; the lower edge of paper touching the horizontal surface of the osteometric board. The axis line was drawn corresponding to the needle.

Anterior head- trochanter line: Red ink was applied to a surface of a thin rectangular metal plate (15 cm X 5cm) which was then placed on the anterior surface of the upper end of femur such that the upper and the lower edge of the plate lie in horizontal planes. The surface to which ink was applied now touches the anterior most points on head and greater trochanter. The plate is now removed and a fine needle was stuck with plasticine at the marked points. The femur was placed against the vertical wall of the osteometric board with a paper pinned to it, the lower edge of paper touching the horizontal surface of the osteometric board. The axis line was drawn along the needle. This line lies in the plane passing through the anterior most points on head and greater trochanter and is anterior head-trochanter line.

Retrocondylar line: It passes through posterior most points of both condyles of femur and is represented here by the horizontal plane of the osteometric board and hence by the lower edge of the paper.

Using these reference lines, the angle of femoral anteversion

was measured by two different methods.

Method 1 – the angle between centre head neck line and retrocondylar line.

Method 2 -- the angle between anterior head-trochanter line and retrocondylar line.

It was measured with protractor to the accuracy of 1°

The angle was measured in all 144 femora by both methods. To minimise any possible error in the technique, the whole process was repeated. Each bone was removed from the osteometric board and repositioned for second set of measurements. Both readings were taken by same observer. The average of the two readings was taken as the angle of anteversion.

STATISTICAL ANALYSIS

The mean angle was calculated for both methods and compared by applying 'z' test. The reliability of each method was tested by calculating 95% confidence limit. The linear regression analysis was done to find conversion factors for method 1 and 2.. The 95% confidence limits were calculated. Pearsons' correlation coefficient was calculated.

OBSERVATIONS

Figure 2

Table 1: The Angle of Femoral Anteversion by Method 1 and Method 2

| Method 1 | | | | Method 2 | | | | p |
|---------------------|------|-------|--------|---------------------|-------|-------|-------|--------|
| Mean angle (degree) | | | | Mean angle (degree) | | | | |
| Right | Left | Total | S.D. | Right | Left | Total | S.D. | |
| 7.98 | 9.7 | 8.68 | ± 6.37 | 14.76 | 17.79 | 16.34 | ± 7.7 | <0.001 |

The mean angle of anteversion by method-1 was found to be 8.68° (+/-6.37) and of the total, 11 femora (7.64%) were found to be retroverted. Method -2 revealed the mean angle to be 16.34° (+/- 7.7). The retroversion was observed in 1 (0.69%) femur by this method.

DISCUSSION

The use of centre head neck line to measure the femoral anteversion is more logical and is widely accepted by researchers [25]. It has also been used to measure the angle in patients by using roentgenography [12], computerized tomography [89] and MRI [10]. While measuring the angle mechanically on dried bones, little difficulty may occur in

fixing the centre of head and centre of base of neck on the femur externally. However with the simple technique used in the present study, these points were obtained with ease. Measuring the anteversion by method- 2 was relatively precise as the anteriormost points on head and greater trochanter were identified without any ambiguity. This method can be used to measure the angle in patients by using ultrasound. However, while measuring the angle in patients with an abnormally large femoral head and greater trochanter (e.g. coxa magna) and deformed femoral head (e.g. severe osteoarthritis, severe Perthes disease) by this method will give erroneous results. In such a case, the angle can be measured with any other method.

This study shows that the method 2 is significantly more reliable than the method 1 (95% confidence limit of $\pm 0.84^\circ$) (Table2).

Figure 3

Table 2: Reliability of method 1 and method 2

| Method 1 | | | Method 2 | | |
|-----------------|------------|------------|-----------------|------------|------------|
| Mean difference | S.D. | 95% CL | Mean difference | S.D. | 95% CL |
| 2.11 | ± 1.54 | ± 2.14 | 0.45 | ± 0.61 | ± 0.84 |

The more accuracy of the method 2 is attributed to the landmarks used to measure the angle being relatively unambiguous. Moreover any potential inaccuracies in identifying central points is avoided. This finding is consistent with Kirby et al, 1993[2] (95% CL $\pm 0.4^\circ$). Likewise the reliability of method -1 in the present study (95% CL ± 3.20) is comparable with that of Kirby et al, 1993 (95% CL ± 2.14).

In the present study, the mean angle observed by method -2 [16.34°] is much higher than that of method -1 [8.68°], the difference being highly significant. [$P < 0.001$] (Table 1). The factor influencing this discrepancy is the choice of anterior head trochanter line or centre head neck line. A greater angle is usually given with use of anterior head trochanter line [fig. 1]. Thus different methods adopted do contribute in variation in the mean angle. Our finding is consistent with Kirby et al (1993). The mean angle of anteversion measured by method -1 in the present study is comparable with other Indian study by Kate & Robert (1963) (mean angle 8.8°). However compared with the anteversion in English [2] & African [13] population, the anteversion in Indian femora is considerably lower. Thus the angle varies in different populations. The

lower angle in Indian population may be a racial characteristic or it may be of developmental origin. The smaller angle can be attributed to the prolonged detorsion of the femur in Indians, probably due to functional and nutritional factors [5]. Kate and Robert (1963) have suggested that it may also be associated with the squatting habit of the Indians.

There is a worldwide disparity in opinions about bilateral differences in femoral anteversion. In the present study, with both method 1 and 2 the angle was found to be greater in left femora than right, the difference being statistically significant ($P < 0.05$) (Table 1). Many researchers noted the angle to be more on left side [14,15] while others found it to be more on right side [5,13]. However to have a concrete conclusion on this issue, a comparison should be done between the femoral anteversion of right & left femora of same individuals.

It was observed, that when measured on same femora, method -2 gave consistently higher values for femoral anteversion than method -1 by an average of 7.66° . This may be used as rough conversion factor to convert method -1 to method -2. However in 10.29% cases method -1 gave higher values than method -2. It may be because of presence of disproportionately large greater trochanter or small head of femur. When measured by method -1, 77.08 % femora were found to be anteverted between 0° & 15° . However, when measured by method -2, majority of them (67.47%) showed anteversion between 10° & 25° . The incidence of retroversion revealed by method -2 (0.69%) is considerably lower than by method -1 (7.64%). As explained earlier, the use of surface landmarks in method 2 has resulted in an increase in angle of anteversion. Hence many femora which showed presence of negative angle (retroversion) by method -1 revealed a positive angle (anteversion) by method -2. An extreme positive angle ($>25^\circ$) was observed in 12.5% femora by method -2 compared to none of them by method -1.

Thus when the same femora are studied by two methods, the mean angles, frequency of distribution, incidence of extreme torsion towards positive as well as negative side are different. So the data obtained by one method is not applicable and hence can not be compared directly with that obtained by the other method.

We conducted a linear regression analysis in all 144 femora & reached to the following conversion equations. A very highly significant correlation was observed between method

-1 & method -2 ($r = 0.565$, $P < 0.0000$).

Method -1 = $1.054 + 0.047 \times [\text{angle of anteversion by method -2}]$

or Method -2 = $10.408 + 0.683 \times [\text{angle of anteversion by method -1}]$

By using these equations, the anteversion measured by one method can be converted into another. It will make available the data obtained by either method for comparison and hence will help in understanding the aetiology of the “abnormal” anteversion. This study will help the clinicians to decide the “abnormal” angle in patients accurately which will lead to treatment of “abnormal” femoral torsion and conditions associated with it. The study will also be useful in general human osteology and forensic anthropology as far as the academics, clinical knowledge and research is concerned.

ACKNOWLEDGMENTS

The authors are thankful to Dr S M Sant, Professor & Head Dept of Anatomy B J Medical College Pune for his invaluable guidance during the study and help by making available the femora for the study.

CORRESPONDENCE TO

Dr. Shrikant A. Rokade C/o Adv. Kishor Y. Mane, 9, Vijay Housing Society, Ganeshkhind Road, Pune, Maharashtra. Pin 411 016. Phone 09981841068 e-mail drshrikantrokaade@yahoo.com

References

1. Upadhyay SS, Burwell RG, Moulton A, Small PG, Wallace WA. Femoral anteversion in healthy children : application of a new method using ultrasound. *J Anat* 1987; 169 : 49-61.
2. Kirby AS, Willace WA, Moulton A and Burwell RG. Comparison of four methods for measuring femoral anteversion. *Clinical Anatomy* 1993; 6 :280-288.
3. Morscher E. Development and clinical significance of the anteversion of the femoral neck. *Reconstr. Surg. Traumat.*, 1967, 9:107-125.
4. Jani L. Idiopathic anteversion of femoral neck. Follow up study of 51 patients on completion of growth. *Int. Orthop.* (SICOT), 1979, 2:283-292.
5. Kate, BR and Robert SL. The angle of femoral torsion. *Journal of Anatomical Society of India* 1963; 12, 8-11.
6. Yoshioka Y, Siu D, Cooke TDV. The anatomy of functional axes of the femur. *Journal of Bone and Joint Surgery* 1987; 69 A : 873-880.
7. Ruby L, Mital MA, O'Connor J and Patel U. Anteversion of the femoral neck. Comparisons of methods of measurements in patients. *Journal of Bone and Joint Surgery* 1979; 61 A: 46-51.
8. Lausten GS, Jorgensen F and Boesen J.. Measurement of anteversion of the femoral neck. Ultrasound and computerized tomography compared. *Journal of Bone and Joint Surgery* 1989 ;71-B:237-239.
9. Murphy SB, Simon SR, Kijewski PK, Wilkinson RH, Griscom NT.. Femoral anteversion. *J. Bone Joint Surg.* 1987 ; 69 - A:1169-1176.
10. Galbraith R T , Gelberman R H, Hajek P C, Baker L A, Sartoris D J, Rab G T , Cohen M S and Geriffin P P. Obesity and decreased femoral anteversion in adolescence . *J. Ortop Res.* 1987;5:523-526.
11. Terjeson T and Anda S. Femoral anteversion in children measured by ultrasound. *Acta Orthop. Scanda.*, 1987, 58:403-407.
12. Lee D Y, Lee C K and Cho T J . A new method for measurement of femoral anteversion. A comparative study with other radiographic methods. *Int. Orthop.*(SICOT)1992, 16:227-281.
13. Eckhoff DG, Kramer RC, Watkins JJ, Alongi CA, van Greven DP. Variation in femoral anteversion. *Clinical Anatomy* 1994; 7:72-75.
14. Le Damany P Les torsions osseuses. Leur role dans la transformation des membres. *Journal de l'anatomie et de la physiologie* .(1903) 39, 426-450
15. Pearson K and Bell J A study of the long bones of the English skeleton. Part I. The Femur, Ch.I-V, PP.23-30. Part I, Section II. The femur of man with special; reference to other primate femora. Ch. VII-X, pp.239-244. London: Cambridge University Press.

Author Information

Shrikant Rokade, M D ANATOMY

Associate Professor, Peoples College Of Medical Sciences & Research Centre

Arati K. Mane, MD MICROBIOLOGY

Scientist, National Aids Research Institute