

# Pleomorphic Adenoma Of The Lacrimal Gland Mimicking A Fungal Granuloma

A Gupta, S Bansal, S Kumar

## Citation

A Gupta, S Bansal, S Kumar. *Pleomorphic Adenoma Of The Lacrimal Gland Mimicking A Fungal Granuloma*. The Internet Journal of Ophthalmology and Visual Science. 2004 Volume 3 Number 2.

## Abstract

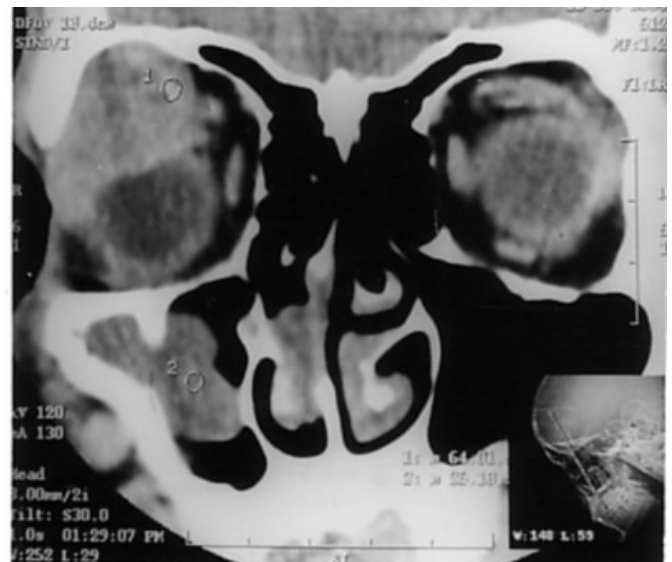
Lacrimal gland tumors are usually benign and slow growing. Pleomorphic adenoma is the most common epithelial tumor of the lacrimal gland accounting for about 12 % of all lacrimal gland lesions (1). Malignant transformation occurs in 10-12% of tumors, the majority of which are pleomorphic adenomas. (2,3). Pleomorphic adenoma of the lacrimal gland usually presents with a longstanding progressive painless process including downward displacement of the globe with axial proptosis (4). It occurs most commonly in adults during the fourth and fifth decades of life but rarely in adolescence (1, 4, 5). We describe an interesting case of a 22-year-old male with progressive painless loss of vision, proptosis over a short duration of two months, headache and nasal obstruction of long standing duration. His clinical presentation gave a false picture of fungal granuloma making the diagnosis very confusing. This is probably the first time that such an entity being reported.

## CASE REPORT

A 22-year-old male patient presented to the outpatient department of ENT, Head Neck Surgery department of the Post Graduate Institute of Medical Education and Research, Chandigarh with a painless gradual but progressive impairment of vision in his right eye along with proptosis and headache. The headache was in the right frontal region, continuous, occasionally throbbing, not associated with any nausea or vomiting. On further inquiry the patient complained of nasal obstruction on right side off and on for the last four years, presently continuous for the last 4 months. The patient had undergone two nasal surgeries, 4 years and 2 months back, the details of which were not known. There was no history of any fever or weight loss. The patient's medical history was unremarkable. Local ENT examination revealed a small polyp in the right nasal cavity. The remainder of the ENT examination was normal. Ophthalmological examination revealed a right eye proptosis of 5mm with inferomedial displacement of the eyeball. There was a 50% restriction of extraocular movements in superolateral gaze leading to diplopia. Visual acuity was 6/24 in the right eye and 6/6 in the left eye. Pupillary reflexes both direct and consensual were normal. Computed tomography (CT) showed a extraconal mass in the superolateral region of the right orbit with the thinning of the roof of the orbit. There was large polypoidal mass in the right maxillary sinus (Fig. 1)

## Figure 1

Figure 1: CT Scan of PNS (coronal view) showing the mass in the superolateral part of the right orbit along with a polyp in the right maxillary sinus.



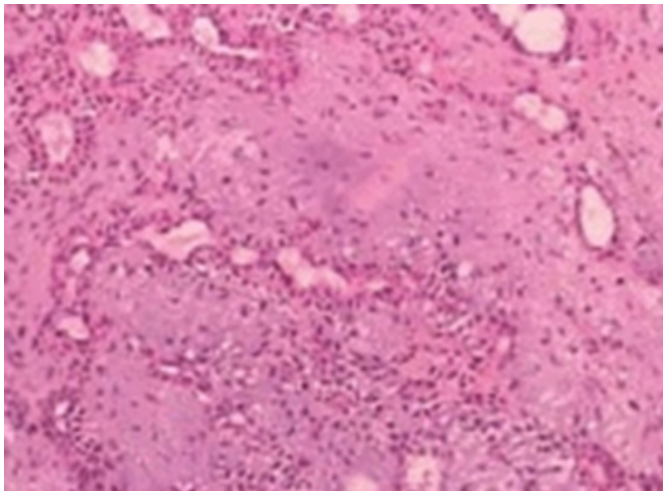
Considering the nasal symptoms of long standing duration and past history of nasal surgeries, with painless, progressive, gradual dimness of vision over a short duration of time and a extraconal mass in the right orbit and polypoidal lesions in the nasal cavity and maxillary antrum on the same side, a diagnosis of a fungal granuloma was made. The discontinuity in the mass in the orbit and nasal

cavity was attributed to the recent nasal surgery.

A right lateral orbitotomy was done under general anesthesia. It revealed a soft to firm pinkish mass in the superolateral part of the right orbit, slightly adherent to the roof of the orbit. It looked like a benign mass, most probably from the lacrimal gland and was removed in toto and sent for fungal culture and histopathology. During the dissection, the capsule was adherent at the roof of the orbit raising a suspicion of a malignancy. Fungal smear and culture came out to be negative. Histopathology showed a tumor with biphasic appearance resulting from the intimate admixture of epithelium and stroma. There is proliferation of epithelial and myoepithelial cells in the fibromyxoid stroma consistent with the diagnosis of pleomorphic adenoma (Fig. 2). After the final histopathology report, the small maxillary and nasal polyp was also removed which came out to be inflammatory in nature. The patient is under regular follow up and has been completely free of any symptoms for 10 months.

### Figure 2

Figure 2: Photomicrograph showing proliferation of epithelial and myoepithelial cells in the fibromyxoid stroma in a high power view.



### DISCUSSION

Pleomorphic adenoma accounts for most epithelial tumors of the lacrimal gland. Most of these occur in the orbital lobe (1,4,6), but can occur in the palpebral lobe also (4,7). Typical presentation of a pleomorphic adenoma of a lacrimal gland is a painless progressive proptosis of a long duration with diplopia and impairment of vision (4). Font and Gamel reported a mean age at presentation of 41 years and a male to female ratio of 1:1.3.17 (8). Our patient was a young male with similar complaints but of short duration with associated complaints of nasal obstruction and headache of long

duration. The patient had past history of nasal surgeries and findings of nasal polyps in nose and maxillary sinus along with a heterogeneous mass in the same side orbit on CT scan, which led us to believe it to be fungal mass.

A diagnostic biopsy preceding tumor excision may result in recurrence (4). A recurrence rate of 30% over five years has been reported if a prior biopsy is taken (8). Surgery is essential in the management of pleomorphic adenoma of the lacrimal gland. Malignant transformation has been reported 60 years after initial diagnosis in a lesion that was left untreated (2). The prognosis of pleomorphic adenoma of the lacrimal gland is good if the lesion is excised completely with an intact capsule. The recurrence rate of pleomorphic adenoma is as high as 30% after incomplete excision, and 20% of recurrent tumors eventually undergo a malignant change.

This case is being reported to highlight that though pleomorphic adenoma of the lacrimal gland typically presents with a longer duration of symptoms, rarely it may become symptomatic in a short span of time. Moreover the coexistence of a nasal polyposis as a second pathology had complicated its diagnosis, giving it a presentation of a fungal granuloma. This is a rare occurrence and is probably being reported for the first time as far as to our knowledge.

### CORRESPONDENCE TO

Dr. Sandeep Bansal Senio Research Associate Department of Otolaryngology PGIMER, Sector 12, Chandigarh – 160012 E mail: drsandeepb@rediffmail.com Phone: 91- 172- 2747837 Ext. 6760 Fax: 91- 172- 2744401, 2747837

### References

1. Shields CL, Shields JA, Eagle RC, Rathmell JP: Clinicopathologic review of 142 cases of lacrimal gland lesions. *Ophthalmology* 1989; 96: 431-439.
2. Shields JA, Shields CL. Malignant transformation of presumed pleomorphic adenoma of lacrimal gland after 60 years. *Arch Ophthalmol* 1987; 105: 1403-1405.
3. Wright JE, Rose GE, Garner A. primary malignant neoplasms of lacrimal gland. *Br. J Ophthalmol* 1992; 76: 395-400.
4. Rose GE, Wright JE. Pleomorphic adenoma of lacrimal gland. *Br. J Ophthalmol* 1992; 76: 395-400.
5. Mercado GJV, Gunduz K, Shields CL, Shields JA, Eagle RC. Pleomorphic adenoma of the lacrimal gland in a teenager. *Arch Ophthalmol* 1998; 116: 962-963.
6. De Souza C, Ogale SB, Shah KL, Sane SY. Pleomorphic adenoma of the lacrimal gland (a case report). *Post Grad Med* 1987; 33: 41-44.
7. Auran J, Jakobiec FA, Krebs W. Benign mixed tumor of the palpebral lobe of the lacrimal gland. Clinical diagnosis and appropriate surgical management. *Ophthalmology* 1988;95: 90-99.
8. Font RL, Gamel JW. Epithelial tumors of the lacrimal

gland: an analysis of 256 cases. In: Jakobiec FA, ed Ocular 787-805.  
and adenexal tumors. Birmingham: Aesculapius, 1978:

**Author Information**

**Ashok K. Gupta**

Associate Professor, Department of Otolaryngology, Head and Neck Surgery, Post Graduate Institute of Medical Education and Research

**Sandeep Bansal**

Senior Research Officer, Department of Otolaryngology, Head and Neck Surgery, Post Graduate Institute of Medical Education and Research

**Sudesh Kumar**

Senior Resident, Department of Otolaryngology, Head and Neck Surgery, Post Graduate Institute of Medical Education and Research