

Fatal Gliomatosis Cerebri In A Pregnant Woman

M Dharan, B Rappaport

Citation

M Dharan, B Rappaport. *Fatal Gliomatosis Cerebri In A Pregnant Woman*. The Internet Journal of Gynecology and Obstetrics. 2003 Volume 3 Number 1.

Abstract

Although there is no increased incidence of brain tumors in pregnancy, the initial manifestation of many of them, especially gliomas, has been found to occur during the first trimester [1,2,3,4]. Gliomatosis cerebri is an extremely rare condition which is characterized by wide-spread, diffuse neoplastic transformation of glial elements within the brain and brain stem [5]. The association of this rare entity with pregnancy and maternal fatality does not appear to have been reported previously.

CASE REPORT

A 33-year-old woman, married with three children was hospitalized with complaints of severe headaches and vomiting of sudden onset. Her past history revealed periodic episodes of headaches and personality disturbance that began six months following the first pregnancy. Of late, she has been taking 50 mg Largactil/day. On admission her general condition was good. Laboratory examination revealed: blood leukocytes 15,300, blood glucose 162 mg. She was given intravenous fluids and Paracetamol. Two hours later she was heard screaming loudly, and was found unconscious in her bed. A neurologic examination revealed irregular breathing with apneic spells and dilated, unresponsive pupils. Endotracheal intubation was performed and she was maintained on a respirator. A CT scan showed a diffuse area of hypo-density in the left hemisphere with compression of the right lateral ventricle and a mid-line shift to the right. She was hyperventilated and was administered mannitol, dexamethasone and antibiotics. Cytology of CSF was negative for tumor cells. The patient continued to be in coma and died on the third day.

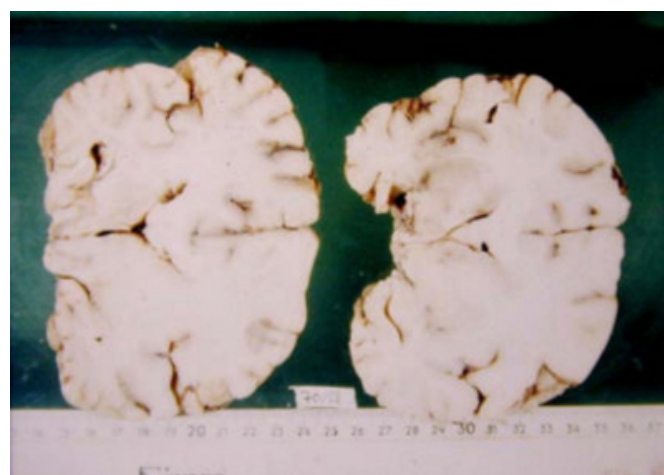
At autopsy, the pregnant uterus revealed a fetus measuring 4 cm in length. Foci of bilateral bronchopneumonia were detected in the lungs.

The brain weighed 1350 gm. The dura and leptomeninges

were unremarkable. There was diffuse flattening of gyri bilaterally, as well as the presence of cerebellar herniation grooves. Coronal sections revealed a diffuse effacement of the architecture, involving the left globus pallidus and putamen. The fornix appeared irregularly thickened and asymmetric (Fig. IA).

Figure 1

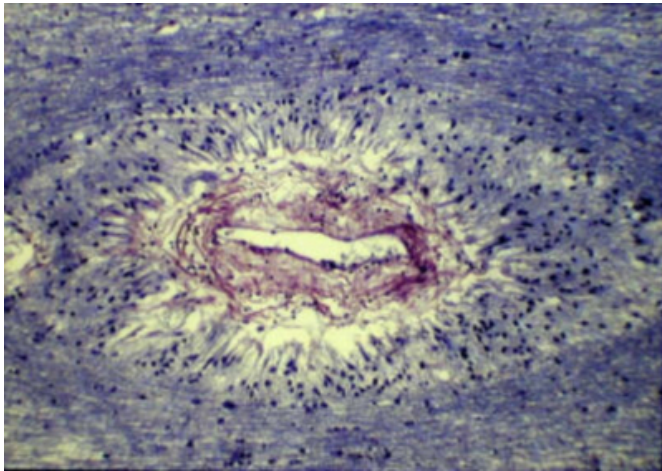
Fig. IA: Coronal sections of the brain showing diffuse enlargement of the left basal ganglia region and effacement of architecture in the adjoining subcortical area. Note irregular thickening and asymmetry of the fornix (Fig IA arrows)



Representative histologic sections demonstrated multiple areas of perivascular proliferation of darkly stained elongated tumor cells (Fig. IB).

Figure 2

Fig 1B: Histological section showing elongated dark-staining tumor cells in a perivascular palisade arrangement (Masson's trichrome stain x100, Fig 1B).



There was a diffuse infiltration of the adjacent subcortical white matter by similar tumor cells. In places, the cells showed marked atypia and focal anaplasia. Neoplastic foci were detected also in the corpus callosum and mid-brain. Paraffin embedded sections were stained by the immunoperoxidase method which yielded the following results: positive staining reaction to glial fibrillary acidic protein (GFAP), vimentin, estrogen receptor (ER), progesterone receptor (PR) and negative reaction to cytokeratin, HMB 45, epithelial membrane antigen (EMA) and neurofilament.

DISCUSSION

Statistical studies have shown that there is no higher incidence of primary brain tumors in pregnancy [1,2,3]. Gliomas, making up 40% of all brain tumors, have been found to make their initial manifestation during the first trimester [1,2,3], presumably due to tumor enlargement resulting from accelerated growth and/or intracellular fluid retention [1,2,3]. Hormonal factors have been implicated to play a causative role in this phenomenon [1,2,3]. Early diagnosis and precise localization of the tumor are of utmost importance since management has to be individually tailored in each case [1,2,3,4]. In cases of multiple tumors and in rare conditions such as gliomatosis cerebri in which neoplastic proliferation is wide-spread, avoidance of pregnancy may be the only way to assure long-term survival of the female patient [4]. The case presented in this report is an unusual histologic type of glioma, termed gliomatosis cerebri. Characteristically the tumor grows as ill-defined, diffuse overgrowth of neoplastic glial elements producing

effacement of the brain architecture [5]. The neoplastic process has been found to involve extensively the brain stem and subcortical structures including the fornix, globus pallidus and putamen. The tumor cells are elongated and dark-staining and tend to accumulate in perivascular locations. Areas of greater cellular pleomorphism and anaplasia, sometimes resembling glioblastoma multiforme, may also be noticed [5]. The gliomatous nature of the tumor can be demonstrated by the positive staining reaction of the tumor cells to GFAP and vimentin. The multifocal, perivascular growth pattern warrants its distinction from metastatic neoplasms. HMB 45 and EMA may be helpful in ruling out melanoma and carcinoma, respectively.

The functional significance of ER and PR positivity cannot be overemphasized. The aggravation of neurological symptoms during pregnancy and postovulatory period in women harboring brain tumors, has been attributed to hormonal effects [1,2,3,4]. Postpartum amelioration of symptoms and angiographically documented decrease of tumor size after confinement, are also points of argument favoring this theory [2]. In this patient, the periodic episodes of headaches and personality disturbances, may have been due to cyclical hormonal effects. Modern molecular therapeutic methods may hold some promise in patients with brain tumors that are not amenable to surgical or radiation therapy. Unexplainable behavior changes in women following pregnancy should arouse suspicion of a brain tumor, and appropriate diagnostic measures have to be undertaken. Women having uncommon brain tumors, such as the one described above, can be guarded against unexpected fatality only by careful monitoring and timely obstetric intervention.

CORRESPONDENCE TO

M. Dharan, M.D., Cytopathology Unit, Haemek Medical Center, Afula, 18101, Israel Tel: 04-6494419 Fax: 04-6494435 E-mail: dharan_m@clalit.org.il

References

1. Isla A, Alvarez F, Gonzalez A, Garcia-Grande A, Perez-Alvarez M, Garcia-Blazque S: Brain tumor and pregnancy. *Obstet Gynecol* 1997; 89: 19-23.
2. Roelvink NCA, Kamphorst W, Van Alphen HAM, Rao BR: Pregnancy-related primary brain and spinal tumors. *Arch Neurol* 1987; 44: 209-215.
3. Kempers RD, Miller RH: Management of pregnancy associated with brain tumors. *Am J Obst Gynecol* 1963; 87: 858-864.
4. Tewari KS, Cappuccini F, Asrat T et al. Obstetric emergencies precipitated by malignant brain tumors. *Am J Obstet Gynecol* 2000; 182: 1215-21.
5. Rubinstein LJ: Tumors of the central nervous system.

AFIP Atlas of Tumor Pathology: Fascicle 6, Series 2,

Washington DC, 1972; 42.

Author Information

Muralee Dharan, MD

Cytopathology Unit, Haemek Medical Center

Bruce Rappaport

Faculty of Medicine, Technion, Israel Institute of Technology