

conservative treatment of large tubercular abscess arising from spinous process and laminae

S Kumar, P Abbey, V Jaiswal

Citation

S Kumar, P Abbey, V Jaiswal. *conservative treatment of large tubercular abscess arising from spinous process and laminae*. The Internet Journal of Neurosurgery. 2008 Volume 6 Number 2.

Abstract

Posterior spinal tuberculosis is rare. A case of posterior spinal tuberculosis with large abscess without any neurological deficit was managed conservatively. He was relieved of pain and swelling subsided completely on anti-tubercular drugs

INTRODUCTION

The characteristic picture of spinal tuberculosis consists of destruction of adjacent vertebral bodies and the intervening disc. Rarely the tuberculosis may affect the posterior elements i.e neural arch without affecting the body. We came across a large tubercular abscess arising from the spinous process and the laminae of C3 vertebra which was managed conservatively. Because of its rare location, it is being reported.

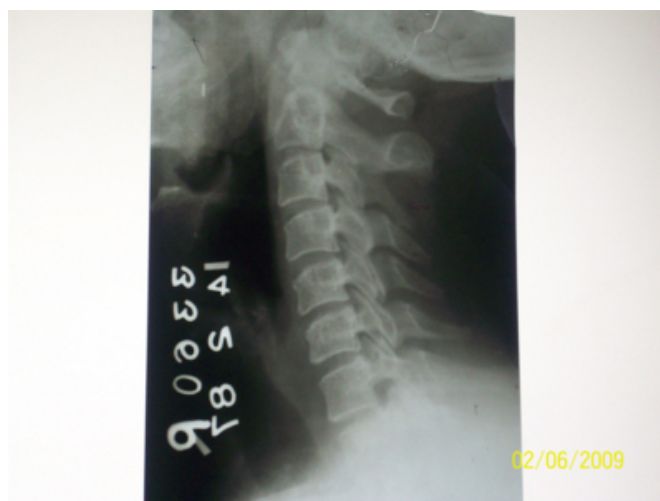CASE REPORT

A 39-year-old male attended neurosurgical service with complaints of swelling in the nape of neck of three months duration. On interrogation he complained of mild pain in the nape of neck. There was no history of trauma or fever. There was no history weakness in the limbs, bladder or bowel disturbances. On examination there was diffuse swelling over the nape of neck extending occiput to C7 spinous process. It was non-tender, ill defined and cystic in nature. There was no neurological deficit in the limbs.

Haemogram, blood chemistry, urine analysis and chest X-ray were normal. ESR was 10mm in the 1st hour. Montoux test was not done. X-ray cervical spine revealed destruction of C3 spinous process and soft tissue shadow posteriorly (Fig 1).

Figure 1

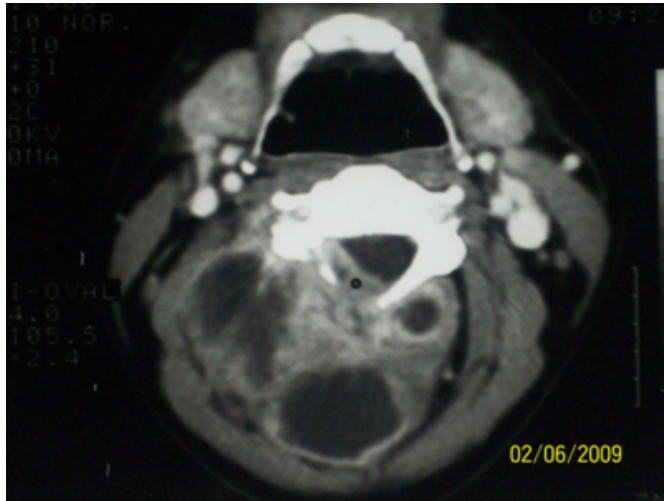
Figure 1: Lateral view of X-Ray cervical spine showing destruction of spinous process of C3 vertebra



Computed tomography revealed destruction of spinous process and laminae and large abscess in the intermuscular plain and small amount of granulation tissue in the epidural space posteriorly (Fig 2).

Figure 2

Figure 2: Computed tomography showing a large multilocular abscess with destruction of spinous process, lamina and extradural granulation tissue



In the absence of neurological deficit, it was decided to treat it conservatively with antitubercular drugs. On antitubercular drugs his swelling subsided completely and was relieved of pain as well and is symptom free for the last 22 years.

DISCUSSION

The involvement of posterior arch by tuberculosis is uncommon and has been reported from 04-10%¹⁻⁴. Most of the cases of posterior arch tuberculosis have been reported from Asian countries²⁻⁸ and few from the west⁹⁻¹⁶. Common presenting features of myelopathy, myeloradiculopathy or radiculopathy depending upon the site of involvement. Our patient did not have neurological deficit^{7,12}. Most often it involves dorsal, dorsolumbar or lumbar vertebral arch but involvement of posterior arch of cervical vertebra is rare.¹ Even large series also did not have even a single case of cervical vertebral arch involvement^{2,8}. Few cases of tuberculosis of neural arch of atlas and cervical vertebrae have been reported^{3,14,17}. Lamina is the most commonly affected followed by pedicle, spinous process and transverse processes⁸. Pure involvement of spinous process is very-very rare and has not been reported even in large series^{2,8}. Rarity of involvement of spinous process could be attributed to its small size. Yusof et al⁹ reported pedicle involvement in 64.5% cases, 75% of which had vertebral body collapse and infection had probably spread to pedicle by direct contiguous extension. Plain X-ray spine usually shows the destruction of the elements of arch and soft tissue shadow. Computed tomography can show the extent of disease. In our case plain X-ray revealed destruction of upper portion of spinous

process where as computed tomography revealed destruction of lamina as well as extradural granulation tissue.

As most of the cases are accompanied by neurological deficit, treatment consists of decompression combined with antitubercular drugs. Babhulkar et al reported three out of 22 cases who refused to undergo surgery were treated conservatively and they improved². We managed our case conservatively, as the patient did not have any neurological deficit; however, hemilaminectomy in a patient who had no neurological deficit on CT and MRI showed evidence of mass compressing the left side of thecal sac has been reported¹². Posterior spinal tuberculosis could be classified into primary and secondary type¹². The primary type is restricted to vertebral arch and spares the vertebral bodies and disk spaces. The secondary type is far more common and is caused by spread of vertebral tuberculosis to the vertebral arch.

Venous plexus present on the posterior surface of laminae and around spinous, transverse and articular processes anastomose with other vertebral plexuses and transmit infection to neural arch in this atypical form of spinal tuberculosis¹⁷.

CONCLUSION

A case with strong clinico-radiological evidence of tuberculosis can be managed with anti-tubercular drugs resulting in cure without resorting to surgery.

References

1. Adendorff JJ, Boeke EJ, Lazarus C. Pott's Paraplegia. South Afr Med Jour 1987;71:427-428.
2. Babhulkar SS, Tayade WB, Babhulkar SK. Atypical spinal tuberculosis. J.B.J.S 1984;88:23-26.
3. Rahman N, Al Arabi KM, Khan FA. Atypical forms of spinal tuberculosis. Acta Neurochir 1987;88:23-26.
4. Tuli SM, Srivastav TP, Varma BP, Singh GP. Tuberculosis of spine. Acta Orthop Scand 1967;38:445-448.
5. Arthornthurasook A, Chongpieboonpatana A. Spinal tuberculosis with posterior element involvement. Spine 1990;15:191-194
6. Pande KC and Babhulkar SS. Atypical spinal tuberculosis. Clin Orthop 2002; 398:67-74.
7. Kanojia RK, Sharma N, Kataria H. Quadripareisis secondary to posterior spinal tuberculosis of dorsal spine. Case report. J Orthop Sci 2007;12:93-96.
8. Kumar K. A clinical study and classification of posterior spinal tuberculosis. Internation Orthop 1985;9:147-152.
9. Mallolas J, Gatell JM, Rovira M et al. Vertebral arch tuberculosis in two human immunodeficiency virus seropositive heroin addicts. Arch Inter Med 1988;148:1125-1127.
10. Ragland RL, Abdelwahab IF, Braffman B, Moss DS. Posterior spinal tuberculosis: A case report. Am Jour Neuroradiol 1990;11:612-613.
11. Adelwahab IF, Camins MB, Hermann G, Klein MJ.

Vertebral arch or posterior spinal tuberculosis. Skelet Radiol 1997;26:737-740.

12. Nasser I, Mahi M, Semlali S et al. Tuberculosis of the posterior vertebral arch: A case report. J Neuroradiol 2002;29:204-207.

13. Akhaddar A, Gazzaz M, Jiddane M et al. Tuberculous ostietis of the posterior vertebral arch: A case report. J Radiol 2001;82:257-260.

14. Lin Greenburg A, Cholankeril J. Vertebral arch destruction in tuberculosis: CT features. J Comput

Assist Tomogr 1990;14:300-302.

15. Corea JR, Jamimi TM. Tuberculosis of the arch of the atlas: Case report. Spine 1987; 12:608-611

16. Acharya S and Ratra GS. Posterior spinal cord compression: outcome and results. Spine 2006; 31: E574-578.

17. Batson OV. The function of vertebral veins and their role in the spread of metastases. Ann Surg 1940; 112:138-149.

Author Information

Sushil Kumar, M.S, MCh

Director-Professor, Department of Neurosurgery, G.B.Pant Hospital

Pooja Abbey, MD,DNB

Department of Radiology, All India Institute of Medical Sciences

Vishwadarshi Jaiswal, M.S, MCh

Department of Neurosurgery, G.B. Pant Hospital