

Malformations Associated With Spina Bifida

L Pantanowitz, M Sur

Citation

L Pantanowitz, M Sur. *Malformations Associated With Spina Bifida*. The Internet Journal of Pediatrics and Neonatology. 2003 Volume 4 Number 1.

Abstract

Patients with spina bifida have a high incidence of associated anomalies. The reason is that initial developmental errors arise early on embryologically, so that the resulting malformations may involve any of the germ layers. In addition, spina bifida has also been linked with numerous syndromes. This article reviews all the syndromes and anomalies known to be associated with spina bifida arising from ectoderm, mesoderm and endoderm. It is important for clinicians to be aware of these associated syndromes and anomalies as many of them are correctable, and if left untreated can significantly alter morbidity and mortality.

INTRODUCTION

Spina bifida (SB) is a neural tube defect caused by the failure of the fetus's spine to close properly during the first month or pregnancy. SB occurs more frequently dorsally (SB dorsalis) than ventrally (SB ventralis). The simplest form where epithelialized skin covers the hidden spinal lesion is known as SB occulta. With more severe cystic lesions (SB cystica or aperta) meninges may herniate through the vertebral defect to form a sac (meningocele), which may also contain the spinal cord and nerve trunks (myelomeningocele). SB, like most other congenital malformations, seldom occurs singly (Till, 1969; Stark, 1977). Patients with SB therefore have a high incidence of associated anomalies. This is particularly the case with more severe and cephalad spinal lesions (Kalien et al,1998). Many of these aberrations have been reproduced by experimental teratologists (Katz,1984). The initial error(s) occurs very early on embryologically so that the resulting malformations may involve all three germ layers. These anomalies are usually less evident initially than the spinal lesion. SB has also been shown to be associated with numerous syndromes (table 1) and a constellation of clinical conditions including dwarfism (Bethem et al,1980), recurrent infections (Graf and Oleinik,1997), latex allergy (Szepfalusi et al,1999), malignant hyperthermia (Anderson et al,1981) and attention deficit disorder (Wolfe,1963). It is important for clinicians to be aware of these anomalies because many of them are correctable and if left untreated can significantly alter morbidity and mortality (Date et al,1993).

Figure 1

Table 1: Syndromes known to be associated with spina bifida

Adams-Oliver Syndrome (Romani et al,1998)
Antley-Bixler Syndrome (Chun et al,1998)
Asplenia Syndrome (Van Went et al,1977)
Becker Naevus Syndrome (Happle and Koopman,1997)
Down's Syndrome (Gal,1971; Szabo et al,1986)
Dubowitz Syndrome (Hansen et al,1995)
Edward's Syndrome (Trisomy 18)
Gorlin Syndrome (Ratcliffe et al,1995)
Jarcho-Levin Syndrome (Giacola and Say,1991)
Klippel-Feil Syndrome (Jablonski,1969)
Larsen Syndrome (Anderson,1997)
Marfan's Syndrome (Ortino et al,1988)
Mayer-Rokitansky-Kuster-Hauser Syndrome (Strubbe et al,1992)
Neu-Laxova Syndrome (Naveed et al,1990)
Patau Syndrome (Rodriguez et al,1990)
13q- Syndrome (Chemke et al,1978)
VATER Syndrome (Quan and Smith,1973)
Velo-cardio-facial Syndrome (Nickel et al, 1996)
Waardenburg Syndrome (De Saxe et al,1984)
XX-Agonadism Syndrome (Kennerkrecht et al,1997)

ANOMALIES FROM NEUROECTODERM

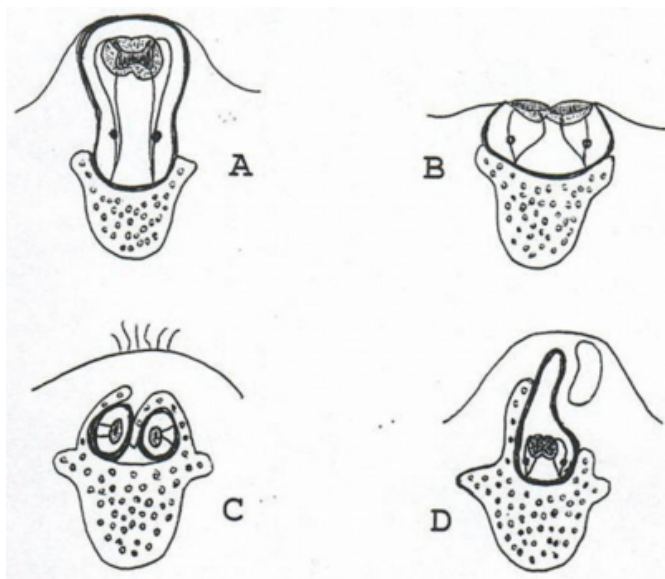
SB occurs most frequently with other congenital malformations of neuroectodermal origin. A meningocele involving only meninges, and not any neural elements, is relatively rare. The majority of cases of SB cystica usually have a Myelomeningocele (Figure 1A). Myelomeningoceles may impair the development of entrapped nerve trunks (Moore,1988), causing marked neurological deficit inferior to the level of the lesion. Motor and/or sensory loss in a few

affected patients, however, may also stem from functionally significant defects of the underlying spinal cord.

Abnormalities of the overlying skin (in SB occulta), such as dimpling or pigmentation, should alert the clinician to the possibility of an associated intraspinal dysraphism (Frank and Fixsen, 1980). In myeloschisis (or rachischisis) the spinal cord is completely exposed to the exterior (Figure 1B). Total rachischisis is incompatible with life. The attachment of the spinal cord to the meningocele sac (tethered cord syndrome) prevents the normal cephalad migration of the spinal cord with growth of the fetus (Steinbok, 1995). Diastematomyelia (split spinal cord with each half in its own dural tube) (Figure 1C), diplomyelia (duplicated portion of the spinal cord enclosed within a single dural tube) and hydromyelia (dilatation of the central spinal canal) are all commonly associated with SB (Azimullah et al, 1991). Syringomyelia (a tubular cavitation of the spinal cord extending over many segments) occurs in 15-20% of children with SB (Dias and Li, 1998), particularly in those with uncompensated hydrocephalus. Some individuals may have an abnormally elongated spinal cord which terminates in the sacral region (low conus medullaris). In addition, there may be symmetrical glial proliferation and malalignment of the white matter in the conus medullaris ("myelodysplasia") (Figure 1D).

Figure 2

Figure 1: Cross section diagrams of spinal lesions seen in spina bifida. (A) Myelomeningocele. (B) Myeloschisis. (C) Diastematomyelia with a spur and hypertrichosis in association with SB occulta. (D) Myelodysplasia with a meningocele and subcutaneous lipoma.



There are also many malformations of the brain which one

can expect to find in association with SB. In the forebrain, micropolygyria (numerous but small cerebral gyri) is present in nearly all cases with SB (Brocklehurst, 1978). Histological examination of the cerebral cortex reveals cortical heterotopia, with clusters of cells in abnormal positions. Dilatation of the lateral ventricles in a "vampire bat" configuration, usually secondary to hydrocephalus, is very common (Zimmerman et al, 1979). This is often accompanied by thinning of the cortex and corpus callosum. There are several reports of an associated pathological corpus callosum with related cognitive problems in SB patients (Christensen and Rand-Hendriksen, 1998). Although children with SB have a normal distribution of intelligence, there is a slightly increased incidence of mentally retarded individuals (Leonard and Freeman, 1981). In early cases there may also be fusion of the thalami to form an enlarged massa intermedia, which becomes attenuated with dilatation of the third ventricle. In the midbrain one may encounter tectal beaking and stenosis of the aqueduct of Sylvius, with forking and periaqueductal gliosis (Brocklehurst, 1978).

SB cystica is associated with hydrocephalus in about 80-90% of cases (Cook, 1971; Lindseth, 1996).

Approximately one third of these individuals only have mild hydrocephalus that may arrest spontaneously. However, the presentation of raised intracranial pressure in some cases may be delayed (Vaishnar and Mackinnon, 1986). Analysis of the CSF protein pattern in SB children with hydrocephalus revealed a barrier damage in half of these cases, a degenerative pattern in 19% of cases and, less commonly, evidence of a block or normal pattern (Cerdeira and Bassauri, 1980). The cause of hydrocephalus in SB is related to an associated Arnold-Chiari (AC) malformation of the hindbrain in most cases, particularly the type II malformation (Zimmerman et al, 1979), where the brainstem and cerebellar vermis herniate through the foramen magnum, so that the fourth ventricle opens into the cervical spinal canal (Williams, 1975; Caviness, 1976; Warkany and O'Toole, 1981). The most common site of obstruction to the normal passage of cerebrospinal fluid (CSF) is the cerebral aqueduct (McCoy et al, 1967). The etiology of the virtually constant association between SB and the AC malformation remains controversial. The association is best explained embryologically by a massive shift in the cranio-caudal direction of the developing elements of the brain stem, cerebellum and spinal cord (Roessmann, 1983). A downward shift of the induction for the rhombencephalon will lead to formation of the brain stem in the spinal canal.

This causes a proportionate shift in closure of the neural tube which culminates in caudal schisis (Jennings et al,1982). The more cephalad and extensive the spinal defect, the more likely it is to be accompanied by the AC malformation. While an AC malformation is almost invariably found when a myelomeningocele exists, SB occulta is almost never accompanied by this malformation. The wall of the meningocele is thought to act as a mechanism for absorption of CSF into the bloodstream, because occasionally hydrocephalus is only slight in the presence of the AC malformation (Potter and Craig,1976). This may explain why postnatal surgical closure of the sac can lead to the development or aggravation of hydrocephalus (Potter and Craig,1976; Lindseth,1996). Paradoxically, fetal surgery to correct this caudal defect early on may reverse the AC malformation, and therefore the need for a shunt to prevent hydrocephalus (Adzick et al,1998; Tulipan and Bruner,1999).

Neurofibromatosis has also been described in association with SB and so too has sacral agenesis and sacrococcygeal teratomas (Lahdenne et al,1991).

ANOMALIES FROM ECTODERM

Very few malformations arising from ectoderm are associated with SB. There are some local skin defects which occur in the region of the spinal defect such as a dysplastic dermis over a meningocele, sacrococcygeal hypertrichosis (sometimes known as a “faun's tail”), excess pigmentation and other cutaneous appendages (Yamada et al,1996). There may also be a dermal sinus associated with the spinal lesion. Because this sinus communicates with the spinal theca it may predispose the patient to meningitis. Rarely, some surface ectodermal cells may become incorporated into the neural tube during closure of the caudal neuropore (Moore,1988). These cells may give rise to a spinal cord tumor known as an intramedullary dermoid.

ANOMALIES FROM MESODERM

Associated with abnormalities derived directly from the neural tube are those derived from the adjacent mesoderm. These are most apparent in the structure of the cranial vault, vertebrae and ribs. Splaying of sutures and shallowness of the posterior cranial fossa are associated with hydrocephalus and the AC malformation. The anterior fontanelle is often extended well down into the metopic suture of the frontal bone giving it a “keyhole” appearance. Also common is the occurrence of the so-called lacunar skull, where the skull is thinner than normal and there are depressed, non-ossified

perforations on the inner surfaces of the flat bones of the calvaria. The skull base may also be grossly abnormal with a large foramen magnum, large jugular foramina and flattened petrous temporal bones. The tentorium cerebelli may be attached very low and the falx cerebri in these patients is nearly always shallow. Children with a cleft lip and palate also appear to have a high (~13%) incidence of cervical SB (Loder,1996).

Anomalies of the vertebral column anywhere along its length are also common (Sherik et al,1986). Most deformities of the spine may only become apparent as children reach their adolescent growth spurt. If the vertebral bodies are distorted in the antero-posterior direction they may give rise to a congenital kyphus. This often occurs at the level of the SB lesion, where the ventral aspects of the vertebrae fail to lengthen. In a similar fashion, when the vertebrae underlying an asymmetrical hemi-myelomeningocele are retarded in unilateral growth, this becomes the concavity of a fixed primary scoliosis (the convexity being on the side with the more normal cord). Tethered cord syndrome and hydrosyringomyelia may also lead to progressive scoliosis. A midline bony or cartilaginous spur and hemivertebrae are suggestive of an associated diastematomyelia. Bifurcation, duplication and absence of ribs is also common in severe SB cases. When the spinal cord is involved the lower limbs are usually the site of such orthopedic deformities as congenital dislocation of the hip, anterior dislocation of the knee and contractures around the knee joint, pes cavus, equinovarus, calcaneus deformities and hammer toes (Sharrard,1968).

Associated anomalous soft tissue conditions are less common. They include intraspinal lipomas (which may connect to larger subcutaneous lipomas), lipomeningocele (in which the sac contains a lipoma that is intimately involved with the sacral nerves), primary duplication and agenesis of ureters and kidneys and derivatives of mesonephros, which may be found among abnormal tissue at the SB defect. There may be a cluster of dilated blood vessels (area vasculosa) on the surface of the neural plaque in dysplastic cases. More importantly, the blood vessels situated around the brain stem may be abnormal. Usually the vertebralbasilar arteries are caudally displaced. In fact, the posterior inferior cerebellar arteries may stretch far down into the cervical spinal canal. Finally, it is not uncommon for the superior sagittal sinus to be duplicated, the vein of Galen to be elongated and the straight sinus relatively shortened.

ANOMALIES FROM ENDODERM

Apart from retrorectal cystic hamartomas (tailgut cysts) which may occur in association with SB (Bale,1984), SB ventralis is the predominant condition in which one is likely to find an associated enterogenous (neurenteric) cyst (Norman and Ludwin,1991; Prasad et al,1996). These cysts develop from incomplete separation of the neural tube and endodermis during the third week of gestation. When they occur, the ventral SB lesion usually emanates in the bodies of the cervicothoracic vertebrae. The enterogenous cyst, located ventral to the cord, may be intramedullary, attached to the meninges or to the vertebrae. Sometimes there may be many vertebral defects, allowing the cyst to communicate with other intrathoracic cysts lined with oesophageal, gastric or intestinal epithelium. They are commonly associated with the Klippel-Feil syndrome (Whiting et al,1991), with symptoms usually noticeable only sometime in adulthood (Rougerie et al,1999).

References

- r-0. Adzick NS, Sutton LN, Cromblehome TM, Flake AW (1998). Successful fetal surgery for spina bifida. *Lancet* 352: 1675-1676
- r-1. Anderson T (1997). Earliest evidence for arthrogryposis multiplex congenita or Larsen syndrome? *Am J Med Genet* 71:127-129
- r-2. Anderson TE, Drummond DS, Breed AL, Taylor CA (1981). Malignant hyperthermia in myelomeningocele: a previously unreported association. *J Pediatr Orthop* 1:401-403
- r-3. Azimullah PC, Smit LM, Rietveld-Knol E, Valk J (1991). Malformations of the spinal cord in 53 patients with spina bifida studied by magnetic resonance imaging. *Child Nerv Syst* 7:63-66
- r-4. Bale PM (1984). Sacrococcygeal developmental abnormalities and tumors in children. *Perspect Pediatr Pathol* 8:9-56
- r-5. Bethem D, Winter RB, Lutter L (1980). Disorders of the spine in diastrophic dwarfism. *J Bone Joint Surg [Am]* 62:529-536
- r-6. Brocklehurst G (1978). Spina bifida. Prenatal diagnosis of neural tube defects. In: *Handbook of clinical neurology: congenital malformations of the spine and spinal cord*. Amsterdam: North Holland Publishing Company; 519-578.
- r-7. Caviness VS (1976). The Chiari malformations of the posterior fossa and their relation to hydrocephalus. *Dev Med Child Neurol* 18:103-116
- r-8. Cerda M, Bassauri L (1980). Isoelectric focusing of cerebrospinal fluid proteins in children with non-tumoral hydrocephalus. *Childs Brain* 7:169-181
- r-9. Chemke J, Fishel E, Zolish M, Sagiv M (1978). Multiple skeletal anomalies in the "13q-" syndrome. *Eur J Pediatr* 128:27-31
- r-10. Chrisstensen B, Rand-Hendriksen S (1998). The significance of associated malformations of the central nervous system in myelomeningocele. *Tidsskr Nor Laegeforen* 10:4232-4234
- r-11. Chun K, Siegel-Bartlett J, Chitayat D, Phillips J, Ray PN (1998). FGFR2 mutation associated with clinical manifestations consistent with Antley-Bixler syndrome. *Am J Med Genet* 77:219-224
- r-12. Cook RCM (1971). Spina bifida and hydrocephalus. *Br Med J* 4:796-799
- r-13. Date I, Yaggu Y, Asari S, Ohmoto T (1993). Long-term outcome in surgically treated spina bifida cystica. *Surg Neurol* 40:471-475
- r-14. De Saxe M, Kromberg JG, Jenkins T (1984). Waardenburg syndrome in South Africa. Part I. An evaluation of the clinical findings in 11 families. *S Afr Med J* 66:256-261
- r-15. Dias MS, Li V (1998). Pediatric neurosurgical disease. *Pediatr Clin N Amer* 45:1539-1578
- r-16. Frank JD, Fixsen JA (1980). Spina bifida. *Br J Hosp Med* 24:422-438
- r-17. Gal I (1971). Mongoloid features associated with spina bifida. *Dev Med Child Neurol* 13:380-383
- r-18. Giacoia GP, Say B (1991). Spondylocostal dysplasia and neural tube defects. *Am J Med Genet* 28:51-53
- r-19. Graf WD, Oleinik OE (1997). Cell cycle properties in lymphocytes from children myelomeningocele. *Eur J Pediatr Surg* 1:15-17
- r-20. Hansen KE, Kirkpatrick SJ, Laxova R (1995). Dubowitz syndrome: long-term follow-up of an original patient. *Am J Med Genet* 55:161-164
- r-21. Happel R, Koopman RJ (1997). Becker nevus syndrome. *Am J Med Genet* 68:357-361
- r-22. Jablonski S (1969). *Illustrated dictionary of eponymic syndromes and diseases*. Philadelphia: WB Saunders
- r-23. Jennings MT, Clarren SK, Kokich VG, Alvord EC (1982). Neuroanatomic examination of spina bifida aperta and the Arnold-Chiari malformation in a 130-day human fetus. *J Neurol Sci* 54:325-338
- r-24. Kalien B, Robert E, Harris J (1998). Associated malformations in infants and fetuses with upper or lower neural tube defects. *Teratology* 57:56-63
- r-25. Katz MJ (1984). CNS effects of mechanically produced spina bifida. *Dev Med Child Neurol* 26:617-631
- r-26. Kennerkrecht I, Matfeldt T, Paulus W, Nitsch C, Negri G, Barbi G, Just W, Schwemmle S, Vogel W (1997). XX-agonadism in a fetus with multiple dysraphic lesions: a new syndrome. *Am J Med Genet* 70:413-414
- r-27. Lahdenne P, Heikinheimo M, Jaaskelainen J, Merikanto J, Heikkila J, Siimes MA (1991). Vertebral abnormalities associated with congenital sacrococcygeal teratomas. *J Pediatr Orthop* 11:603-607
- r-28. Leonard CO, Freeman JM (1981). Spina bifida: a new disease. *Pediatrics* 68:136-137
- r-29. Lindseth RE (1996). Myelomeningocele. In: Lovell and Winter's pediatric orthopaedics. 4th ed. Morrissey RT, Weinstein SI (editors). Philadelphia: Lippincott-Raven Publishers;503-536.
- r-30. Loder RT (1996). The cervical spine. In: Lovell and Winter's pediatric orthopaedics. 4th ed. Morrissey RT, Weinstein SI (editors). Philadelphia: Lippincott-Raven Publishers; 739-779.
- r-31. McCoy WT, Simpson DA, Carter RF (1967). Cerebral malformations complicating spina bifida. Radiological studies. *Clin Radiol* 18:176-182
- r-32. Moore KL (1988). *The developing Human. Clinically oriented embryology* 4th Ed. Philadelphia: WB Saunders Company
- r-33. Naveed M, Majunath CS, Sneenivas V (1990). New manifestations of Neu-Laxova syndrome. *Am J Med Genet* 35:55-59
- r-34. Nickel RE, Magenis RE (1996). Neural tube defects and deletions of 22q11. *Am J Med Genet* 66:25-7
- r-35. Norman MG, Ludwin SK (1991). Congenital malformations of the nervous system. In: *Textbook of*

- neuropathology. 2nd Ed. Davis RC, Robertson DM (editors). Baltimore: Williams & Wilkins; 207-280.
- r-36. Ortino O, Bonani F, Ruffino C, Maiolino L, Tedoldi A (1988). Hepato-renal polycystosis, Marfan's syndrome and spina bifida occulta: a complex association. *Minerva Med* 79:1105-1107
- r-37. Potter EL, Craig JM (1976). *Pathology of the fetus and the infant* 3rd Ed. Chicago: Year Book Medical Publishers
- r-38. Prasad VS, Reddy DR, Murty JM (1996). Cervico-thoracic neurenteric cyst: clinicopathological correlation with embryogenesis. *Childs Nerv Syst* 12:48-51
- r-39. Quan L, Smith DW (1973). The VATER association. *J Pediatr* 82:104-107
- r-40. Ratcliffe JF, Shanley S, Chenevix-Trench G (1995). The prevalence of cervical and thoracic congenital skeletal abnormalities in basal cell naevus syndrome. *Br J Radiol* 68:596-599
- r-41. Rodriguez JI, Garcia M, Marales C, Morillo A, Delicado A (1990). Trisomy 13 syndrome and neural tube defects. *Am J Med Genet* 36:513-516
- r-42. Roessmann U (1983). The embryology and neuropathology of congenital malformations. *Clin Neurosurg* 30:157-164
- r-43. Romani J, Puig L, Aznar G, Demestre X, Altirriba O, Alomar A (1998). Adams-Oliver syndrome with unusual central nervous system alterations. *Pediatr Dermatol* 15:48-50
- r-44. Rougerie C, Chazerain P, Arthuis F, Chicheportiche V, Ziza JM (1999). Spinal neurenteric cyst revealed by a cauda equina syndrome. *Presse Med* 28:229-230
- r-45. Sharrard WJW (1968). Spina bifida and its sequelae. *S Afr Med J* 42:915-918
- r-46. Sherik HH, Charney E, Pasquariello PD, Shut L, Gibbons PA (1986). Hydrocephalus, cervical cord lesions, and spinal deformity. *Spine* 11:340-342
- r-47. Stark GD (1977). *Spina bifida. Problems and management*. Oxford: Blackwell Scientific Publications
- r-48. Steinbok P (1995). Dysraphic lesions of the cervical spinal cord. *Neurosurg Clin N Amer* 6:367-376
- r-49. Strubbe EH, Lemmens JA, Thijn CJ, Willemsen WN, van Toor BS (1992). Spinal abnormalities and the atypical form of the Mayer-Rokitansky-Kuster-Hauser syndrome. *Skeletal Radiol* 21:459-462
- r-50. Szabo J, Szemere G, Gellen J, Herczeg J (1986). Diagnosis of trisomy-21 associated spina bifida and cheilognathopalatoschisis during the first trimester of pregnancy. *Orv Hetil* 127:2015-2018
- r-51. Szepefalusi Z, Seidl R, Bernert G, Dietrich W, Spitzauer S, Urbanek R (1999). Latex sensitization in spina bifida appears disease-associated. *J Pediatr* 134:344-348
- r-52. Till K (1969). Spinal dysraphism. A study of congenital malformations of the lower back. *J Bone Joint Surg* 51B:415-422
- r-53. Tulipan N, Bruner JP (1999). Fetal surgery for spina bifida. *Lancet* 353:406-407
- r-54. Vaishnar A, Mackinnon AE (1986). Progressive hydrocephalus in teenage spina bifida patients. *Z Kinderchir* 41:36-37
- r-55. Van Went JJ, van Went GF, Delleman JW, Becker AG (1977). Spina bifida and so-called asplenia syndrome occurring separately in sibs. *Teratology* 15:195-198
- r-56. Warkany J, O'Toole BA (1981). Experimental spina bifida and associated malformations. *Childs Brain* 8:18-30
- r-57. Whiting DM, Chou SM, Lanzieri CF, Kalfas IH, Hardy RW (1991). Cervical neurenteric cyst associated with Klippel-Feil syndrome: a case report and review of the literature. *Clin Neuropathol* 10:285-29
- r-58. Williams B (1975). Cerebrospinal fluid pressure-gradients in spina bifida cystica, with special reference to the Arnold-Chiari malformation and aqueductal stenosis. *Dev Med Child Neurol* 35:138-150
- r-59. Wolfe PH (1963). Development and motivational concepts in Piaget's sensory-motor theory of intelligence. *J Am Acad Child Adolesc Psychiatry* 2:225-228
- r-60. Yamada S, Mandybur GJ, Thompson JR (1996). Dorsal midline proboscis associated with diastematomyelia and tethered cord syndrome. Case report. *J Neurosurg* 85:709-712
- r-61. Zimmerman RD, Breckbill D, Dennis MW, Davis DO (1979). Cranial CT findings in patients with meningocele. *Am J Roentgen* 132:623-629

Author Information

Liron Pantanowitz

Department of Pathology, Beth Israel Deaconess Medical Center, Harvard Medical School

Monalisa Sur

Department of Pathology and Molecular Medicine, McMaster University