

# Splenogonadal Fusion In Bilateral Cryptorchidism: A Case Report

I Meteoglu, E Levi, M Erku<sup>o</sup>, N Çulhaci, M Yazici

## Citation

I Meteoglu, E Levi, M Erku<sup>o</sup>, N Çulhaci, M Yazici. *Splenogonadal Fusion In Bilateral Cryptorchidism: A Case Report*. The Internet Journal of Pathology. 2002 Volume 2 Number 2.

## Abstract

Splenogonadal fusion is a rare congenital malformation in which there is an abnormal fusion between spleen and the gonad or derivatives of the mesonephros. Approximately 140 cases have been reported. We describe a child with bilatereal cryptorchidism in whom splenic gonadal fusion presented as an testicular torsion.

## INTRODUCTION

Splenic gonadal fusion is a rare anomaly that was first described in 1883. Although rare, this entity should be cosidered in the differential diagnosis of scrotal masses in children. This entity manifest itself continuous and discontinuous. In one-third of all reported cases splenogonadal fusion is associated with other congenital defects.

## CASE REPORT

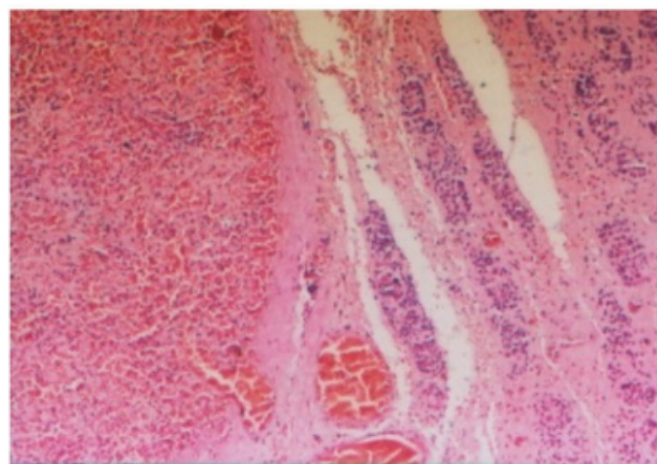
An Eight-month-old infant was referred for evaluation bilateral cryptorchidism. He was the product of an uncomplicated pregnancy, He was normally developed for his age. Findings on physical examination were unremarkable except for bilateral polydactyly. He was hospitalized for unexplained nausea, vomiting and abdominal pain. Testicular torsion was considered to be the most likely diagnosis based on an ultrasonographic examination. He underwent a left inguinal exploration. A red-brown encapsulated mass was seen to be fused to the left testis. No connection between the spleen and this mass could be seen. The testis tortion was confirmed.

Despite the correction of the torsion, circulation to the organ could not be restored. A decision was made to remove the testis. The right testis was located at the right inguinal canal and was pulled down. Pathological examination showed a testicle 1 cm in length with an attached encapsulated red-brown nodule measuring 1,2 cm in diameter, located in the upper pole. Microscopic examination of the mass revealed normal spleen tissue, separated from the testicle by a fibrous capsule(Figure 1). The histological appearance was

consistent with splenogonadal fusion-discontinuous type.

## Figure 1

Figure 1: Splenogonadal fusion, H&E x100



## DISCUSSION

Slenogonadal fusion is a rare, but important lesion which should be considered in the differential diagnosis of scrotal masses and unexplained abdominal pain[<sub>1</sub>]. This anomaly has been subtyped into continuous and discontinuous forms (as in our case), depending on the presence or absence of a cord connecting the accessory splenic tissue with the normal spleen[<sub>2</sub>]. About one fifth of the cases have other congenital abnormalities such as limb defects, micrognathia, cardiac malformations[<sub>3,4,5</sub>]. Continuous type is slightly more common and most cases have concomitant major congenital anomalies. In addition, cryptorchidism also occurred in one fifth of the cases[<sub>6</sub>]. Splenogonadal fusion is almost always left-sided and is much more common in males than females.

The most common presentation is as a scrotal mass<sup>[1, 3]</sup>. Other presentations include –as in this case- cryptorchidism, torsion, and inguinal hernia<sup>[6]</sup>. In about half of all reported cases splenogonadal fusion was found during childhood<sup>[2]</sup>.

The mechanism of splenogonadal fusion remains obscure. The splenic anlage develops in the left dorsal mesogastrium during the 4th to 5th week of gestation. Thereafter, as the embryonic gut rotates, the splenic anlage lies in close apposition with mesonephron and the gonad. The testis begins descent in the 8th to 10th week. Therefore, splenogonadal fusion must occur between the 4th and 10th weeks. Diagnosis typically is unsuspected preoperatively. Ultrasound, laparoscopic exploration and scintigraphic scanning to show the distribution of splenic tissue are necessary studies for proper diagnosis and management of these patients<sup>[1, 3]</sup>. If intraoperative biopsy reveals splenic tissue, orchiectomy is not indicated. Surgery is still necessary for the usual or unusual indications, such as hernia, cryptorchidism and torsion. The ectopic spleen can usually be dissected away and testis salvaged. Laparoscopic surgery should be considered for most uncomplicated cases.

### **CORRESPONDENCE TO**

Ibrahim Meteoglu Adnan Menderes University Faculty of Medicine Department of Pathology 09100 Aydin- TURKEY  
Phone: 90 256 2120020-227 Fax: : 90 256 2120146 e-mail: imete69@hotmail.com

### **References**

1. Oliva E., Young RH. Paratesticular tumor-like lesions, *Semin. Diagn. Pathol.* 2000;17:340-58.
2. Gouw AS, Elema JD, Bink-Boelkens MT, de Jongh HJ, ten Kate LP, The spectrum of splenogonadal fusion. Case report and review of 84 reported cases, *Eur J Pediatr* 1985; 144: 316-23.
3. Kmeoka H, Yamada R, Sonoda T, Okuyama A, Splenic gonadal fusion with persistent mullerian duct syndrome, *Urol Int* 1993; 50:170-3.
4. Murray RS, Keeling JW, Ellis PM, Fitzpatrick DR. Symmetrical upper limb peromelia and lower limb phocomelia associated with a de novo apparently balanced reciprocal translocation: 46,XX,t(2; 12)(p25.1;q24.1). *Clin Dysmorphol.* 2002;11:87-90.
5. Bonneau D, Roume J, Gonzalez M, Toutain A, Carles D, Marechaud M, Biran-Mucignat V, Amati P, Moraine C. Splenogonadal fusion limb defect syndrome: report of five new cases and review. *Am J Med Genet* 1999;86:347-58.
6. Lanza P, Scalfari A, Docimo C, Splenic-gonadal fusion in cryptorchidism, *Eur Urol* 1987;13:210-2.

**Author Information**

**Ibrahim Meteoglu**

Department of Pathology, Adnan Menderes University Faculty of Medicine

**Edi Levi**

Department of Pathology, Adnan Menderes University Faculty of Medicine

**Muhan Erku<sup>o</sup>**

Department of Pathology, Adnan Menderes University Faculty of Medicine

**Nil Çulhaci**

Department of Pathology, Adnan Menderes University Faculty of Medicine

**Mesut Yazici**

Department of Pediatrics Surgery, Adnan Menderes University Faculty of Medicine