

A Case Of Abdomino-Scrotal Hydrocele In An Adult Male

A Bhatnagar, T Prajapati, P Mohite

Citation

A Bhatnagar, T Prajapati, P Mohite. *A Case Of Abdomino-Scrotal Hydrocele In An Adult Male*. The Internet Journal of Surgery. 2006 Volume 9 Number 1.

Abstract

Abdomino-scrotal hydrocele is an extremely rare condition and very few cases are reported in the literature. All the reported cases are the ones in children. We are reporting a case of a huge abdomino-scrotal hydrocele in a 35 year old adult male. Condition needs extensive radio imaging for diagnosis. We did fluid analysis of cystic fluid and histopathological examination of the cyst wall to prove the diagnosis. Complete excision of the cyst wall with preservation of the testis is the treatment of choice.

INTRODUCTION

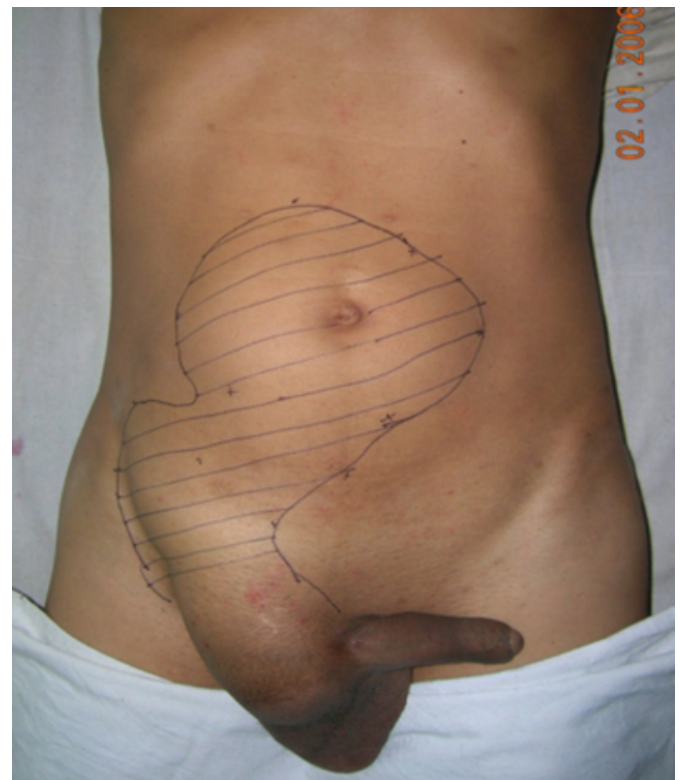
Extension of the hydrocele sac from the scrotum into the abdomen leads to formation of this condition. Cyst arises from the tunica vaginalis of the testis and cyst always contain normal testis inside it, which is pathognomonic of hydrocele. Rarity of the condition always bewilders the surgeons and most of the time despite thorough radiological investigations condition is diagnosed intraoperatively.

CASE REPORT

A 35-year male presented to us with the chief complains of slow growing lump in the abdomen since 4-5 years associated with pulling up of the right testis since last one year. He also had other associated complains of early feeling of satiety, fullness of stomach and non-localized dull aching chronic pain in the abdomen. Physical examination revealed a huge abdominal lump in the midline extending from pubis symphysis up to 7 cm above the umbilicus. Flanks were empty. Lump seems to deviate slightly rightwards of the pubic symphysis. Fluid thrill was present. Scrotal examination showed that the right testis is pulled up almost in the abdomen and just lower part was palpable in the scrotal sac.

Figure 1

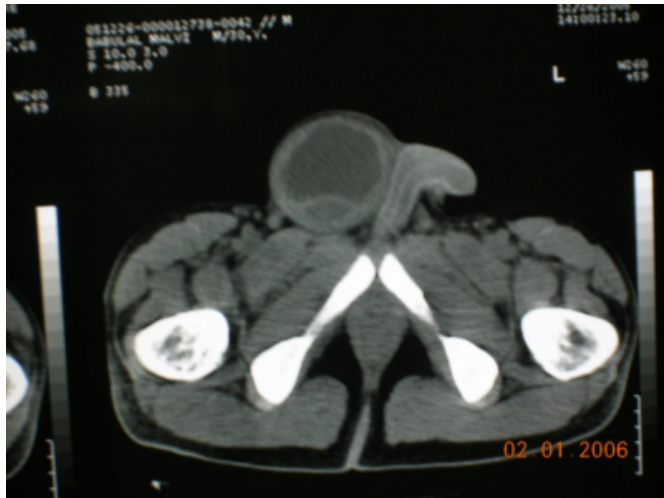Figure 1: On presentation



Ultrasonography of the abdomen revealed an intraabdominal cyst, which measured 30 cms vertically, and 15 cms each in breadth and depth. Cyst was unilocular filled with clear fluid. CT scan of the abdomen was done which confirmed findings of the ultrasonography with additional information about extension of the cyst into the right inguinal canal.

Figure 2

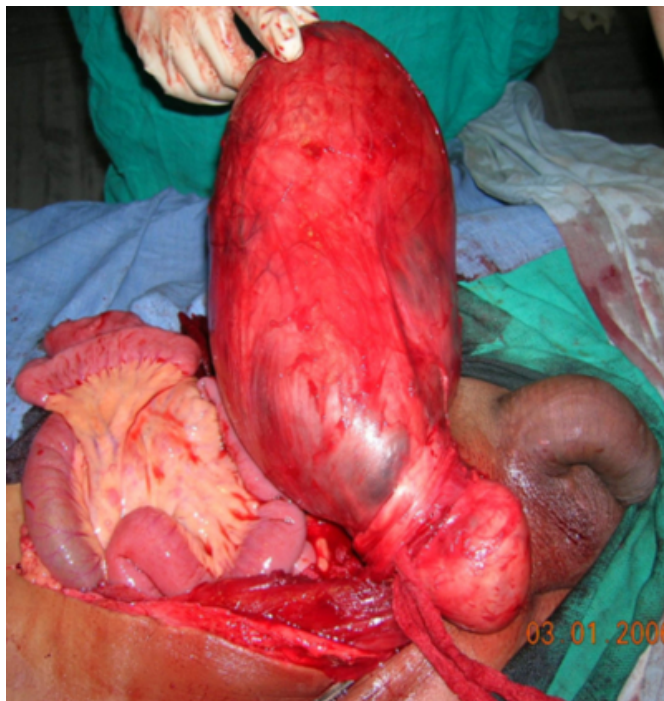Figure 2: CT Scan



Depending upon the investigations provisional diagnosis of lymphangioma/ mesenteric cyst was kept. Patient was operated with midline vertical incision over the abdomen. Peritoneum opened to found the huge cyst lying anterior to the abdominal organs. Cephalad part of the cyst was delivered out to found its extension into the right inguinal canal. Right testis was inside the cyst with inguinal ligament crossing over the cyst. Whole of the cyst wall except the part around the testis was resected. Testis was preserved and replaced inside the right scrotal sac.

Figure 3

Figure 3: Hydrocele with testis inside



Fluid analysis of the cystic fluid was done. Grossly fluid was amber color. Microscopically Cholesterol crystals were isolated. Tests were positive for albumin and fibrinogen. Specific gravity of the fluid was 1.02. Fluid analysis was coinciding with that of hydrocele fluid. Histopathological examination of the cyst wall suggested collagenous material without epithelial lining or lymphocytic infiltration ruling out possibility of lymphangiomatous cyst or cystic teratoma which are most common differential diagnoses.

DISCUSSION

Dupuytren in 1834 first mentioned about the condition abdominal scrotal hydrocele⁽¹⁾. Very few cases have been reported in the literature since then. Etiological factors proposed by some workers were not very sure. Mechanism proposed by Sasidharan⁽²⁾ is based on the hypothesis that the intraabdominal hydrocele is pushed into the scrotum due to increased intraabdominal pressure^(3,6). But it is unexplainable how intraabdominal hydrocele forms. Hydrocele arising from undescended testis may give rise to intraabdominal hydrocele, which may be pushed later on into the scrotal sac. Our patient had both testes fully descended into the scrotum 1 year before presentation. Right testis was pulled up after enlargement of the abdominal part of the cyst.

Sasidharan⁽²⁾ thinks the cause may be antenatal i.e. intrauterine pressure may push the hydrocele into the abdomen during the intrauterine life or in the process of birth. But the mechanism may be true in case of children but unexplainable in our patient who is 35 years. Again in our case the hydrocele is not pushed up from the scrotum but the testis is pulled up in the abdomen after primary development of the abdominal hydrocele. We think in this patient the hydrocele sac must be arising from the tunica vaginalis of the spermatic cord which initially grew into the abdomen and later on it pulled the testis into the abdomen.

Choice of investigation for the diagnosis of the condition is ultrasonography of the abdomen and scrotum. CT scan may help when the extension of the cyst can not be clearly defined as in our case^(3,4). Clinically the condition may present as an abdominoscrotal swelling or pure abdominal lump as in case of our patient. It may present due to pressure symptoms produced due to compression by the cyst over intra abdominal organs. In the literature cases were reported about hydronephrosis, hydroureter⁽⁷⁾ and unilateral leg oedema⁽⁸⁾ secondary to compression by the cyst. Torsion of the sac may produce acute abdominal symptoms.

Treatment of choice is to excise the hydrocele sac. Depending upon the size of the cyst incision used may be inguinal or in case of bigger size cyst or unclear diagnosis as in our case one can approach through midline vertical incision. If the walls of the inguinal canal are found damaged as in our case, repair of the inguinal canal with placement of testis in the scrotal sac carries prime importance in the management.

CONCLUSION

Abdominal hydrocele in adult is extremely rare condition. Hydrocele arising from the cord may be the etiology. Cystic abdominal swellings are the main differential diagnoses. Resection of the sac with repair of the inguinal canal is the treatment.

CORRESPONDENCE TO

Dr. Ashok Bhatnagar
51/A Maheshwari Nagar

Vasana link road, Gotri road,
Vadodara, 390001, India

References

1. Dupuytren G. Lecons orales de clinique chirurgicale. Paris Balliere 1834; 4:705.
2. Sasidhran P, Crankson S, Ahmed S. Fetal abdominoscrotal hydrocele. Am J Obstet Gynecol 1991; 5:1353-5.
3. Han BK. Uncommon causes of scrotal and inguinal swelling in children. J Clin Ultrasound 1986; 14:421-7.
4. Wlochynski T, Wassermann J, Generowicz Z. Abdominoscrotal hydrocele in childhood. J Pediatr Surg 1993; 28:248-50.
5. Saharia PC, Bronsther B, Abrams MW. Abdominoscrotal hydrocele. Case presentation and review of literature. J Pediatr Surg 1979; 6:713-4.
6. Klin B, Efrati Y, Mor A, et al. Unilateral hydroureteronephrosis caused by abdominoscrotal hydrocele. J Urol 1992; 148:348-6.
7. Klin B, Efrati Y, Mor A, et al. Unilateral hydroureteronephrosis caused by abdominoscrotal hydrocele. J Urol 1992; 148:348-6.
8. Krasna IH, Solomon M, Merzrich R. Unilateral leg edema caused by the abdominoscrotal hydrocele - elegant diagnosis with MRI. J Pediatr Surg 1992; 27:1349-51.

Author Information

Ashok Bhatnagar, M.S. (General Surgery)

Professor & Head, Department of Surgery, SSG Hospital & Medical College

Tushar Prajapati, M.B.B.S.

Resident (General Surgery), SSG Hospital & Medical College

Prashant Mohite, M.B.B.S.

Resident (General Surgery), SSG Hospital & Medical College