

Pancreatic Fistula Following Surgery of Primary Pancreatic Hydatid Cyst Causing Pancreatitis

G Nasir, R Ahmad

Citation

G Nasir, R Ahmad. *Pancreatic Fistula Following Surgery of Primary Pancreatic Hydatid Cyst Causing Pancreatitis*. The Internet Journal of Surgery. 2007 Volume 17 Number 1.

Abstract

Background:

Primary pancreatic hydatid cyst is rarely encountered and difficult to differentiate from pancreatic cyst neoplasm.

The Aim:

Of this case is to discuss the mode of presentation and best management of this condition.

Case Report:

A twenty-eight year-old male presented with recurrent upper abdominal pain of three years duration. The pain was radiating to the back and associated with vomiting and low-grade fever.

The ultrasound as well as CT scan with oral and I.V. contrast revealed that there was a solid-cystic mass in the tail of the pancreas suggesting of a pancreatic cystic tumor. Laparotomy revealed a pancreatic hydatid cyst, which was communicating with the pancreatic duct. The patient was treated by endocystectomy, which was complicated by pancreatic fistula.

Conclusion:

Pancreatic hydatid cyst should be kept in mind in any cystic lesion of the pancreas.

This disease could be treated by endocystectomy or partial pancreatectomy.

INTRODUCTION

Hydatid disease can affect any part of the body from crown to the big toe and no tissue is immune except hair, nail and teeth. However, the liver is affected in 75-80% of the cases (1, 2, 3).

This serious disease is caused by the larval stage of *Echinococcus granulosus*, which belongs to the *Taenia* family. It occurs throughout the world but is endemic in the Mediterranean, the Middle East, in South America, Australia, South Africa and Eastern Europe (2). Hydatid cysts of the pancreas are rarely encountered and few cases are reported (4).

We report a rare case of a primary pancreatic hydatid cyst, which was communicating with the main pancreatic duct causing recurrent acute and chronic pancreatitis.

CASE REPORT

A twenty-eight-years-old male presented with recurrent upper abdominal pain of three years duration. The pain was

radiating to the back and associated with vomiting and low-grade fever. These attacks subsided one or two days later. During the last six months the pain became more severe and associated with watery diarrhea and weight loss. On examination, there was nothing significant except mild tenderness at the epigastric region. The investigation revealed: PCV 47, WBC 10.5×10^9 /L, eosinophils 5%, neutrophils 75%, ESR 75mm/h, TSB 14mmol/L and alkaline phosphate 87IU/L. Abdominal ultrasound revealed a multiloculated cyst 11.2x6cm in the body and tail of the pancreas with another mass in the head of the pancreas measuring 3x5cm, which was suggestive of a pancreatic cyst neoplasm (cystadenoma, cystadenocarcinoma) or pancreatic pseudocyst. Abdominal CT scan with oral and I.V. contrast revealed that there was a solid-cystic mass, hypodense in nature, 8x6cm, with multiple septae at the body and tail of the pancreas, and another hypodense mass at the head of the pancreas measuring 5x4cm. The picture was suggestive of pancreatic cystadenoma or pancreatic pseudocyst (figure 1).

Figure 1

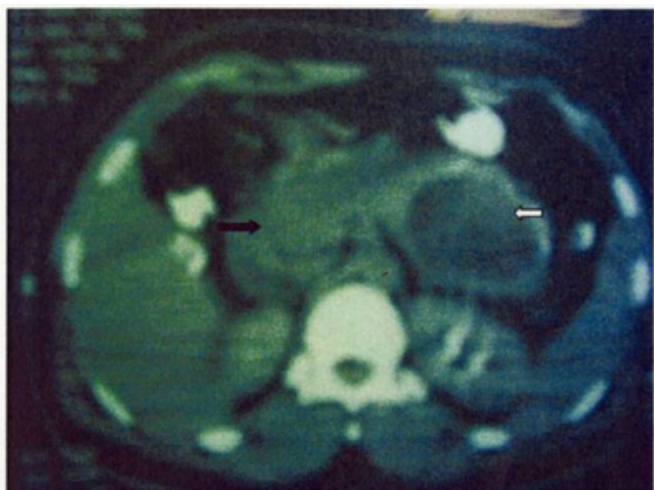


Figure 1 CT scan of the abdomen revealed cystic mass (white arrow) in the body and tail of the pancreas with other hypodense mass (black arrow) at the head of the pancreas.

The patient was explored through an upper midline incision, after mobilization of the spleen medially; there was a cystic mass at the body and tail of the pancreas measuring 10cm in diameter pointing mainly posteriorly. Aspiration revealed turbid greenish-white fluid and a laminated membrane was expelled suddenly (figure 2).

Figure 2

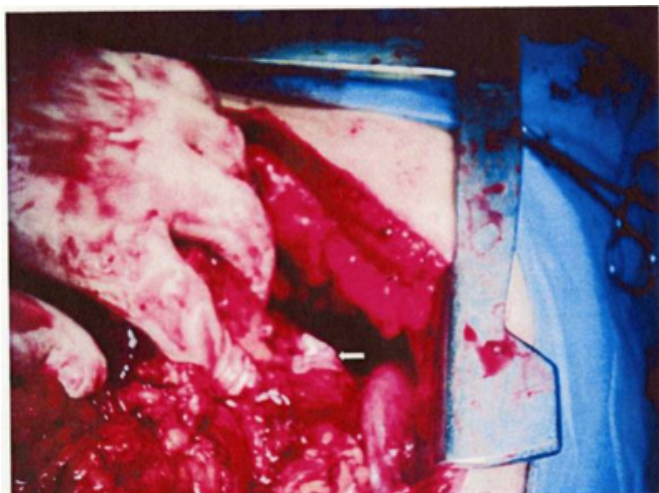


Figure 2 laminated membrane expelled from the cyst in the tail of the pancreas.

The cyst was completely evacuated and irrigated with normal saline and a tube drain was left inside the residual cavity. In addition to that, there was a diffuse enlargement of the head and neck of the pancreas but without definite mass. Incisional biopsy as well as fine-needle aspiration (FNA) was taken from the head of the pancreas. Post-operatively, the patient passed through uneventful recovery but on the

third post-operative day there was a discharge of a clear whitish fluid about 500cc/24h from the intracystic drain. The fluid analysis revealed that it is of exudative type with high amylase level (10350 IU/L), so the diagnosis of pancreatic fistula was proven. The patient was kept on fat-free diet and subcutaneous injection of octreotide 100ug/8hours. The patient was discharged home on the 8th postoperative day. Two weeks later there was no fluid discharge from the drain, which was removed.

The histopathological study of the pancreatic head biopsy revealed chronic non-specific inflammation and fibrosis (figure 3).

Figure 3

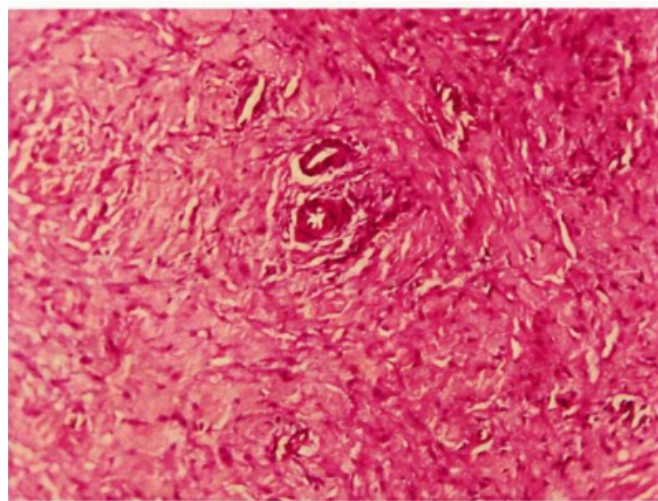


Figure 3 histopathology of the biopsy taken from the head of the pancreas showing features of chronic pancreatitis.

DISCUSSION

Primary pancreatic hydatid disease rarely occurs even in endemic areas. Al-Bahrani et al. reviewed 791 patients with abdominal hydatidosis and they found that only 0.4% of abdominal hydatid cysts were found in the pancreas⁽⁴⁾, while Nazif Erkan et al. report that primary pancreatic cysts account for 0.19-2% of all hydatid cases⁽⁵⁾. About 70-90% of pancreatitis is caused by either biliary tract disease or alcohol intake^(1,2,3,4,5,6,7,8). Recurrent acute pancreatitis due to hydatid cysts is extremely rare.

As far as we know, there were only four cases of pancreatic hydatid disease reported in the literatures but no case was found in English medical literature^(9, 12). The possible sources of infestation of the pancreas by hydatid cysts might be hematogenous dissemination, local spread via pancreatobiliary ducts or peri-pancreatic lymphatic invasion⁽¹¹⁾. The clinical presentation is usually due to the

pressure effect of the cyst on adjacent structures and depends largely on the size and anatomic location of the cyst.

It was found that 50% of pancreatic hydatid cysts are localized at the head^(14, 15), and the patients may present with jaundice⁽¹⁶⁾. But when the cyst is localized at the body and tail of the pancreas, it may present with recurrent abdominal pain or features of recurrent pancreatitis⁽⁹⁾.

Partial duct obstruction, along with stimulation of pancreatic secretion, produces a pancreatic inflammation. Duct obstruction of short duration may cause acute pancreatitis, but when it persists over months or years, it is a recognized cause of chronic pancreatitis^(8,9,10,11,12), as what happened in this case. Although the cystic lesion of the pancreas is easily identified by US or CT scan, the diagnosis of the hydatid cyst of the pancreas is rather difficult and rarely established pre-operatively unless the hydatid disease is suspected especially in endemic areas^(9, 11, 12). The hydatid cyst is easily confused with cystadenoma, cystadenocarcinoma or pseudocyst of the pancreas ⁽¹⁷⁾.

In the present case, abdominal ultrasound as well as CT scan of the pancreas (fig 1) failed to diagnose the hydatid cyst of the pancreas preoperatively, but both suggested a cystic neoplasm or pseudocyst of the pancreas.

The treatment of hydatid disease of the pancreas is either by partial pancreatectomy, or endocystectomy ^(15,16,17,18) according to the site and size of the cyst. If the cyst is communicating with the pancreatic duct, a stent is better to be inserted in the duct during surgery, otherwise cystogastrostomy might be the procedure of choice ^(4, 11). In this case the cyst was infected and it was treated by endocystectomy with drainage of the residual cavity. Postoperatively, a pancreatic fistula developed and closed spontaneously by conservative treatment after two weeks.

CONCLUSION

Hydatid cyst of the pancreas is an extremely rare condition but may be a causative factor for recurrent pancreatitis and should be kept in mind in any cystic lesion of pancreas.

This condition could be treated either by endocystectomy or partial pancreatectomy.

References

1. Alan G. Johnson. The liver. In: Charles V. Mann, R. C. G. Russell, Norman S. Williams (22nd ed.), *Bail & Love's Short Practice of Surgery*. Chapman & Hall Medical; 1995:

701-730.

2. Stephen A. Barnes, Keith D. Lillemoe. Liver Abscess and Hydatid Cyst Disease. In: Michael J. Zimmer, Seymour I. Schwartz, Harold Ellis, Maingot's Abdominal Operation, 10th ed., Appleton and Lange, Connecticut, 1997: p.1553.

3. Farroch Saidi. Treatment of Echinococcal Cyst. In: Lloyd M. Nyhus, Robert J. Baker, *Mastery of Surgery* (2nd ed.). Little, Brown and Company, Boston, 1992: 818-837.

4. Ahmed R. Al-Bahrani, Mohamed A. Al-Maiyah, Zuhair R. Al-Bahrani. Survey of abdominal hydatidosis. Review of 791 patients in Iraq. *The Arab J Gastroenterology* 2003;4:152-256.

5. Nazif Erkan, Mehmet Hacıyanli, Mehmet Yildirim, Cengiz Yilmaz. A case report of the unusual presence of hydatid disease in the pancreas and breast. *KOP. J Pancreas* (Online) 2004;5:368-372.

6. Clern W. Imire, C. Ross Carter, Colin J. McKay. Acute Pancreatitis. In: O. Kames Garden. *Hepatobiliary and Pancreatic Surgery* (2nd ed.), W.B. Saunders Company, Toronto 2001: p.305-347.

7. William E. Fisher, Dona K. Andersen, Richard H. Bell, Jr., Ashonk K. Saluja, F. Charlis Bruicardi. Pancreas. In: F. Charles Vruicardi, Dana K. Anderson, Timothy R. Biliar, David L. Dunn, John J. Haunter, and Raphael E. Pollock (eds), *Schwartz's Principles of Surgery* (8th ed.), McGraw Hill, Philadelphia 2004: 1221-1296.

8. Charles J. Yeo, John L. Cameron. The Pancreas. In: David C. Sabiston, H. Kim Lyerly (15th ed.), *Textbook of Surgery: The Biological Basis of Modern Surgical Practice*. W. B. Saunders Company; 1997: 1152-1186.

9. Ozmen MM, Moran M, Coskun F. Recurrent acute pancreatitis due to hydatid cyst of pancreatic head, case report and review of the literature. *Journal of Pancreas* 2005;6:354-358.

10. Sebbag H, Partensky C, Roche J, Ponchon T, Martins A. Recurrent acute pancreatitis from the rupture of a solitary pancreatic hydatid cyst in the Wirsung's canal. *Gastroenterol Clin Biol* 1999;23:793-4.

11. Augustin N, Gamstatter G, Neher M, Schreyer T, Storkel S. *Echinococcus cysticus* of the pancreas in the clinical picture of the acute pancreatitis. *Chirurg* 1984;55:661-4.

12. Katkhouda N, Legoff D, Tricarico A, Castillo L, Bertrand M, Mouiel J. hydatid cyst of the pancreas responsible for chronic recurrent pancreatitis. *Presse Med* 1988;17:2021-3.

13. Brown RA, Millar AJ, Steiner Z, Krige JE, Burkimsher D, Cywes S. Hydatid cyst of the pancreas a case report in child. *Eur J Pediatric Surgery* 1995;5:121-4.

14. Coskun T, Kama NA, Dener C, Gozalan U. Primary hydatid disease of the pancreas. *Am J Gastroenterol* 1997;92:899-900.

15. Kayabali I, Hatuk GI, Necati O. Surgical treatment of hydatid cysts of the pancreas. *Int Surgery* 1991;76:185-8.

16. Hamaci Eo, Besim H, Korkmaz A. Unusual locations of the hydatid disease and surgical approach. *ANZ J Surgery* 2004;74:356-60.

17. Krige JE, Mirza K, Bornman PC, Beningfield SJ. Primary hydatid cysts of the pancreas. *S African J Surgery* 2005;43:37-40.

18. Safioleas MC, Moulakakis KG, Manti C, Kostakis A. Clinical consideration of primary hydatid disease of the pancreas. *Pancreatology* 2005;5:457-61.

19. Oruc MT, Kulacoglu IH, Hatipoglu S, Kulah B, Ozmen MM, Coskun F. Primary hydatid cyst of the pancreas related to main pancreatic duct. *Hepatogastroenterology* 2002;49:383-4.

Author Information

Ghassan A.A. Nasir, FRCS, FICS

Senior Consultant Surgeon, Faculty of Medicine-UiTM

Raafat Ahmad, CABS

Consultant Surgeon