

Idiopathic eosinophilic cholecystitis with cholelithiasis: A Case Report And Review Of Literature

D Singh, R Shankar, R Gondal, V Malhotra, P Mishra

Citation

D Singh, R Shankar, R Gondal, V Malhotra, P Mishra. *Idiopathic eosinophilic cholecystitis with cholelithiasis: A Case Report And Review Of Literature*. The Internet Journal of Surgery. 2007 Volume 16 Number 1.

Abstract

Eosinophilic cholecystitis is a rare form of cholecystitis in which eosinophils form the dominant component of inflammatory cells in the gallbladder wall. It is an acalculous cholecystitis but in rare cases it presents with cholelithiasis. It is frequently associated with severe diseases like eosinophilia-myalgia syndrome, hypereosinophilic syndrome, parasitic infestations or with drug intake. A 41-year-old man presented to us with complaints of abdominal pain and tenderness and guarding in the right upper quadrant. Ultrasonography of the abdomen showed a distended gallbladder with multiple calculi. During open cholecystectomy, a partially intrahepatic gallbladder with serosal congestion was found. Microscopic examination of the gallbladder showed eosinophils forming more than 90% of the inflammatory infiltrate. Eosinophils were present in all layers of the gallbladder. A histopathologic diagnosis of idiopathic eosinophilic cholecystitis with cholelithiasis was made. We present this case because of the rare occurrence of eosinophilic cholecystitis, the rarity of association of idiopathic eosinophilic cholecystitis with cholelithiasis and the need to investigate the patient meticulously for other associated disease conditions, which might have a worse prognosis than cholecystitis itself.

INTRODUCTION

Eosinophilic cholecystitis is a rare form of cholecystitis in which eosinophils form the predominant component of the inflammatory cell infiltrate in the wall of the gallbladder. (1) It is described as an acalculous cholecystitis but in rare cases it is associated with cholelithiasis. (2) Eosinophilic cholecystitis may be idiopathic or it may be associated with other disease conditions. (3)

We report a case of idiopathic eosinophilic cholecystitis with cholelithiasis because of its rarity and the need to investigate the patient for other associated disease conditions, which may range from simple gastritis to parasitic infestation, to a serious condition like hypereosinophilic syndrome or a debilitating disease like eosinophilia-myalgia syndrome.

CASE REPORT

A 41-year-old male patient presented to us with complaints of right upper quadrant pain off and on since two months. Pain was dull and radiated to the back. There was no history of drug intake and no significant past or family history. On examination, the patient was afebrile. Icterus, cyanosis and pallor were not present. Tenderness and guarding were present below the right costal margin. Murphy's sign was positive.

Laboratory investigations showed: Hb 10.2g%; TLC 9.8 109/L; DLC: neutrophils 68%, lymphocytes 30%, monocytes 1% and eosinophils 1%; platelet count 153 109/L; serum bilirubin (total/direct) 0.4/0.2mg%; alkaline phosphatase 63IU/mL; SGOT 33IU/mL; SGPT 42IU/mL; total proteins 7.6g% and albumin 4.2g%. The stool test for ova or cysts was negative.

Ultrasound examination of the abdomen revealed a distended gallbladder with multiple calculi. Liver, common bile duct and the rest of the abdominal viscera were unremarkable. A clinical diagnosis of chronic cholecystitis with cholelithiasis was made. An open cholecystectomy was performed. Peroperatively, a partially intrahepatic gallbladder with serosal congestion was found. The postoperative course of the patient was unremarkable.

The operative specimen received was a gallbladder measuring 11x3x2cm. The external surface was congested. On cutting open, the gallbladder was filled with bile and multiple calculi. The mucosa was congested and ulcerated. Wall thickness was 0.3-0.4cm. Multiple strips from the body and neck of the gallbladder were taken, routinely processed and paraffin embedded. Sections were stained with haematoxylin and eosin.

Microscopic examination showed focal ulceration of the gallbladder mucosa. Eosinophils formed the dominant component of the inflammatory infiltrate (90%). They were present in all the layers of the gallbladder. (Figure 1, 2) Few lymphocytes and occasional neutrophils were also seen. A histopathologic diagnosis of idiopathic eosinophilic cholecystitis with cholelithiasis was made.

The patient is well and is under follow-up at our GI surgery department.

Figure 1

Figure 1: Section from the gallbladder showing eosinophils infiltrating all the layers of the gallbladder wall

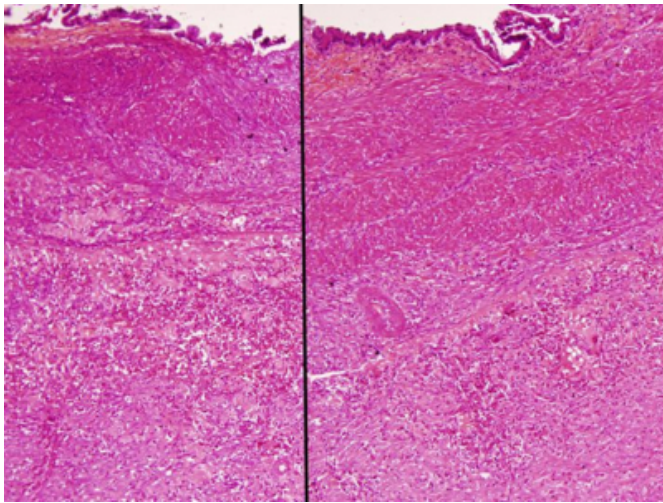
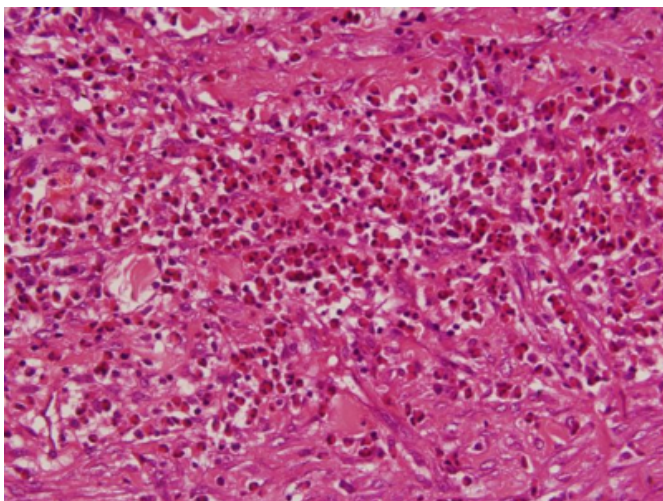


Figure 2

Figure 2: Eosinophils formed the predominant component of the inflammatory infiltrate



DISCUSSION

Eosinophilic cholecystitis was described for the first time by Albot et al. in France in 1949. (4) It is a rare entity,

characterized by a dense transmural inflammatory cell infiltrate in which eosinophils comprise more than 90% of inflammatory cells. (3)

The etiology of eosinophilic cholecystitis is not known. Pardo Mindas et al. described eosinophilic infiltrates of isolated organs and tissues not associated with any history of allergy in the patients. Symptoms and signs in these cases were related to the inflammation of the involved organ or tissues. It was proposed that some of these lesions are possibly due to local allergic reaction to substances released at the foci of inflammation in the target organ or tissues. Platelet-activating factor, leukotrienes and many cytokines were proposed to be the substances responsible for the inflammation. (5) It has also been proposed that eosinophilic cholecystitis may result from a hypersensitivity type of inflammatory response to altered bile. (1)

Eosinophilic cholecystitis occurs in association with eosinophilic gastroenteritis, eosinophilia-myalgia syndrome, idiopathic hypereosinophilic syndrome, parasitic infestation like *clonorchis sinensis* and hydatid cyst disease and drugs like cephalosporins. (3) Rare cases of idiopathic eosinophilic cholecystitis have been reported in which no associated etiology could be found. (1,3) In our patient, we could not find any possible etiology even after a detailed personal, past and family history along with a thorough physical examination and laboratory investigations.

An increased number of eosinophils in the inflammatory infiltrate in the gall bladder occurs three times more commonly in patients with acalculous cholecystitis than in patients with cholecystitis with cholelithiasis. (1) In our patient, gallstones were present in a rare association with eosinophilic cholecystitis.

Eosinophilic cholecystitis cannot be clinically distinguished from ordinary cholecystitis before surgery and it invariably leads to cholecystectomy. (6) A suspicion of this entity can be kept if peripheral eosinophilia is present. (7) The significance of eosinophilic cholecystitis lies in the fact that it may be associated with other more severe disease conditions and eosinophilic cholecystitis may be a presenting feature of these conditions. These may be missed if the patient is not subjected to a thorough clinical and laboratory investigation. The symptoms and signs of associated disease may be present along with symptoms of cholecystitis. However, if a patient presents only with symptoms of cholecystitis and a post-operative histopathologic diagnosis of eosinophilic cholecystitis is

made, the patient must be investigated to rule out other associated disease conditions, which may have a worse prognosis than cholecystitis itself.

CORRESPONDENCE TO

Dr. Deepak Kumar Singh 597, Z-Type Flats, Lucknow Road, Timarpur, Delhi-110054. Ph.: +91-9819713135 E-mail: dr_kumar2004@yahoo.com

References

1. Dabbs DJ. Eosinophilic and lymphoeosinophilic cholecystitis. *Am J Surg Pathol*. 1993;17:497-501.
2. Pary SW, Pelias ME, Browder W. Acalculous hypersensitivity cholecystitis: hypothesis of a new clinicopathologic entity. *Surgery*. 1998;104:911-916.
3. Sanchez-Pobrep P, Lopez-Rios Moreno, Colina F, Yela C, Manzano M, Rodriguez S, Martin A, Casis B, Garfia C, Castellano G, Solis-Herruzo JA. Eosinophilic cholecystitis: an infrequent cause of cholecystectomy. *Gastroenterol Hepatol*. 1997;20:21-22.
4. Albot G, Poilleux H, Oliver C. Les Cholécystites a éosinophils. *Presse Med* 1949;57:558-559.
5. Pardo-Mindan FJ, Joly MA, Santamaria M, Munoz Navas M. Eosinophil inflammatory reaction in isolated organs. *Allergol Immunopathol (Madr.)*. 1980;8:23-30.
6. Tajima Katsushi, Katagiri T. Deposits of eosinophil granule proteins in eosinophilic cholecystitis and eosinophilic colitis associated with hypereosinophilic syndrome. *Dig Dis Sci*. 1996;41:282-288.
7. Vauthey JN, Loyer E, Chokshi P, Lahoti S. Case 57: Eosinophilic colangiopathy. *Radiology*. 2003;227:107-111.

Author Information

Deepak Kumar Singh, M.D.

Senior Resident, Department of Pathology, GB Pant Hospital

Ravi Shankar, MBBS

Junior Resident, Department of Pathology, GB Pant Hospital

Ranjana Gondal, MD

Junior Resident, Department of Pathology, GB Pant Hospital

V. Malhotra, MD

Director-Professor and HOD, Department of Pathology, GB Pant Hospital

P.K. Mishra, MS

Professor, Department of Gastrointestinal Surgery, GB Pant Hospital