

# Anesthetic management of repair of exomphalus and extrophy of the bladder for a neonate with double outlet right ventricle with atrial septal defect

G Mishra, V Hemanth, S Mishra, P Ezhilarasu

## Citation

G Mishra, V Hemanth, S Mishra, P Ezhilarasu. *Anesthetic management of repair of exomphalus and extrophy of the bladder for a neonate with double outlet right ventricle with atrial septal defect*. The Internet Journal of Anesthesiology. 2008 Volume 22 Number 1.

## Abstract

A neonate with complex cardiac disease posted for emergency non cardiac surgery is a challenging task for anesthesiologists. There have complex pathophysiology, which can leads to unstable haemodynamics, arrhythmia and cardiac arrest during anesthesia. Here we report a case of a neonate with double outlet right ventricle with large atrial septal defect posted in emergency as suspected gangrenous bowel due to exomphalus which was also associated with exstrophy of bladder.

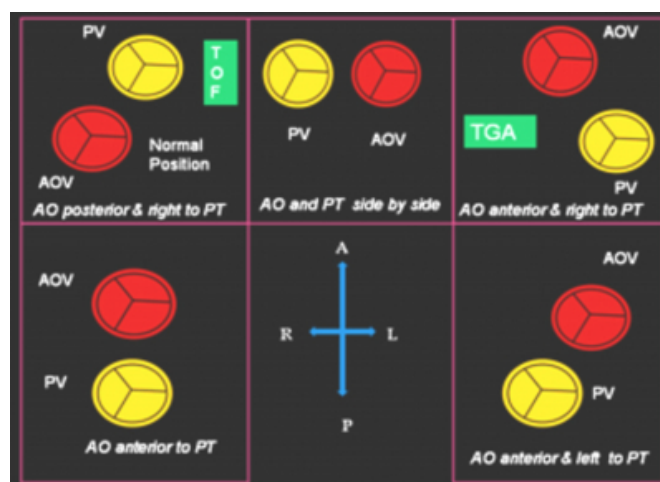
## INTRODUCTION

A neonate with complex cardiac disease posted for emergency non cardiac surgery is a challenging task for anesthesiologists. They have a complex pathophysiology, which can lead to unstable haemodynamics, arrhythmia and cardiac arrest during anesthesia. Double outlet right ventricle (DORV) is a partial abnormality of ventriculoarterial connection and intracardiac ventricular septation. It is a congenital anomaly in which both great arteries arise wholly or in large part from the right ventricle. The great vessel relationships also lie in between that of the tetralogy of Fallot and of D-transposition, resulting in both aorto-mitral and aorto-tricuspid discontinuity. The VSD is typically large and has commonly 4 potential locations:

- Subaortic,
- Subpulmonic, (Taussig-Bing anomaly)
- Doubly committed,
- Remote.

**Figure 1**

Figure 1 (Relationship of the semilunar cusps in heart with DORV)



Here we report a case of a neonate with double outlet right ventricle with large atrial septal defect posted for emergency repair of exomphalus and extrophy of bladder.

A two day old female baby born outside hospital diagnosed as exomphalus with extrophy of bladder was sifted to our institute for further management. Because of possibility of associated congenital anomaly, chest x-ray and echocardiography was done.

This revealed DORV with minimal sub pulmonary stenosis, large VSD, aorta right to pulmonary artery, ASD of 6mm,

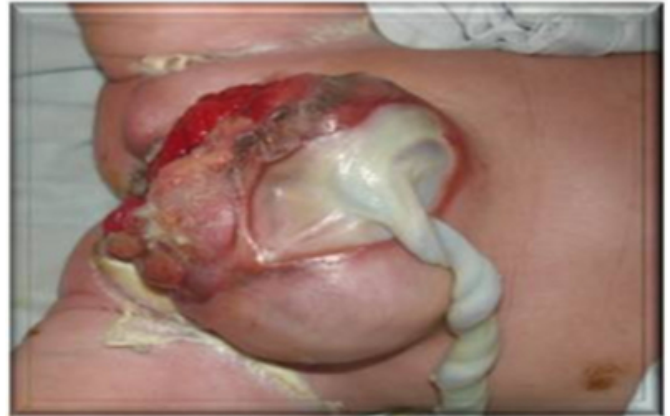hypoplastic mitral valve. Large sub-aortic VSD, mild subpulmonary obstruction, Peak gradient across pulmonary valve is 18mm. Both ventricles have normal systolic performance. Laboratory investigation revealed as, blood urea-16 Cr-1.0 Na-130 mEq/dl K-6.0 mEq/dl Cl-101 mEq/dl Bicarb-18 mEq/dl, Ionized calcium-1.18 mmol/dl PT-16 (C-14) SGOT-87 IU/L, SGPT-16/L. ABG-PH-7.32. PaCO<sub>2</sub>-76 mmHg in room air, PaO<sub>2</sub>-30 mmHg..

Two 22G IV cannulas were secured and iv fluids started. Monitor connected were HR, Spo<sub>2</sub>, ECG, Temp and urine output. HR-120/Min, NIBP-70/40 mmHg. Spo<sub>2</sub>-93 % (room air), 100% O<sub>2</sub> by mask, ECG shows sinus rhythm. The child received prophylactic antibiotics. Fentanyl-3 µg and midazolam-0.2 mg. Saturation maintained-100% with FIO<sub>2</sub>-100%. Caudal anesthesia was planned with bupivacaine-0.125%-10 ml. Vitals were stable. Inj adrenaline and Phenylephrine, and defibrillator kept ready

The patient was induced with sevoflurane with gradual concentration up to 7% and intubated with size 3 ETT/9. Post intubation Spo<sub>2</sub> drops to 90% HR-88/MIN. Anesthesia was maintained with Inj atracurium and sevoflurane 2-3% and fentanyl. Operation time was 3 hours. In spite of warming measure the temperature decreased to 33.4°C. Repair of abdominal wall defect and reconstruction of extrophy was performed. Repair bony pelvis (symphysis pubis fusion) followed. Intra-operative vitals were stable. Spo<sub>2</sub> maintained between-93-100% with 50% O<sub>2</sub> and N<sub>2</sub>O. HR-100-130/min. Blood loss:-60ml replaced with blood. (more during pubic symphysis fusion) Total IV fluid:-75ml RL. TEMP-33.4°C -34°C Urine output -10ml, ON Ventilator for 3 hours. Temp improved to 36°C. The patient was extubated. Post extubation vitals were of HR-130-140/min, BP-65-75/40-45 mmHg, Spo<sub>2</sub>-95-98% with 40% FIO<sub>2</sub> in room air.

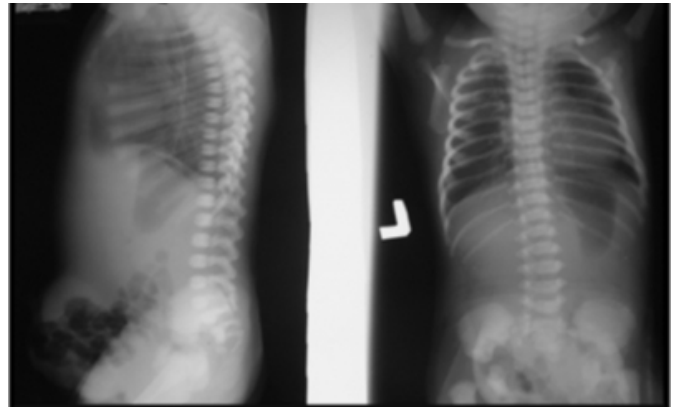
**Figure 2**

Figure 2 Exomphalus and extrophy of bladder



**Figure 3**

Figure 3 x-ray showing exomphalus and extrophy of bladder



## DISCUSSION

A proper anaesthetic goal for congenital heart disease with multiple heart defects is difficult, as in this case. Pathophysiology of DORV can be either like TOF or TGA. In this case echocardiography finding was more suggestive of TOF. A different technique has been described for anaesthesia for non cardiac surgery with DORV 2, 3, 4. Ketamine is the usual induction of choice for TOF, along with muscle relaxant for intubation, but we preferred Sevoflurane for induction, as the airway may be difficult because of receding mandible. Sevoflurane can cause decrease in systemic vascular resistance which can be managed with small dose of Phenylephrine. Exomphalus, Extrophy bladder is also associated with multiple other conditions and should be taken into anaesthetic consideration. These are,

Congenital heart disease  
Spin bifida, Meningocele

Prematurity  
Malrotation, Diaphragmatic hernia  
Backwith-wiedmann syndrome(Exomphalus, Macroglossia, Micrognathia, Hypoglycemia with kidney/ Liver involvement)  
Intraoperative concerns of latex sensitization and latex allergy

## **SUMMARY**

A neonate with complex congenital heart disease can be very sensitive to changes in preload, after load, ionotropes and arrhythmias. This case report is important as it is difficult to delineate and correlate anatomic variable type of DORV, its pathophysiology and anaesthetic implication. From Echo finding diagnosis was more towards patho-physiology like

that of TOF. Anesthesia goals were planned like TOF, and it worked well.

## **References**

1. Freedom R, Smallhorn J. Double outlet right ventricle. In: Freedom R, Benson L, Smallhorn J - Neonatal Heart Disease. 1st ed. London: Springer Verlag, 1992: 453-70.
2. Kamata K, Nagata O, Komatsu R, Ozaki M. Epidural anesthesia for cesarean delivery in a parturient with a double-outlet right ventricle J Anesth. 2006; 20(2):158.
3. Tjeuw M, Fong J. Anaesthetic management of a patient with a single ventricle and phaeochromocytoma. Anaesth Intensive Care 1990;18:567-9.
4. The Perioperative Management of a Patient with Complex Single Ventricle Physiology and Pheochromocytoma.
5. Landau R, Giraud R, Morales M, Kern C, Trindade P. Sequential combined spinal-epidural anesthesia for cesarean section in a woman with a double-outlet right ventricle. Acta Anaesthesiol Scand. 2004 Aug; 48(7):922-6.

**Author Information**

**Gayatri Mishra, MBBS, DNB trainee**

Junior resident, Department of Anaesthesiology, IGGGH-PGI Pondicherry India

**V. Hemanth, MBBS, DA, DNB**

Ex. Specialist, Department of Anaesthesiology, IGGGH-PGI Pondicherry India

**Sandeep Kumar Mishra, MBBS, DA**

Senior Resident, Department of Anaesthesiology, IGGGH-PGI Pondicherry India

**P. Ezhilarasu, MBBS, DA, MD**

HOD, Department of Anaesthesiology, IGGGH-PGI Pondicherry India