

Ancient Schwannoma Of The Nasal Cavity, A Rare Cause Of Nasal Obstruction: A Review And Case Report

N Jonas, D Matelakengisa, J Fagan

Citation

N Jonas, D Matelakengisa, J Fagan. *Ancient Schwannoma Of The Nasal Cavity, A Rare Cause Of Nasal Obstruction: A Review And Case Report*. The Internet Journal of Otorhinolaryngology. 2006 Volume 6 Number 1.

Abstract

Schwannomas with destructive pathologic characteristics, also known as ancient schwannomas are slow growing benign tumours arising from the nerve sheath. Approximately one third of schwannomas occur in the head and neck region. Surgery is the treatment of choice and total excision is curative. Although schwannomas have been described in the head and neck region, we would like to report, to the best of our knowledge, the first case of an ancient schwannoma of the nasal cavity.

INTRODUCTION

Schwannomas are benign, encapsulated tumours arising from the Schwann cells of the nerve sheath, and were originally described by Stout in 1935 [1]. Batsakis more accurately described these tumours as neurilemmomas, in reference to the cells of origin [2]. Approximately 25-40% of all neurilemmomas occur in the head and neck region [3]. The acoustic nerve is the most frequent site involved. Other locations described in the literature include the scalp, oral cavity, pharynx, larynx, parotid gland, middle ear and sinonasal tract. [4, 5]

Sinonasal tract schwannomas are very rare, representing less than 4% of head and neck schwannomas. [6] Patients, with sinonasal schwannomas, ages range from 12 to 76 years, with most cases occurring between ages 25 and 55 years. Males and females are affected equally. [7]

Symptoms and signs associated with sinonasal schwannomas include rhinorrhea, epistaxis, anosmia, and facial swelling. [8] Because these tumours are located in a cavity, they are able to grow silently to a substantial size before diagnosis. The most common affected area is the ethmoid sinus, followed by the maxillary sinus, nasal pits, and sphenoid sinus. [8] Localization to the nasal septum is exceedingly rare. [9]

This paper reports an unusual case of an Ancient Schwannoma that presented as long standing nasal obstruction.

CASE PRESENTATION

A 54 year old gentleman presented to our outpatients department complaining of a blocked nose for the past three years. He stated that his left nostril was more blocked than the right and that it was progressively getting worse. He did not have any nasal discharge, discomfort or epistaxis. He also did not have any other systemic complaints.

On examination he was a healthy looking gentleman and examination of his throat, ears and neck did not reveal any abnormalities. On examination of his nose an obvious mass in the left nostril could be seen, displacing the septum to the right side. The mass appeared pale and granular.

A contrasted CT scan of his nose and sinuses were done. The scan revealed a large soft tissue mass lesion that completely filled the left nasal cavity. It showed irregular, mild enhancement post contrast. The mass had completely obliterated the nasal turbinates and osteo-meatal opening on the left side and extended posteriorly as far as the posterior choanae on the left. The nasopharynx was normal. The nasal septum was markedly deviated to the right side. The appearance was suggestive of a slow growing mass (Figure 1,2) . The differential diagnosis included benign nasal polyp, inverting papilloma and schwannoma.

Figure 1

Figure 1

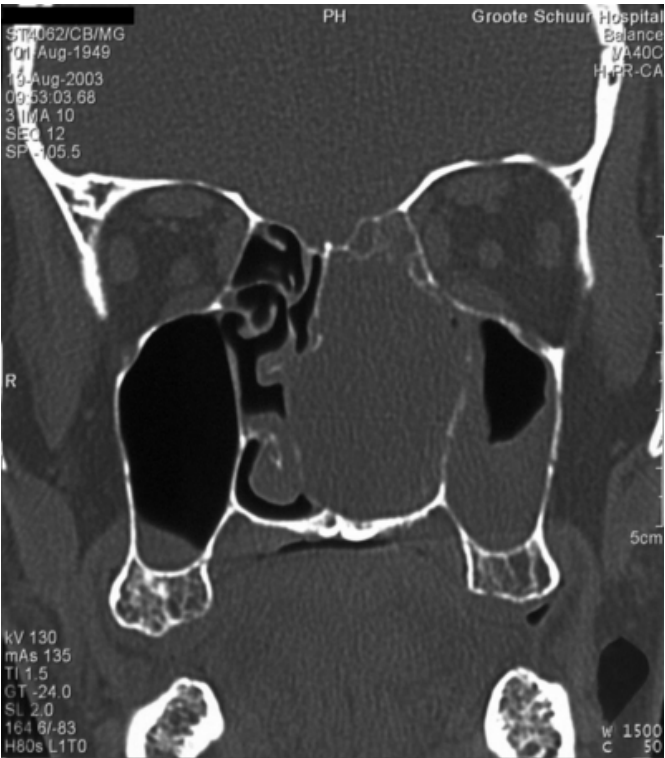
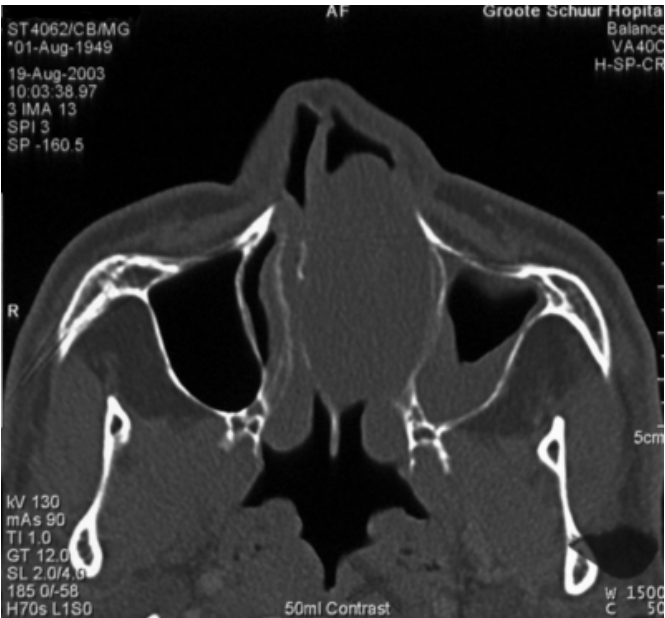
Figure 2

Figure 2



Subsequently a biopsy was performed. The biopsy was composed of slender spindled cells in a loose, fibrous background with focal areas of hypercellularity alternating with hypocellular areas (Figure 3). There were focal areas of pleomorphism of the cells and chronic inflammation. There

was no mitotic activity (Figure 4). The S100 immunohistochemistry was strongly positive.

Figure 3

Figure 3

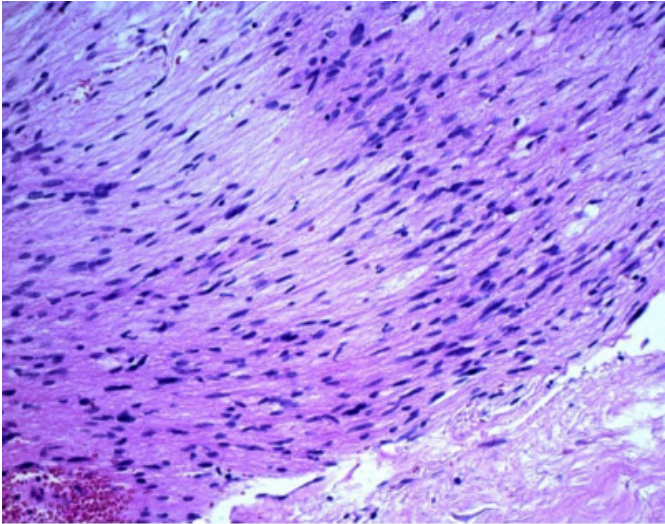
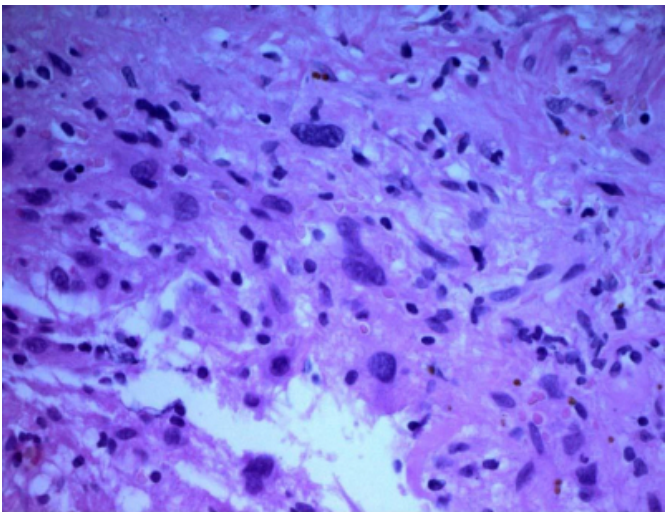


Figure 4

Figure 4



A diagnosis of ancient schwannoma was made and the tumour was excised under general anaesthesia. Early follow up showed no signs of local recurrence of the tumour.

DISCUSSION

The term ancient schwannoma was first introduced by Ackerman and Taylor in 1951 [10]. They described destructive pathologic characteristics such as large areas of hyalinized matrix, increased hypercellularity with nuclear pleomorphism, and hyperchromatism. Ackerman and Taylor stated that these features occurred in schwannomas of long

duration, leading to the term ancient schwannoma.

The presence of hypercellularity and atypia may lead to the misdiagnosis of these lesions as sarcomas. Dahl reported 6 cases out of 11 that have been misdiagnosed as sarcomas [11]. Various other sinonasal tumours have been described in the literature and can be difficult to distinguish from schwannomas. These tumours include malignant melanomas, leiomyomas, leiomyosarcomas, hemangiopericytomas etc. The absence of mitotic activity is the key feature to differentiate benign ancient schwannomas from malignant schwannomas. The presence of a capsule, evidence of prior haemorrhage, thick walled vascular structures and areas representing degenerative changes also may suggest a benign lesion.

Malignant changes in a benign schwannoma are extremely rare. The diagnosis of malignant change of a benign schwannoma is based on the following criteria: (1) demonstrable areas of benign schwannoma; (2) unequivocal malignant foci manifested by increased cellularity, numerous mitoses, anaplastic cells, and invasiveness; (3) transitional areas between malignant and benign regions; and (4) the absence of clinical evidence of neurofibromatosis 1 [12,13].

The first ancient schwannoma of head and neck region was reported by Eversole and Howell in 1971 [14]. Since the first report, several authors have described ancient schwannomas in a variety of locations in the head and neck region, involving the oral cavity, submandibular gland, pharynx, orbit and infratemporal fossa.

Schwannomas in general should be treated by surgical excision, attempting to preserve the function and integrity of the involved nerve. Successful grafting of defective nerve segments has been described by some authors, in cases where preservation of the nerve was not possible [15]. In this case the tumour most likely originated from branches of the trigeminal nerve supplying sensation to the sinonasal mucosa. The small size of these nerves will explain why it is rarely observed during surgical resection. [4, 16] Total excision of the lesion is curative.

Ancient schwannoma is a rare variant of a neurilemmoma, which clinical findings and radiographic features suggest is a slow-growing, benign tumour. To the best of our knowledge, this is the first reported case of an ancient schwannoma of

the nasal cavity.

ADDRESS OF CORRESPONDENCE

Dr Nico Jonas Division of Otolaryngology University of Cape Town Medical School H53, Old Main Building, Groote Schuur Hospital Observatory, Cape Town, 7925 South Africa Tel: +27 (021) 4066420 Fax: +27 (021) 4488865 E-mail: nicojonas@gmail.com

References

1. Stout AP. The peripheral manifestations of the specific nerve sheath tumour (neurilemmoma). *Am J Cancer* 24:751-796, 1935
2. Batsakis JG. Tumours of the Head and Neck, Clinical and Pathological Consideration. Baltimore, MD, Williams & Wilkins, 1974, pp 231-249
3. Conley JJ. Neurogenic tumours in the neck. *Arch Otolaryngology* 61: 167-180, 1955
4. Donnelly MJ, Al-Sader MH, Blayney AW. Benign nasal schwannoma. *J Laryngol Otol* 1992; 106:1011-1015.
5. Niemczyk K, Vaneecloo FM, Houcke-Lecomte M. et al. Correlation between Ki-67 index and some clinical aspects of acoustic neuromas (vestibular schwannomas). *Otolaryngol Head Neck Surg* 2000; 123:779-783.
6. Hillstrom RP, Zarbo RJ, Jacobs JR. Nerve sheath tumors of the paranasal sinuses: electron microscopy and histopathologic diagnosis. *Otolaryngol Head Neck Surg* 1990; 102:257-263.
7. Buob D, Wacrenier A, Chevalier D. Schwannoma of the Sinonasal Tract: A Clinicopathologic and Immunohistochemical Study of 5 Cases *Archives of Pathology and Laboratory Medicine: Vol. 127, No. 9, pp. 1196-1199.*
8. Donnelly MJ, Al-Sader MH, Blayney AW. Benign nasal schwannoma. *J Laryngol Otol* 1992; 106:1011-1015.
9. Berlucchi M, Piazza C, Blanzuoli L, Battaglia G, Nicolai P. Schwannoma of the nasal septum: a case report with review of the literature. *Eur Arch Otorhinolaryngol* 2000; 257:402-405.
10. Ackerman LV, Taylor FH. Neurogenous tumours within the thorax: A clinicopathological evaluation of forty-eight cases. *Cancer* 4:669-691, 1951
11. Jackson RM, Rice DH, Crockett DM. Malignant schwannoma of the cervical vagus nerve in a patient with neurofibromatosis (von Recklinghausen's disease). *Otolaryngol Head Neck Surg* 94:641-644, 1986
12. Nakayama H, Shimanoto F, Kajihara H. Ancient schwannoma of the oral floor and ventricular portion of the tongue: a case report and review of the literature. *Jpn J Clin Oncol* 1996; 26:185-188
13. Khwarg SI, Lucarelli MJ, Lemke BN, et al. Ancient schwannoma of the orbit. *Arch Ophthalmol* 1999; 117:262-264
14. Eversole LR, Howell RM. Ancient neurilemmoma of the oral cavity. *Oral Surg* 32:440-443, 1971
15. Rosenfeld L, Graves H Jr, Lawrence R. Primary neurogenic tumours of the lateral neck. *Ann Surg* 167:847-855, 1968
16. Robitaille Y, Seemayer TA, El Deiry A. Peripheral nerve tumors involving paranasal sinuses: a case report and review of the literature. *Cancer* 1975; 35: 1254-1258.

Author Information

Nico E. Jonas, MBCHB, FRCS (Glas), FCORL (SA)

Senior Registrar, Division of Otolaryngology, University of Cape Town

D. B. Matelakengisa, MBCHB

Registrar, Division of Anatomical Pathology, University of Cape Town

Johannes J. Fagan, MBCHB, MMed, FCS (SA)

Division of Otolaryngology, University of Cape Town