

Bladder Outflow Obstruction: An Unusual Presentation Of Mucocele Of The Appendix

M Akhtar, S Basu, H Montgomery, S Namasivayam, K Rogawski

Citation

M Akhtar, S Basu, H Montgomery, S Namasivayam, K Rogawski. *Bladder Outflow Obstruction: An Unusual Presentation Of Mucocele Of The Appendix*. The Internet Journal of Urology. 2006 Volume 4 Number 2.

Abstract

Bladder outflow obstruction in elderly males usually results from an intrinsic narrowing at the level of bladder neck, prostate or the urethra. We report a case where obstruction to the bladder outflow resulted from an extrinsic compression by an appendicular mucocele, an unusual mode of presentation of this pathological entity.

INTRODUCTION

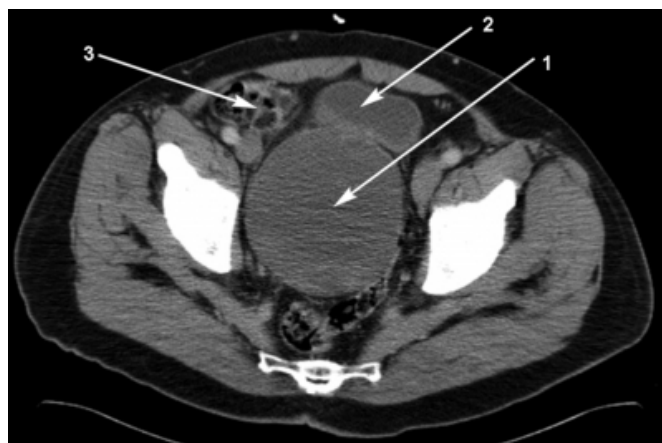
Bladder outflow obstruction in males usually results from an intrinsic obstruction of the lower urinary tract, in the region of the prostatic or peno-bulbar urethra. Extrinsic compression leading to outflow obstruction can occur in women but not seen frequently in men. This case report illustrates how a pelvic mass can lead to bladder outflow obstruction by extrinsic compression.

CASE REPORT

A 62 year old man presented with moderate lower urinary tract symptoms (LUTS), a small benign feeling prostate, a PSA of 1.7 and microscopic haematuria. Uroflowmetry showed a maximum flow rate of 5.4 ml/sec for a voided volume of 305 ml and a postvoid residual of 328 cc suggestive of bladder outflow obstruction. The only abnormalities on routine blood tests were an ESR of 36 and a CRP of 75. Urine cytology and microscopy was clear. The patient was put on the waiting list for cystoscopy and an ultrasound scan was requested. At cystoscopy there was no urethral stricture seen and residual urine of 300 ml was present. The bladder neck was occlusive, displaced anteriorly and the entire right lateral wall and dome was pushed to the left by an extrinsic mass. The mass extended from the umbilicus towards the pelvis and felt cystic on bimanual examination. The ultrasound scan, revealed mild right ureterohydronephrosis and a heterogeneous mass 16x8x8 cm in size arising behind the bladder. Subsequent contrast CT scan showed a large cystic structure within the pelvis continuous with the bladder, most likely to be a large bladder diverticulum arising from the fundus (FIG I).

Figure 1

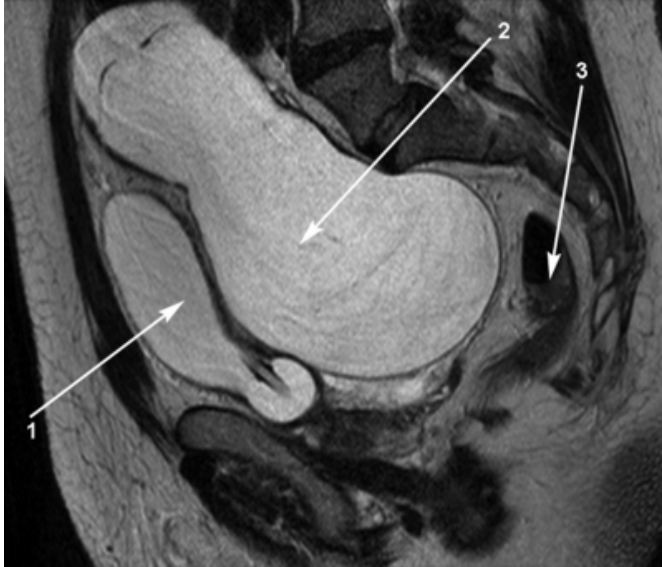Figure 1: CT scan of the pelvis with the labels 1, 2 and 3 depicting the cyst (mucocele in this case), bladder and the caecum respectively.



To assess the anatomy further, an MRI scan was organised, which showed a large fluid filled structure with rim enhancement, clearly separate from the bladder and intimately related to right distal ureter (FIG II).

Figure 2

Figure 2: MRI scan of the pelvis with gadolinium contrast, the labels 1, 2 and 3 representing the urinary bladder, the mucocele and the rectum respectively. The state of compression of the bladder neck and prostate is clearly identified.



Its superior margin appeared to be connected to the posterior aspect of the rectus sheath close to the umbilicus and a provisional diagnosis of an urachal cyst was made. At exploratory laparotomy the mass was found to be a large retroperitoneal pelvic cyst containing about 700 cc of mucinous material, with the appendix attached to its dome. This cyst was excised along with the appendix and histology revealed a neoplastic mucocele of the appendix caused by an entrapped tubulovillous adenoma. Subsequent colonoscopy showed no abnormalities. Following this procedure, the patient's voiding dysfunction almost completely disappeared and symptomatically he felt much better.

DISCUSSION

Mucocele of the appendix usually occurs because of luminal obstruction and has been found in about 0.3% of appendicectomies (2). It infrequently causes urinary tract complications, some of which have been documented like ureteric obstruction (1, 2) and renal failure (3), invasion locally into the bladder (4) by a malignant transformation of the mucocele, haematuria (5) and presentation as cystic renal

masses (6). This case highlights the fact that mucocele of the appendix can also present with bladder outflow obstruction due to displacement of the bladder neck, a symptom so far not reported. Marked improvement of lower urinary tract symptoms after removal of the mass suggests that the lower urinary obstruction was secondary to the mucocele.

Ultrasound scan of upper urinary tracts is recommended in patients with LUTS as it provides information about anatomy, residual volume, renal mass or stone (7) and more particularly in those with microscopic hematuria. In this case report the cystoscopy preceded urinary ultrasound. This was based on the poor uroflowmetry and large post void residuals, which prompted us to rule out urethral or bladder neck stricture. The MRI scan in this case provided a better anatomical relationship and in cases of bladder outflow obstruction with a pelvic mass, though a preliminary ultrasound is warranted, a pelvic MRI is a better modality and an appendicular mucocele should be kept in the list of differential diagnoses.

CORRESPONDENCE TO

M.A. Akhtar 20 Acre House Avenue, Lindley, Huddersfield. HD3 3BB m_adeel_akhtar@yahoo.com

References

1. Ibeigi P, Lombardo S, Sadeghi-Nejad H. Unusual cause of obstructive uropathy. *Int Urol Nephrol*. 2005;37(3):505-6.
2. Risher WH, Ray JE, Hicks TC. Calcified mucocele of the appendix presenting as ureteral obstruction. *J La State Med Soc*. 1991 Nov; 143(11): 29-31.
3. Parada R, Rosales A, Algaba F, Lluís F, Villavicencio H. Mucocele of the appendix: an unusual cause of obstructive kidney failure. *Br J Urol*. 1998 Sep; 82(3): 444-5.
4. Arisawa C, Takeuchi S, Wakui M. Appendiceal carcinoma invading the urinary bladder. *Int J Urol*. 2001 Apr;8(4): 196-8.
5. Oliphant UJ, Rosenthal A. Hematuria: an unusual presentation for mucocele of the appendix. Case report and review of the literature. *JSLs*. 1999 Jan-Mar; 3(1): 71-4.
6. Parsons JK, Freeswick PD, Jarrett TW. Appendiceal cystadenoma mimicking a cystic renal mass. *Urology*. 2004 May; 63(5):981-2
7. Boss HP, Knonagel H. Value of intravenous urography versus ultrasound in preoperative assessment of prostatic hyperplasia *Ultraschall Med*. 1992 Oct;13(5):228-33.

Author Information

M.A. Akhtar, MRCS

Senior House Officer, Department of Urology, Calderdale and Huddersfield NHS Trust

S. J. Basu, MS, FRCS. PhD

Specialist Registrar, Department of Urology, Calderdale and Huddersfield NHS Trust

H. D. Montgomery, FRCS

Consultant Radiologist, Department of Radiology, Calderdale and Huddersfield NHS Trust

S. Namasivayam, FRCS (Urol)

Consultant Urologist, Department of Urology, Calderdale and Huddersfield NHS Trust

K. M. Rogawski, FRCS (Urol)

Consultant Urologist, Department of Urology, Calderdale and Huddersfield NHS Trust