

Successful Treatment of Toxic Epidermal Necrolysis with Intravenous Immunoglobulin

S Ragaisiene, I Bajoriuniene, R Rimdeika, R Sakalauskas, B Sitkauskiene

Citation

S Ragaisiene, I Bajoriuniene, R Rimdeika, R Sakalauskas, B Sitkauskiene. *Successful Treatment of Toxic Epidermal Necrolysis with Intravenous Immunoglobulin*. The Internet Journal of Asthma, Allergy and Immunology. 2008 Volume 7 Number 1.

Abstract

Toxic epidermal necrolysis (TEN) is a rare but potentially fatal delayed hypersensitivity reaction to numerous medications. Anticonvulsants are one of the most common etiologic factors. The approved and controversial management strategies are still under consideration, including the administration of intravenous immunoglobulin (IVIG). We describe one patient who developed anticonvulsant-related TEN while using valproic acid and lamotrigine for epilepsy. The patient experienced systemic hypersensitivity reaction with high fever, pain in the eyes and diffuse pruritic maculopapular eruption, which became vesicular and bullous, involved oral mucosa and conjunctiva. Diagnosis of TEN was considered, and previously used drugs were discontinued. In addition to standard treatment, IVIG was administered of 0.4 g/kg (30 g) a day for a 5-day-course. The treatment led to prevention of new blister formation and improvement of skin lesions. This case-report suggests that IVIG might be beneficial in the treatment of patients with TEN.

INTRODUCTION

Toxic epidermal necrolysis (TEN) is a rare but potentially fatal reaction to numerous medications resulting in the apoptotic loss of the epidermis. It is suggested that keratinocyte apoptosis is immune-related reaction that occurs because of overexpression of TNF- α and Fas ligand (FasL) in the epidermis [1]. Anticonvulsants are reported to be a common etiologic factor; in some cases, this reaction can be triggered by latent virus reactivation [2]. Mortality rates vary 15-40% and fatal outcome usually is a consequence of infections or multi-organ failure. The accepted and controversial management strategies are still under discussion, including the administration of intravenous immunoglobulin (IVIG), which may inhibit keratinocyte apoptosis [3,4].

CASE REPORT

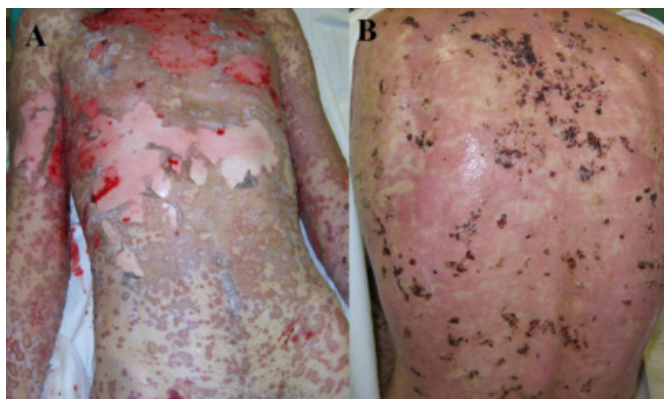
A 19-year-old man was taking valproic acid 2 g daily for the treatment of epilepsy. Because of poor symptom control, lamotrigine was added. On the 15th day of the treatment, he experienced fever and pain in the eyes and developed pruritic maculopapular eruption. The skin lesions became vesicular and bullous, involving mucosa and conjunctiva. Physical examination revealed widespread lesions with large areas of blistering and skin denudation affecting up to 80%

of the body surface area and a positive Nikolsky sign (figure 1: A). There were hemorrhage and crusted erosions on lips, gums, buccal and oral mucosa. Blood tests revealed anemia (Hb 94-100 g/l), hyperglycemia (7.6 mmol/l), hypoalbuminemia (20.9 g/l), elevated serum urea level (11.6 mmol/l) as well as elevated AST and ALT levels. Elevated hepatic enzyme levels were observed at the admission and they returned to the normal ranges at the end of the treatment - ALT from 276 U/l decreased to 38 U/l and AST from 60 U/l to 32 U/l. Serology for hepatitis A, B, C, Epstein-Barr viruses, cytomegalovirus, HSV and HIV was negative. Diagnosis of TEN was considered. According to the calculated SCORTEN (scoring system for TEN proposed by Bastuji-Garin et al.) at the admission, the predicted mortality rate was approximately 35%. When the diagnosis was established, all the previously used drugs were discontinued. The standard symptomatic management included pain control with opioid analgesics, wound management, prevention of stress ulcers, nutrition and fluid support. In addition to this treatment, 0.4 g/kg (30 g) daily dose of IVIG for a 5-day-course was started on the 3rd day after the onset of the disease. After one week, signs of the skin lesions infection and elevation of CRP level (272.0 mg/l) were observed. Some of the erosions were covered with wih purulent discharge and yellow crust. *S. aureus*, *P.*

aeruginosa, *Acinetobacter* spp and *E. faecalis* were obtained on skin lesions culture and gentamicin and imipenem intravenously were started. The patient's condition improved though tardily. The treatment led to the prevention of new blister formation and improvement of skin lesions with minimal permanent sequela. Only residual postinflammatory skin hyperpigmentation was observed, but no cutaneous scarring, nor ocular or oral complications developed (figure 1: B). Because of a low risk of cross reactivity, topiramate was administered for the continuous epilepsy treatment.

Figure 1

Figure 1: Extensive skin lesions of toxic epidermal necrolysis before the treatment (A) and on the 15th day of the treatment (B).



DISCUSSION

The reported incidence of skin reactions with lamotrigine use is approximately 10% within the first 8 weeks of the treatment [7]. The relative risk estimated (95% CI) for SJS and TEN was over 14 and 71 in patients receiving lamotrigine and phenobarbital, respectively, when the duration of the treatment was less than 8 weeks [8]. The risk of hospitalization for SJS and TEN induced by lamotrigine, carbamazepine, phenytoin and phenobarbital was calculated to be 1-10 per 10 000 new users. This ratio was significantly lower for valproic acid [9]. Tennis and colleagues reported the incidence of serious cutaneous reactions in new users of carbamazepine, phenytoin, or valproic acid. An estimated risk for such reactions was of 2.3 to 4.5 per 10,000 for phenytoin, of 1 to 4.1 per 10,000 for carbamazepine and there were no confirmed serious cutaneous reactions in patients taking valproic acid [10]. Hebert rewiev stated 5% and 10% of patients receiving hydantoin develop cutaneous reactions [11].

The anticonvulsant drug combination of valproic acid and lamotrigine is known to increase the incidence of severe immune system reactions, which are life-threatening. One of

them is toxic epidermal necrolysis. Pharmacovigilance data show that lamotrigine monotherapy may cause severe to mild mucocutaneous reactions in 0.3% to 10% of patients, respectively. However, bipolar and other mood disorders clinical trials revealed the data showing increase of the risk of serious rash with lamotrigine as adjunctive therapy up to 0.13% compared to lamotrigine monotherapy rate of 0.08% [192021]. Other factors increasing the risk of the adverse drug reactions include large initial doses of lamotrigine and rapid dose escalation within the first 8 weeks of treatment particularly in patients taking valproic acid [171821]. Pharmacokinetic features show that valproic acid may increase the half-life of lamotrigine up to 30 - 90 hours. It was suggested that the rapid culprit drug withdrawal might significantly decrease mortality rate. Unfortunately, this feature is not common for the drugs with long elimination half-life, including lamotrigine. Our reported data support such anticonvulsant-related adverse drug reactions. One of the possible triggering factors, latent virus infection, which can lead to an increase of proinflammatory cytokines, was not detected in our patient [12].

The predicted mortality rate for the patient was calculated according to the SCORTEN and it was approximately 35%. SCORTEN is an exclusive specific scoring system that is validated for the prognosis estimation of the toxic epidermal necrolysis. The certain number of independend prognostic factors indicates different range of the mortality risk. The prognostic factors for the patient were giving a score of 35.3%. It included tachycardia of 130 beats per minute, involved body surface area of greater than 10% and elevated serum urea level of 11.6 mmol/l. There were a few more scoring systems proposed in the literature, therefore they were not specific and not validated [15].

Contradictory results have been reported with skin prick tests (SPT) and patch tests for diagnosing hypersensitivity to lamotrigine. The diagnosis of TEN is usually based on clinical findings, since there are no reliable in vivo or in vitro tests. A number of false negative SPT and patch tests results may be ascribed to the specificity of the pathogenesis mechanism of this reaction. It is important to note that there is a risk of severe systemic reaction while performing these tests.

The researchers post a hypothesis of specific cytotoxic activity of T lymphocytes leading to overexpression of proinflammatory cytokines, including IL-5, CCL5 and IFN- γ [1314]. Studies showed enhanced expression of IL-6, TNF- α

and FasL with involvement of CD95 (comprising FasL and Fas receptor) and CD40/CD40L systems in TEN. The precise pathophysiologic mechanisms of this reaction to drugs remain unknown. Moreover, the cases of TEN are rare and there is limited possibility to perform prospective controlled randomized studies. Assuming all the possible management strategies for TEN, therefore there is no accepted specific treatment. Separate clinical cases report beneficial effect of IVIG on the disease progression and mortality rates. Some of the authors still have controversial opinion.

It is known that IVIG contains natural anti-Fas antibodies, which can inhibit Fas-mediated keratinocyte apoptosis in vitro that causes epidermal detachment in TEN. It thus can be regarded as a rationale to use it in humans. In addition, IVIG has powerful anti-inflammatory activity and can provide protection from possible common pathogen infections. Furthermore, IVIG has the potential to suppress proinflammatory mediators, including cytokines, chemokines and matrix metalloproteinases. The immunomodulatory effect can be obtained with a “high dose” of IVIG at 2.0 g/kg divided over 1-5 days [34]. Administration of IVIG may provide a large colloidal source of protein which has longer half-life than albumin. It is considered that colloidal intravenous supplementation is essential in the initial stages of TEN. [15] A few non-controlled clinical studies showed a benefit of IVIG in TEN, though N. Bachot conducted a prospective noncomparative study, which showed no measurable effect of IVIG therapy on mortality or progression [16]. It was a monocenter pilot trial, which included 34 patients with Stevens–Johnson syndrome and TEN. The controversial results may be due to the small number of patients, therefore researchers do not recommend administration of IVIG as a first line treatment for TEN without further studies. A prospective controlled trial then should be carried out to determine the therapeutic effect.

CONCLUSION

This case-report suggests that it might be beneficial to use IVIG in the treatment of patients with TEN. We achieved excellent outcome with IVIG added to standard symptomatic treatment.

References

1. Chave TA, Mortimer NJ, Sladden MJ, Hall AP, Hutchinson PE. Toxic epidermal necrolysis: current evidence, practical management and future directions. *Br J Dermatol* 2005;153:241-53.
2. Kano Y, Inaoka M, Shiohara T. Association between anticonvulsant hypersensitivity syndrome and human herpesvirus 6 reactivation and hypogammaglobulinemia. *Arch Dermatol* 2004;140:183-88.
3. French LE, Trent JT, Kerdel FA. Use of intravenous immunoglobulin in toxic epidermal necrolysis and Stevens–Johnson syndrome: Our current understanding. *Int immunopharmacol* 2006;6(suppl 4):543-49.
4. Campione E, Marulli GC, Carrozzo AM, Chimenti MS, Costanzo A, Bianchi L. High-dose intravenous immunoglobulin for severe drug reactions: efficacy in toxic epidermal necrolysis. *Acta Derm Venereol* 2003;83:430-32.
5. Brown KM, Silver GM, Halerz M, Walaszek P, Sandroni A, Gamelli RL. Toxic epidermal necrolysis: does immunoglobulin make a difference? *J Burn Care Rehabil* 2004;25:81-88.
6. Stella M, Cassano P, Bollero D, Clemente A, Giorio G. Toxic epidermal necrolysis treated with intravenous high-dose immunoglobulins: Our experience. *Dermatology* 2001;203:45-49.
7. Guberman AH, Besag FM, Brodie MJ, Dooley JM, Duchowny MS, Pellock JM, Richens A, Stern RS, Trevathan E. Lamotrigine-associated rash: risk/benefit considerations in adults and children. *Epilepsia* 1999;40:985-91.
8. Pichler WJ. *Drug Hypersensitivity*. Basel, Karger, 2007.
9. Mockenhaupt M, Messenheimer J, Tennis P, Schlingmann J. Risk of Stevens–Johnson syndrome and toxic epidermal necrolysis in new users of antiepileptics. *Neurology* 2005;64(7):1134-38.
10. Tennis P, Stern RS. Risk of serious cutaneous disorders after initiation of use of phenytoin, carbamazepine, or sodium valproate: a record linkage study. *Neurology* 1997;49:542-46.
11. Hebert AA, Ralston JP. Cutaneous reactions to anticonvulsant medications. *J Clin Psychiatry* 2001;62(14):22-6.
12. Aihara Y, Ito I, Aihara M, Yokota S. Two different adverse drug reactions in a pediatric patient separated by a 15-month interval: carbamazepine-induced hypersensitivity syndrome and cefaclor-induced cutaneous eruptions. *Allergologie* 2004;27:163.
13. Naisbitt DJ, Britschgi G, Wong G, Farrell J, Depta JPH, Chadwick DW, Pichler WJ, Pirmohamed M, Park BK. Hypersensitivity reactions to carbamazepine: characterization of the specificity, phenotype, and cytokine profile of drug-specific T cell clones. *Mol Pharmacol* 2003;63:732-41.
14. Naisbitt DJ, Farrell J, Wong G, Depta JP, Dodd CC, Hopkins JE, Gibney CA, Chadwick DW, Pichler WJ, Pirmohamed M, Park BK. Characterization of drug-specific T cells in lamotrigine hypersensitivity. *J Allergy Clin Immunol* 2003;111:1393-403.
15. Trent JT, Kirsner RS, Romanelli P, Kerdel FA. Analysis of intravenous immunoglobulin for the treatment of toxic epidermal necrolysis using SCORTEN. *Arch Dermatol* 2003;139:39-43.
16. Bachot N, Revuz J, Roujeau JC. Intravenous immunoglobulin treatment for Stevens–Johnson syndrome and toxic epidermal necrolysis. *Arch Dermatol* 2003;139:33-36.
17. Schlienger RG, Shapiro LE, Shear NH. Lamotrigine induced severe cutaneous adverse reactions. *Epilepsia* 1998;39(1 7):S22-S26.
18. Rzany B, Correia O, Kelly JP, Naldi L, Auquier A, Stern R. Risk of Stevens Johnson and toxic epidermal necrolysis during first weeks of antiepileptic therapy: a case control study. *Lancet* 1999;353:2190-94.
19. Mansouri P, Rabiei M, Pourpak Z, Hallaji Z. Toxic

epidermal necrolysis associated with concomitant use of lamotrigine and carbamazepine: a case report. Arch Dermatol 2005;141(6):788.
20. Data on file, GlaxoSmithKline. Information last revised

July 2008 Copyright(c) 008 First DataBank, Inc.
21. Chang CC, Shiah IS, Chang HA, Huang SY. Toxic epidermal necrolysis with combination lamotrigine and valproate in bipolar disorder. Prog Neuropsychopharmacol Biol Psychiatry 2006;30(1):147-50.

Author Information

Sandra Ragaisiene, MD

Department of Pulmonology and Immunology, Kaunas University of Medicine

Ieva Bajoriuniene, MD

Department of Pulmonology and Immunology, Kaunas University of Medicine

Rytis Rimdeika, PhD, MD

Professor, Department of Plastic and Reconstructive Surgery, Kaunas University of Medicine

Raimundas Sakalauskas, PhD, MD

Professor, Department of Pulmonology and Immunology, Kaunas University of Medicine

Brigita Sitkauskiene, MD, PhD

Associate Professor, Department of Pulmonology and Immunology, Kaunas University of Medicine