

A Comparison Of Radiant And Convective Warming In An Anesthetised Surgical Patient: A Case Report

S Walker, M Bradley, A Salmon

Citation

S Walker, M Bradley, A Salmon. *A Comparison Of Radiant And Convective Warming In An Anesthetised Surgical Patient: A Case Report*. The Internet Journal of Anesthesiology. 2002 Volume 6 Number 2.

Abstract

Surgical patients can become significantly hypothermic after induction of an anesthetic, exacerbated by the operating room environment, resulting in post operative wound infections and other morbidities. During many surgical operations treatment of intra-operative hypothermia is often confounded by lack of suitable patient surface area to warm. A new radiant warming device (SunTouch™) was compared to a common convective air warmer (BairHugger™) in two very similar operations. The radiant device was shown to reverse intra-operative hypothermia by heating only the facial area of a patient undergoing reconstructive surgery. This new radiant warmer would appear to offer anesthetists an alternative method for intra-operative warming.

INTRODUCTION

Patients undergoing surgery often become hypothermic due to redistribution hypothermia caused by anesthetic agents and exposure to cool operating room temperatures. In these patients, hypothermia is known to cause discomfort and increase the likelihood of wound infection and morbidity, and without active warming, a patient's temperature can decrease by as much as 1.5°C in the first few hours of anesthesia, when core heat loss exceeds metabolic heat production₁.

Presently, the most common mode of active warming is by forced air devices, such as the BairHugger™, Augustine Medical, USA. An alternative method of patient warming was tried in our hospital, the SunTouch™, Fisher & Paykel Healthcare, NZ. Radiant warming devices have been used before for postoperative warming₂ but have yet to be shown to be useful in the O.R. In contrast to other radiant devices this new device has a small heater, focussed output and monitors and controls skin temperature. It utilises Infrared B that slightly penetrates the skin directly heating the subcutaneous vessels, including the arteriovenous anastomoses (AVA), which are prevalent in the forehead, nose, ears, hands and feet₃. It is known that these AVA dilate to increase AV blood flow by as much as 40 times to provide thermoregulation₄ and in particular cooling of the blood by allowing large volumes of blood to pass close to the surface of the skin. As well as providing a cooling function, AVA may dilate in response to local heating₅ and

anesthesia and allow applied heat energy to be quickly and effectively transferred directly to the core.

CASE REPORT

The effectiveness of the two warming systems was retrospectively analysed following two similar operations performed on a 21-year-old female who had suffered an industrial accident resulting in multiple metacarpal and phalangeal fractures with skin loss of her right hand. Eleven days following her initial trauma, she underwent the first of two prolonged reconstructive surgeries with local muscle flap and skin graft operations with the second being two days later. The patient was generally fit and well, weighed 70kg with an ASA of I. For both operations she received a combined general anesthetic with intravenous induction (propofol on the first occasion, thiopentone on the second), non-depolarizing muscle blockade, (rocuronium on the first occasion, atracurium on the second), endotracheal intubation, and maintenance with balanced general anesthesia with isoflurane and nitrous oxide, and intravenous opioids, (both fentanyl and morphine on both occasions) and brachial plexus block.

The first operation lasted 5 hours and involved debridement of multiple lacerations and complex fixation and reconstruction of the fingers with the patient in the supine position. The patient was warmed with a full body BairHugger™ blanket. Other warming devices included an airway heat and moisture exchanger (HME) and an intravenous fluid warmer. During this procedure 3000mL of

warmed crystalloid was administered intravenously.

Body core temperature was monitored using a nasopharyngeal temperature probe (Figure 2(a)). The probe recorded continuously but only 5 data points were recorded on the anesthetic sheet, at the discretion of the attending anesthetist, not specifically for the purposes of this case report. During the first hour, the patient's core body temperature slightly decreased dropping from 36.6°C to 36.4°C, following a typical core temperature drop due to redistribution hypothermia. By t=205 minutes this had increased to 36.9°C and was maintained at this level for the remainder of the operation. Between t=105 and t=205 minutes, no temperature data were recorded.

The second operation lasted 8.5 hours, and involved repair of metacarpals using plates and soft tissue cover with a left serratus anterior muscle free flap and required the patient to be in the right lateral position. As in the first operation, the patient had an airway HME and intravenous fluid warmer, a total of 5000mL of warmed crystalloid was administered intravenously. The radiant warmer was set up as demonstrated in Figure 1, except that the patient was in the right lateral position for the first 80 minutes of the procedure. The warmer was positioned at a height of 40cm and set to control to a maximum skin temperature of 41degrees. During this time the patients' nasopharyngeal temperature dropped slightly as with the forced air warmer but remained above 36.4°C. For the next 140 minutes the radiant warmer was withdrawn to improve surgical working conditions, due to the proximity of a surgical site to the area being heated. The nasopharyngeal temperature readings fell from 36.5 to 35.5°C. The radiant heater was repositioned at t=220 and over the next 270 minutes the temperature steadily increased to 36.8°C. A greater number of temperature recordings were made during this operation. (Figure 2(b)).

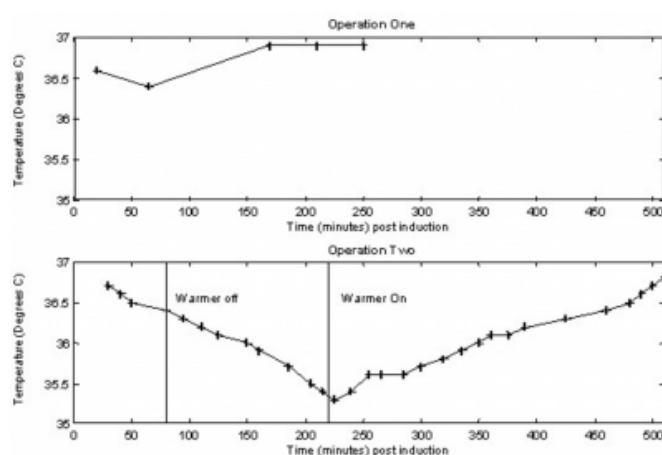
Figure 1

Figure 1. A typical setup using the radiant warmer.

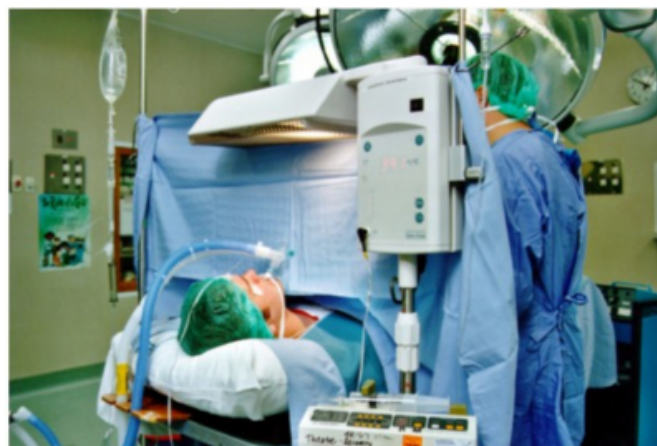

Figure 2

Figure 2. The patients core body temperature during (a) operation 1 and (b) operation 2.



DISCUSSION

The necessity for intra-operative warming devices was well demonstrated in the second procedure when the patient's core temperature dropped by 1°C during a period of 140 minutes of no external heating. The radiant warmer managed to reverse this established hypothermia, achieving the same normal core body temperature by the end of the second procedure, as did the forced air device. This might suggest that the warming power of the radiant device was at least comparable with that of the forced air system used with a full body blanket in this case, and should be investigated further.

CONFLICT OF INTEREST STATEMENT

Andrew Salmon is an employee of Fisher & Paykel Healthcare Ltd, manufacturer of the radiant warmer used in this case report.

ACKNOWLEDGEMENTS

Dr Tony Mark, consultant anesthetist in the first operation.

CORRESPONDENCE TO

Department of Anaesthesia,
Middlemore Hospital,
Private Bag 93311 Otahuhu
Auckland, New Zealand.
Ph: (649) 276 0000
Fax: (649) 270 4702

No funding was applied for. The radiant warming device was supplied by Fisher & Paykel Healthcare Ltd.

References

1. Sessler DI. Perioperative Heat. *Anesthesiology* 2000; 92: 578-596
2. Bredahl C, Lambert-Jensen P, Freundlich M. Effect of radiant heater on post operative hypothermia: comparison with a reflective blanket. *Eur J Anesthesiology* 1995; 12: 565-9
3. Bergersen T. K. A search for arteriovenous anastomoses in human skin using ultrasound Doppler. *Acta Physiol Scand.* 1993 Feb; 147(2): 195-201
4. Thoresen, M & Walloe, L: Skin blood flow in humans as a function of environmental temperature measured by ultrasound. *Acta Physiol Scand* 1980, 109: 333-341
5. Bergersen T.K., Eriksen M., Walløe L. Effect of local warming on hand and finger artery velocities. *Am J Physiol.* 1995 Aug; 269(2 Pt 2): R325-30

Author Information

Stuart Walker, FANZCA

Department of Anaesthesia, Middlemore Hospital

Martin Bradley

Clinical Trials Coordinator, Center for Clinical Research and Effective Practice, Middlemore Hospital

Andrew Salmon

Fisher & Paykel Healthcare Ltd.