

Operative Picture Of A Case Of Korner's Septum In Left Mastoid Cavity

S Vaidya

Citation

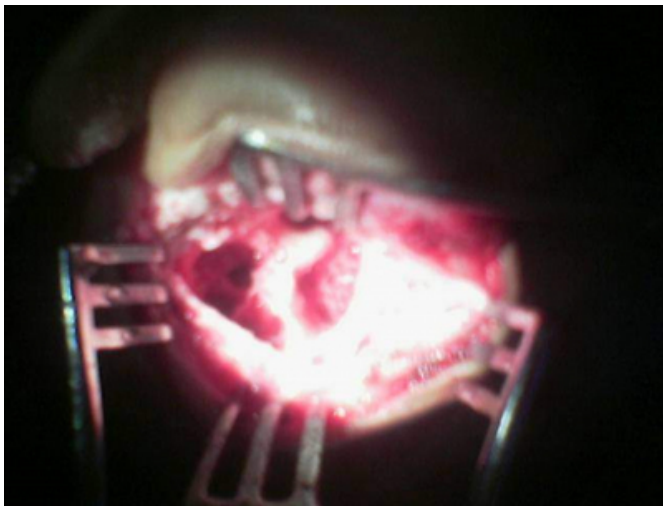
S Vaidya. *Operative Picture Of A Case Of Korner's Septum In Left Mastoid Cavity*. The Internet Journal of Otorhinolaryngology. 2006 Volume 6 Number 1.

Abstract

Figure 1

Figure 1: Operative Picture of a case of Korner 's Septum in Left Mastoid Cavity

References



Author Information

Sudhakar Vaidya, D. N. B.(ENT), D.L.O.

Associate Professor, Dept. of Otorhinolaryngology, R D Gardi Medical college & Ujjain Charitable Hospital