

Primary Tubercular Osteomyelitis Of The Sternum: Report of Two cases

S Bajracharya, G Singh, M Singh

Citation

S Bajracharya, G Singh, M Singh. *Primary Tubercular Osteomyelitis Of The Sternum: Report of Two cases*. The Internet Journal of Third World Medicine. 2006 Volume 5 Number 2.

Abstract

Tubercular involvement of the sternum, leading to osteomyelitis, is a rarely described entity even in countries where tuberculosis is endemic. Frank Presentation of this entity is even more uncommon. We describe two cases who presented with discharging sinuses with erythematous lesion over the sternum with constitutional symptoms like fever, loss of appetite and significant weight loss, but without features of pulmonary tuberculosis like cough, hemoptysis. Plain Radiographs demonstrated eroding cortex of the manubrium with lytic lesion. Tubercular etiology was suggested by presence of epithelioid granulomas and acid fast bacilli in the Ziehl-Neelsen staining of the aspirate from the lesion. Both patients responded well to antitubercular treatment.

INTRODUCTION

Tuberculosis remains a formidable challenge to health care providers in developing countries. Sternal osteomyelitis is a rarely described manifestation of tuberculosis. We report an unusual cases of sternal tubercular osteomyelitis treated with Anti tubercular regimen of 12 months duration.

CASE 1

A 35-year-old male, from Sarlahi, a Terai district of Eastern Nepal, presented with complaints of a discharging sinus with redness on the anterior chest wall, over the manubrium, noticed to be present over the last 3 months. He also had low grade fever, with evening rise, and anorexia of 3 months duration. There was no history of cough, expectoration or chest pain; and no significant family history.

On examination, he was afebrile, weighed 50 kg. A 4 X 4 cm erythematous lesion with discharging sinus was present over the distal part of the sternum and another discharging sinus just distal and right part of anterior chest wall as shown in Fig 1 (a). There was no significant lymphadenopathy. Systemic examination revealed no abnormalities.

Investigations revealed a decreased hematocrit and lymphocytosis. The ESR was elevated at 48mm/hr. Chest X-ray PA view was normal, however the lateral film revealed cortical breach and irregularity of the xiphisternum along

with a lytic lesion as shown in Fig 1 (b). Contrast enhanced computed tomography (CT) of the chest was advised, but deferred because of economic problems of patient.

Ultrasonography of the abdomen was normal. The fine needle aspiration cytology (FNAC) from the affected area revealed numerous epithelioid cell granulomas with mononuclear infiltrate and scattered giant cells. Ziehl-Neelsen staining of the aspirate was positive for acid fast bacilli. HIV serology was negative.

The patient was started on antitubercular treatment with four drugs: isoniazid, rifampicin, ethambutol and pyrazinamide. After 2 weeks of the treatment, his appetite improved with decrease in discharge. After 1 months of treatment, the erythema had subsided, and the patient had also gained weight. After 3 months of treatment, discharging sinus was healed completely. He was switched over to continuation phase with 3 drugs: isoniazid, rifampicin and pyrazinamide which were continued for another 9 months. The patient was completely cured with total 12 months of Antitubercular drugs.

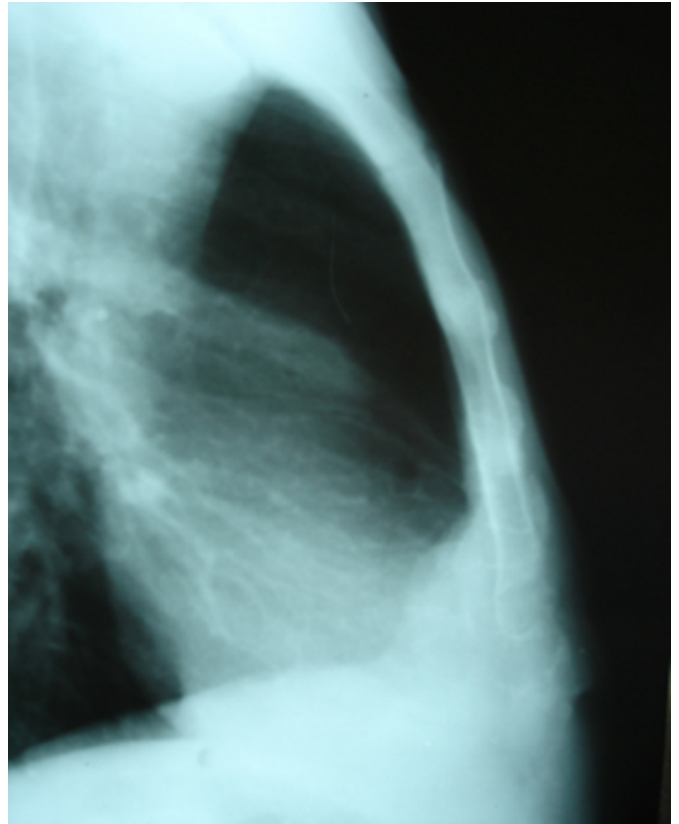
Figure 1

Figure 1a: Discharging sinuses over sternum

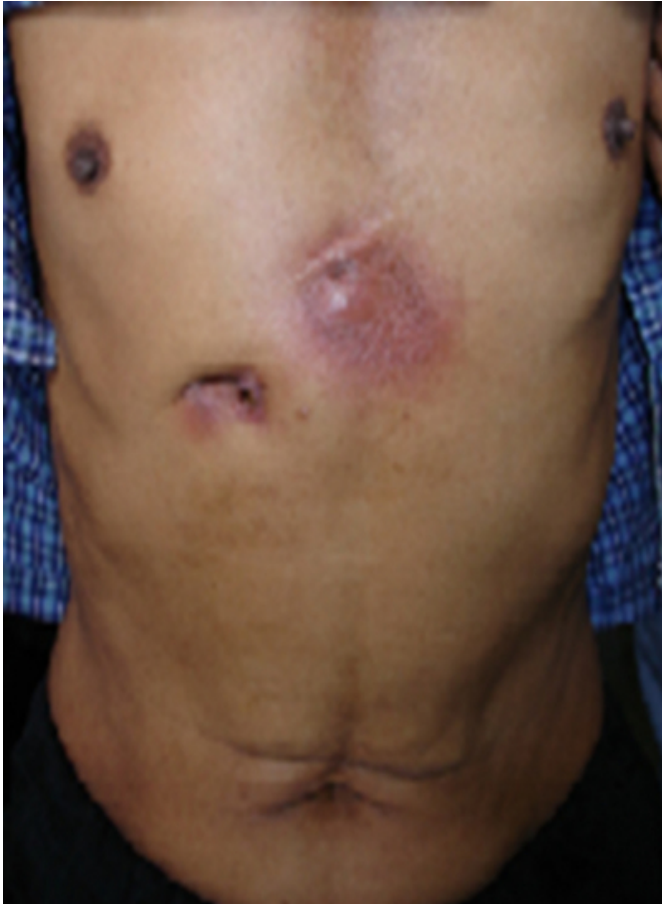

Figure 2

Figure 1b: Radiographs showing Sternal osteomyelitis with breach in cortex in distal part of body of sternum



CASE 2

A 57-year-old male, from Pachthar, a remote hilly village of Eastern Nepal presented with complaints of a discharging sinus with redness on the anterior chest wall with multiple ulcerating lesion over the manubrium for 5 and half months duration. Fig 2 (a) Constitutional symptoms like low grade fever, with evening rise, and anorexia was present for last three months. As in previous case, there was no history of cough, expectoration or chest pain; and no significant family history.

On examination, he was febrile, weighed 47 kg. A 7 X 10 cm erythematous lesion with multiple discharging sinuses and ulceration was present over the whole of the sternum extending from suprasternal notch to xiphisternum. No significant lymphadenopathy was detected. Systemic examination was within normal limit.

Investigations revealed a normal hemogram. The ESR was elevated at 60mm/hr. Chest X-ray PA view was normal, however the lateral film revealed a lytic lesion on the

proximal part of the sternum with cortical breach. Ultrasonography of the abdomen was normal. The fine needle aspiration cytology (FNAC) from the site was suggestive of tuberculosis as previous one.

Antitubercular treatment with four drugs: isoniazid, rifampicin, ethambutol and pyrazinamide was started according to body weight. After 2 months of treatment, the erthema had decreased to some extent with decreased amount in discharge. After 3 months of treatment, erythema and discharging sinus were healed completely. Continuation phase with 3 drugs: isoniazid, rifampicin and pyrazinamide were continued for another 9 months. The patient was satisfied with total 12 months of Antitubercular drugs.

Figure 3

Figure 2a: Discharging sinuses

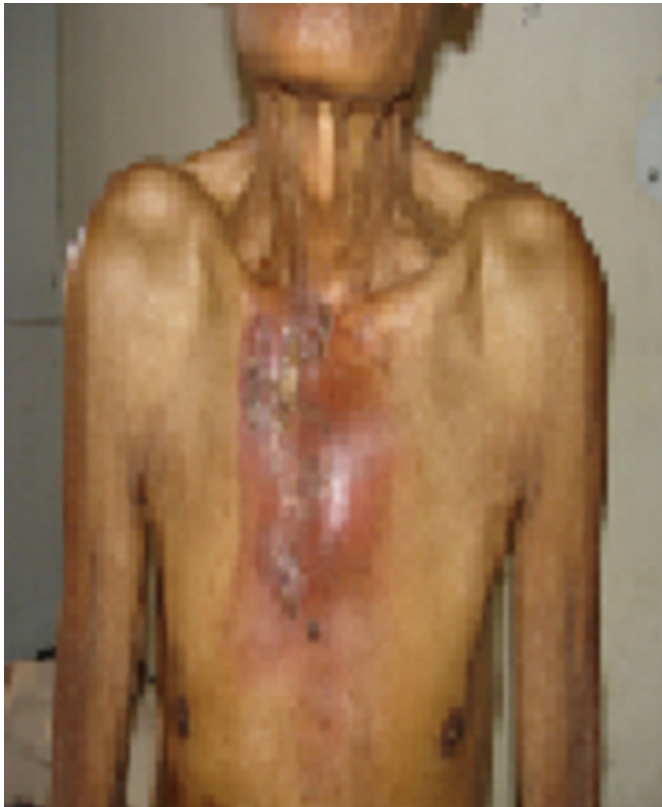
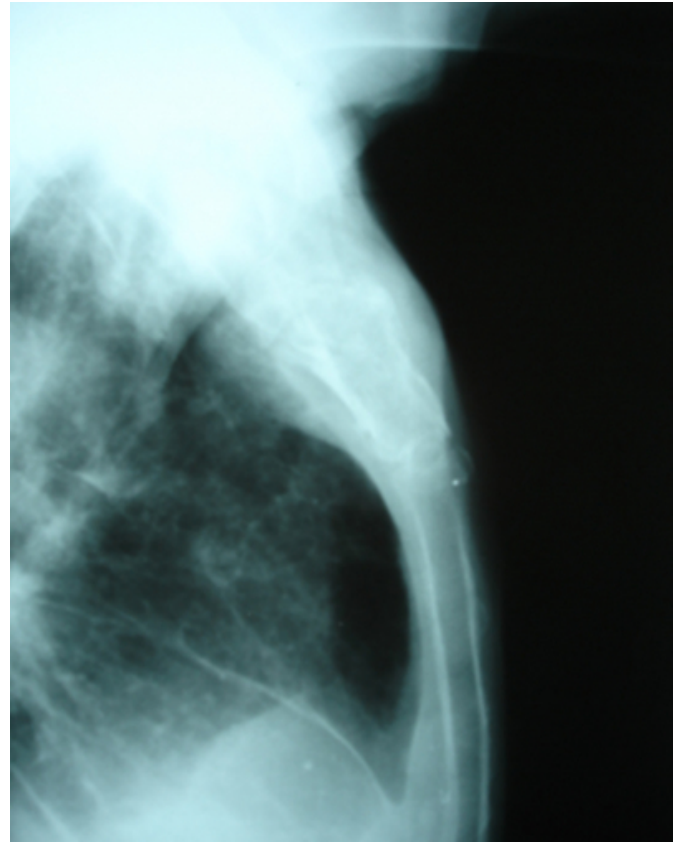
Figure 4

Figure 2b: Radiographs showing sternal. Osteomyelitis with lytic lesion over. Proximal part of the sternum



DISCUSSION

Osteomyelitis of the sternum is a very rare manifestation of tuberculosis. Around 25 cases have been reported so far, in the post antitubercular treatment era. Davies et al reported that, out of more than 4000 patients with tuberculosis, only 2 had sternal tuberculosis₁. The condition is even more uncommon in children. Out of 20 cases of sternal osteomyelitis reviewed by McLellan et al, only 2 were children₂. The earliest age at presentation has been 9 months, described in a Japanese infant₃. From India, a few cases of sternal tuberculosis have been described in adults_{4,5, 6}. Ray et al have described a case of disseminated tuberculosis in a child, in which the sternum was also involved₇.

Tubercular sternal osteomyelitis is usually caused by reactivation of latent loci formed during hematogenous or lymphatic dissemination of primary tuberculosis₈. Direct extension from contiguous mediastinal lymph nodes has also been described₉. Unlike pyogenic sternal infections characterized by more rapid and fulminant course, tubercular sternal osteomyelitis usually presents insidiously as swelling and pain over the sternum₂. Constitutional symptoms are

relatively uncommon.

Concomitant extrasternal tubercular involvement was described in 8 out of 20 cases reviewed by McLellan et al.². These included mediastinal lymph nodes (5), paraspinal abscess (2), and pulmonary involvement (1). We could not find any extrasternal source of infection in our patient.

Definitive diagnosis rests largely with the histological and microbiological examination of sternal tissue. Needle aspiration, as compared to surgical exploration, is less invasive and may represent the diagnostic procedure of first choice. However, it demonstrates positive cultures less frequently than excisional biopsy.³

CT chest, apart from the evaluation of the sternum, is also helpful in detecting any pulmonary or mediastinal involvement, which may be missed on plain Chest X-ray.^{2, 9}. Recently the role of MRI has been studied in evaluation of sternal tuberculosis. MRI is helpful in picking up bone marrow involvement and peristernal soft tissue changes.¹⁰

In addition to tuberculosis, the differential diagnosis of a chest wall discharging sinuses includes pyogenic infections, malignancy, sarcoidosis, actinomycosis, and fungal disease.⁹. FNAC or needle biopsy is useful to confirm the presence of tuberculosis or exclude other conditions.

There is no consensus on the optimal treatment of sternal tuberculosis. Although some authors suggest that medical treatment alone is effective, others believe that aggressive debridement with primary closure as an adjunct to chemotherapy is needed to prevent recurrence or the formation of a draining sinus.¹¹. Our patients responded well

to medical treatment. However, close follow up is needed in these patients to determine whether surgical treatment will ultimately be needed.

CORRESPONDENCE TO

Dr Suraj Bajracharya, MBBS, MS (Orthopaedics)
Department of Orthopaedics B P Koirala Institute of Health Sciences Dharan, Nepal E-mail: drsurajbajra@yahoo.com

References

1. Davies PDO, Humphries MJ, Byfield SP, et al. Bone and joint tuberculosis. A survey of notifications in England and Wales. *J Bone Joint Surg Br* 1984; 66: 326-330.
2. McLellan DGJ, Philips KB, Corbett CE, Bronze MS. Sternal osteomyelitis caused by *Mycobacterium tuberculosis*: case report and review of literature. *Am J Med Sci* 2000; 319: 250-254.
3. Kato Y, Horikawa Y, Nishimura Y, Shimoda H, Shigeto E, Ueda K. Sternal tuberculosis in a 9-month-old infant after BCG vaccination. *Acta Paediatr* 2000; 89: 1495-199.
4. Kataria SP, Avasthi R. Sternal tuberculosis in combination with Thalessemia. *J Assoc Physicians India* 1993; 41: 317-318.
5. Aggarwal BK, Kamath SG, Shatapathy P. Tubercular sternal osteomyelitis and mediastinitis after open heart surgery. *Indian Heart J* 1997; 49: 313-314.
6. Jhamb DK, Bhatnagar MK, Verma S, et al. Tubercular cold abscess over the manubrium sterni. *J Assoc Physicians India* 1989; 36: 292-293.
7. Ray M, Kataria S, Singhi P. Unusual presentation of disseminated tuberculosis. *Indian Pediatrics* 2002; 39: 88-91.
8. Fadiran OA, Akintan B, Oluwale SF. Tuberculous orchitis co-existing with tuberculosis of the sternum: a case report. *Cent Afr J Med* 1999; 45: 45-47.
9. Bohl JM, Janner D. *Mycobacterium tuberculosis* sternal osteomyelitis presenting as anterior chest wall mass. *Pediatr Infect Dis J* 1999; 18: 1028-1029.
10. Atasoy C, Öztekin PS, Özdemir N, Sak SD, Erden I, Akyar S. CT and MRI in tuberculous sternal osteomyelitis: a case report. *J Clinical Imaging* 2002; 26: 112-115.
11. Hsu HS, Wang LS, Wu YC, Fahn HJ, Huang MH. Management of chest wall tuberculosis. *Scand J Thorac Cardiovasc Surg* 1995; 29: 119-123.

Author Information

Suraj Bajracharya, MS (Orthopaedics)

Department of Orthopaedics, B P Koirala Institute of Health Sciences

Girish Kumar Singh, MS (Orthopaedics), DNB (PMR)

Advisor (Indian Advisory Authority) to BPKIHS, Honorary Professor, Department of Orthopaedics, B P Koirala Institute of Health Sciences

Mahipal Singh, MS (Orthopaedics)

Professor and Head, Department of Orthopaedics, B P Koirala Institute of Health Sciences