

# Posterolateral ulnar styloid process- a morphological variation

A Koka, M Sajad, K Ahmad

## Citation

A Koka, M Sajad, K Ahmad. *Posterolateral ulnar styloid process- a morphological variation*. The Internet Journal of Orthopedic Surgery. 2008 Volume 11 Number 2.

## Abstract

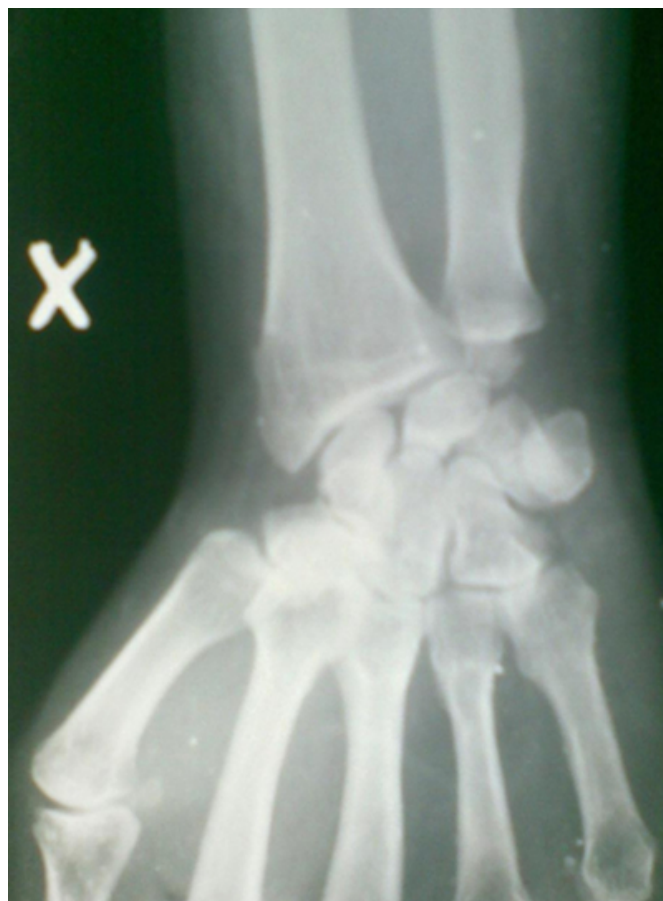Ulnar styloid process is usually present on the posteromedial aspect of the head of the ulna to the tip of which is attached the ulnar collateral ligament. Its base is the point of insertion of very important triangular fibrocartilage complex. We mention a case report in which the ulnar styloid process is present at the dorsolateral aspect of head of ulna bilaterally as a morphological variation.

## CASE HISTORY

A 42 YEARS OLD PATIENT CAME TO US WITH INJURY DUE TO FALL ON THE WRIST RIGHT SIDE. ON CLINICAL EXAMINATION HE HAD MILD TENDERNESS AT THE DORSAL ASPECT OF DISTAL RADIUS. HE HAD NO SWELLING OR DEFORMITY AT THE WRIST. ELBOW AND HAND MOVEMENTS WERE NORMAL. WRIST MOVEMENTS WERE MILDLY PAINFUL AT THE EXTREMES. RADIOGRAPHS OF THE AFFECTED WRIST (AP AND LATERAL VIEWS, FIG. 1 & 2) WERE TAKEN WHICH SHOWED NO SIGNS OF FRACTURE. BUT THE INCIDENTAL FINDING WAS A HYPERTROPHIED AND DORSOLATERALLY ATTACHED ULNAR STYLOID PROCESS. THE PATIENT HAD NO COMPLAINTS IN THE PAST HISTORY. HE USED TO CARRY OUT HIS DAILY ACTIVITIES WITHOUT ANY PROBLEMS BEFORE HE SUSTAINED TRAUMA TO HIS WRIST ONE WEEK BACK. HE HAD NO ASSOCIATED DEFORMITY ELSEWHERE. THE ELBOW JOINTS WERE NORMAL ON PALPATION AND ELBOW MOVEMENTS WERE FULL RANGE. CAREFUL EXAMINATION OF WRISTS SHOWED DECREASED ULNAR DEVIATION (BY 10-15 DEGREES) AND PRONATION (BY 10 DEGREES) ON BOTH SIDES. RADIOGRAPHS OF BOTH WRISTS WERE TAKEN ON THE SAME FILM WHICH SHOWED THE FINDING BILATERALLY (FIG 3).

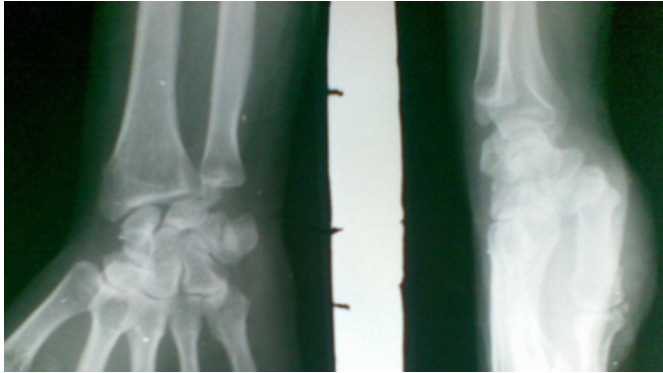
## Figure 1

Figure 1: Anteroposterior view of the wrist with laterally placed ulnar styloid



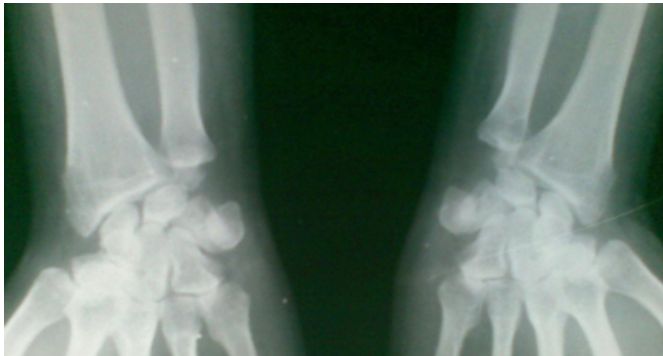
**Figure 2**

Figure 2: Anteroposterior and lateral views of the patient



**Figure 3**

Figure 3: Anteroposterior views of both wrists



The patient was managed in a wrist brace and advised analgesics.

## DISCUSSION

Normally ulnar styloid process is attached at the dorsomedial aspect of ulnar head. Morphological variations have been described by A. Biyani et.al.(400 patients). They have

described five different morphological variations, the commonest being an elongated process (102 wrists). Medially deviated (41 wrists), parrot beaked (27 wrists) and hypertrophic (16 wrists) patterns were less common. One person had bilateral unfused separate ossification centres for the ulnar styloid.

No case has been reported till date (at least in our knowledge) with the variation we have described.

The wrists with elongated ulnar styloid processes are prone to develop ulnar styloid impaction syndrome a condition in which the excessively elongated ulnar styloid process impacts the triquetrum, causing chondromalacia, synovitis and pain.

The patient in our report had no complaints in his wrists but we can predict features of ulnar styloid impaction syndrome in his wrists in the coming years, theoretically at least.

## CORRESPONDENCE TO

Abid Hussain Koka. Flat no. 10. Govt. flats Jawaharnagar Srinagar. Near SBI. Pin code 190001 Email: abidkoka@yahoo.co.in Phone no. +91-9419080662

## References

1. A.Biyani, A. Mehra and S. Bhan, Morphological variations of the ulnar styloid process, Journal of hand surgery (British and European), Vol. 15, No. 3, 352-354 (1990)
2. Hyams E, Yazaki N, Nakamura R, Nakao E, Watanabe K, Radiographic morphology of the ulnar head. Hand surg. 2004 Dec; 9(2):175-80
3. Steven M. Topper, Michael B. Wood and Leonard K. Ruby, Ulnar styloid impaction syndrome, The Journal of Hand Surgery, Vol 22, Issue 4, July 1997, pages 699-704.
4. De Smet L, Ulnar variance: facts and fiction review article. Acta Orthop Belg 1994; 60(1): 1-9.

**Author Information**

**Abid Hussain Koka, MS (Orthopaedics)**

Senior resident, Department of Orthopaedics, SKIMS Medical College

**Moulvi Sajad, MS (Orthopaedics)**

Senior Resident, Department of Orthopaedics, SKIMS Medical College

**Khurshid Ahmad, MBBS**

Junior Resident, Department of Orthopaedics, SKIMS Medical College